107 1917 2024

RHODE ISLAND MEDICAL JOURNAL

JANUARY 2024 VOLUME 107 • NUMBER 1 ISSN 2327-2228

RHODE ISLAND
MEDICAL JOURNAL

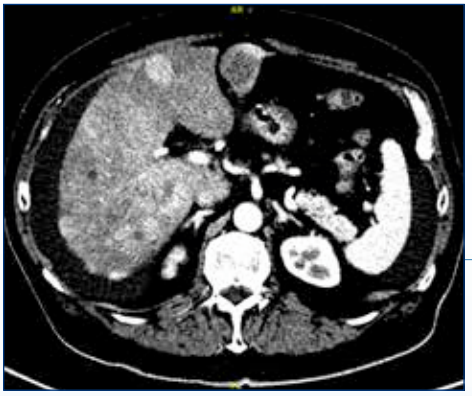

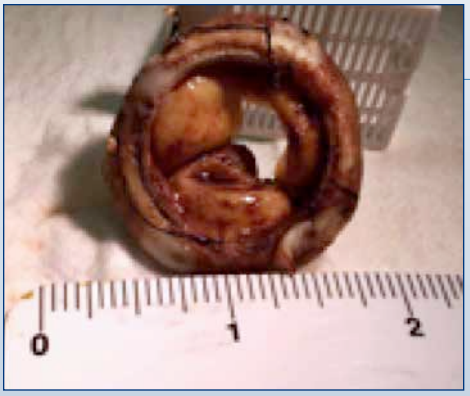

CASE REPORTS

JANUARY 2024
VOLUME 107 • NUMBER 1

RHODE ISLAND MEDICAL JOURNAL

RHODE ISLAND MEDICAL JOURNAL (USPS 464-820), a monthly publication, is owned and published by the Rhode Island Medical Society, 405 Promenade Street, Suite A, Providence RI 02908, 401-331-3207. All rights reserved. ISSN 2327-2228. Published articles represent opinions of the authors and do not necessarily reflect the official policy of the Rhode Island Medical Society, unless clearly specified. Advertisements do not imply sponsorship or endorsement by the Rhode Island Medical Society.

IMAGES IN MEDICINE

CONTRIBUTIONS

PUBLIC HEALTH

RHODE ISLAND
MEDICAL JOURNAL

J. Teck, MD D. Szkwarko, DO

A. Tyrka, MD, PhD

E. Lowenhaupt, MD

P. Vivier, MD, PhD

J. Barrett, RN, BSN

M.V. Jayaraman, MD

J. Bratberg, PharmD

Acquired von Willebrand's Syndrome in a Patient with Concomitant Chronic Lymphocytic Lymphoma and Smoldering Multiple Myeloma

NIRAV HARIBHAKTI, MD; PharmD; HYUN LEE, MD; MATTHEW QUESENBERRY, MD; JOHN REAGAN, MD

ABSTRACT

An African-American female in her sixties presented to the hospital with intermittent gum bleeding for the past two years along with severe anemia. This case details the differential and workup that lead to the diagnosis of acquired von Willebrand's syndrome (AvWS). A thorough investigation in the possible etiologies of AvWS revealed that the patient had concomitant chronic lymphocytic lymphoma (CLL) and smoldering multiple myeloma (SMM). Due to the concomitant diagnosis of CLL and SMM, there was a dilemma regarding whether CLL, SMM, or both was driving this patient's AvWS. Decision was made to treat the underlying CLL initially with rituximab and later on at recurrence with obinutuzumab/venetoclax with complete resolution of patient's bleeding and normalization of her factor VIII activity, von Willebrand factor antigen levels, and vWF:ristocetin cofactor levels. We believe this is first case in the literature of a patient with AvWS with concurrent CLL and SMM.

KEYWORDS: Acquired von Willebrand's Syndrome, chronic lymphocytic lymphoma, smoldering multiple myeloma

BACKGROUND

The case details the differential and workup that led to the diagnosis of acquired von Willebrand's syndrome (AvWS) in a patient presenting with mucocutaneous bleeding without any previous personal or family history of bleeding. Through this case, the authors have attempted to go over the etiologies of AvWS, and systematically explain how the diagnosis of chronic lymphocytic lymphoma (CLL) and smoldering multiple myeloma (SMM) were made while ruling out other differentials. Due to the concomitant diagnosis of CLL and SMM, there was a dilemma regarding whether CLL, SMM, or both was driving this patient's AvWS. In the case, the authors discuss how this dilemma was addressed, how treatment modalities were selected, and how the patient was monitored. At the end, the authors compare AvWS in this case with previously reported cases of AvWS in patients with CLL. We believe this case presents a unique diagnostic challenge and dilemma, and we have attempted to provide a step-by-step clinical reasoning to address the multiple facets of the case.

CASE PRESENTATION

An African-American female in her sixties with a past medical history of hypertension and hypothyroidism presented to the hospital with symptoms of fatigue, dyspnea on exertion, and bleeding from the gums. She reported intermittent gum bleeding for the past two years and became concerned the day prior to admission when the bleeding did not stop. She was hemodynamically stable, with an exam significant for pale conjunctiva and no lymphadenopathy or hepatosplenomegaly. Of note, the patient denied any personal or family history of bleeding, transfusion, menorrhagia, or hemarthrosis.

INVESTIGATIONS

Initial laboratory workup showed hemoglobin of 3.5g/dL, hematocrit 11.7%, MCV 90fL, WBC 15.8 x 10e9/L, platelets 326 x 10e9/L, and reticulocyte index 1.65. Iron panel was consistent with iron deficiency anemia with an iron < 10 ug/dL, iron saturation was low at a level that could not be quantified, TIBC 434 ug/dL, and ferritin 8 ng/ml. Additional lab work revealed normal PT, PTT, thrombin-time, and fibrinogen. CT face and CTA abdomen, pelvis with and without contrast were unremarkable for any bleed or acute pathology.

The presence of mucocutaneous bleeding in the setting of a normal platelet count and coagulation profile led to further workup of an acquired bleeding diathesis. This evaluation revealed factor VIII activity of 59% (reference range 50–150%), von Willebrand factor antigen 35% (reference range 50–180%), vWF:ristocetin cofactor 10% (reference range 40–180%), vWF:collagen binding 10% (reference range 50–200%), PFA-collagen/epinephrine > 232 seconds (reference range 75–195 seconds), and PFA-collagen/ADP > 300 seconds (reference range 70–120 seconds). A vWF propeptide antigen was also performed and found to be 86 IU/dL (reference range 62–183 IU/dL).

DIFFERENTIAL DIAGNOSIS

The differential for acquired bleeding disorders can be broadly divided into platelet disorders and coagulation cascade disorders.[1,2,3] Platelet disorders can be further divided into quantitative or qualitative defects. This patient's platelet levels were within normal levels making quantitative platelet disorder less likely. The normal comprehensive metabolic panel made renal and liver diseases unlikely etiologies of her presentation. At this point, platelet dysfunction and acquired coagulation cascade disorders were differential diagnoses. The normal PT/INR and PTT argued against an acquired factor deficiency. Additionally, the patient's ISTH bleeding assessment tool score of 4 made an inherited bleeding disorder less likely.

Although the patient's pro-peptide to VWF ratio was less than 3.9, it was felt that she still likely had AvWS because of her late onset mucocutaneous bleeding history and lack of family bleeding history. In order to elucidate the etiology of AvWS she underwent evaluation for hypothyroidism, lymphoproliferative disorders, myeloproliferative disorders, and structural cardiac diseases for etiologies commonly associated with AvWS.[4,5,6]

Transthoracic echocardiography was performed and was unremarkable. She had TSH of 10.2 uIU/ml with decreased total T3 62 ng/dl (80–180 ng/dl) and normal T4 1.15 ng/dL (0.8–1.8ng/dL). SPEP detected a monoclonal paraprotein in the gamma region (0.67g/dL). She was found to have normal serum kappa light chain levels, elevated lambda light chain levels, and decreased kappa/lambda ratio (0.16). Immunofixation revealed monoclonal IgG-lambda.

Flow cytometry and immunophenotypic analysis of peripheral blood and bone marrow were done. Analysis of peripheral blood showed 60% CD19+ B-lymphoid cells co-expressing CD5 and exhibiting cytoplasmic Ig kappa light chain restriction (absolute number 1.5 x 10e9/L). They were positive for CD20 (dim), CD22, CD23, CD11c, CD25, CD38, CD52, and CD79b (dim) and negative for CD10, CD103, and FMC7. Bone marrow aspirate analysis showed hypercellular bone marrow with trilineage hematopoiesis. Immunohistochemistry showed approximately 40% PAX5+, kappa+, minimally CD20+ B- lymphoid cells, approximately 10-15% CD3+, CD5+ T-cells, and approximately 15-17% CD138+ plasma cells. The plasma cell population was in a large subset lambda light chain restricted and co-expressed cyclin D1. Flow cytometry of bone marrow aspirate identified 15% lymphocytes of all bone marrow white blood cells and a large subset (77%) being cytoplasmic Ig kappa light chain restricted B-lymphoid cells co-expressing CD5 and CD19, dim CD20 positive.

Based on analysis of the peripheral blood and bone marrow, the patient was diagnosed with chronic lymphocytic lymphoma (CLL) based on International Workshop in Chronic Lymphocytic Leukemia (iwCLL) guidelines, as it was thought her B cell clonal process was driving her symptoms. Cytogenetics were significant for trisomy 12 and IgHV was unmutated. Additionally, her bone marrow contained 15–17% mostly lambda chain restricted plasma cells consistent with a diagnosis of smoldering multiple myeloma (SMM) given the absence of hypercalcemia, renal dysfunction, and bone lesions. Her severe microcytic anemia on presentation was secondary to iron deficiency.

TREATMENT

Treatment of her AvWS was two pronged to first stop the bleeding, and secondarily to treat the underlying cause. Tranexamic acid 1300mg PO three times daily sufficiently stopped bleeding. At diagnosis, however, it was unclear whether CLL, SMM, hypothyroidism or all three were driving this patient's AvWS. It was thought that the patient's hypothyroidism was less of a factor in this situation because the patient's VWF profile was more in keeping with an inherited type 2 VWD panel (much lower activity level to antigen level), which is what is often seen in lymphoproliferative disorders and multiple myeloma. AvWS with hypothyroid usually fits an inherited type 1 VWF panel profile (lower antigen to activity level). She was started on thyroid supplementation with levothyroxine, which corrected her hypothyroidism but it did not normalize her factor VIII activity (FVIII activity), von Willebrand factor antigen levels (vWF:Ag), and vWF:ristocetin cofactor (vWF:RCo) levels. Hence, it was determined that hypothyroidism may have been contributing but was not the major driver of the patient's AvWS.

The patient was initially risk stratified for both CLL and SMM based on the most recent evidence-based guidelines available at the time with the thought that an underlying reason to treat one or the other would help guide therapy.[7,8,9] Although she presented with anemia, which would have made her a high risk on both Rai and Binet staging systems for CLL,[10,11] with initial pRBC transfusion and subsequent control of gum bleeding with tranexamic acid, her hemoglobin returned to normal consistent with her anemia being secondary to iron deficiency. Given that she also had no lymphadenopathy, she was thus classified as low risk CLL. Additionally based on the Mayo Clinic SMM risk stratification she was low risk for myeloma as well.[8,9]

Left with no clear evidence for symptomatic CLL or SMM we reviewed her presenting lab values which showed a normal vWF propeptide antigen. This suggests that this patient's low vWF levels were secondary to increased clearance, which we postulated was an antibody-mediated phenomenon.[12] We therefore targeted this potential lymphoid B-cell antibody production with rituximab.

She received weekly rituximab for four weeks. FVIII activity, vWF:Ag, and vWF:RCo levels showed improvement compared to the patient's baseline at initial hospital presentation. She was then treated with rituximab maintenance

Figure 1. Factor VIII activity, Von Willebrand antigen level, and ristocetin cofactor level in response to rituximab and subsequently to obinutuzumab/venetoclax.

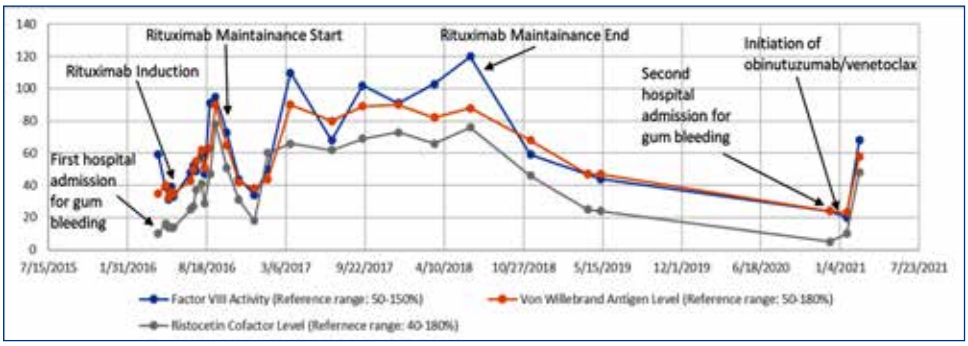

every three months for two years with normalization of her FVIII activity, vWF:Ag, and vWF:RCo levels during the maintenance (**Figure 1**). She did not report any bleeding during this time period.

OUTCOME AND FOLLOW-UP

She was subsequently lost to follow-up after discontinuation of rituximab. Almost two years after discontinuation of rituximab, the patient presented to the outpatient clinic for bleeding from the gums. Flow cytometry was performed and found consistent with prior flow cytometry results. SPEP, kappa/lambda ratio, and immunofixation continued to show stable monoclonal IgG lambda.

Considering that while being on maintenance rituximab the patient's AvWS resolved while SMM remained untreated in the background, it was determined that the recurrence of AvWS was again secondary to CLL rather than SMM. She was started on CLL-directed therapy once again with obinutuzumab and venetoclax. After starting the obinutuzumab/venetoclax regimen, the patient's levels of FVIII activity, vWF:Ag, and vWF:RCo once again returned to normal levels and her bleeding subsided.

DISCUSSION

To our knowledge, this is the first case in the literature of a patient with AvWS who was concurrently diagnosed with CLL and SMM. It highlights clinical dilemmas in elucidating the etiology of AvWS, the decision to observe or treat CLL and SMM, and which treatment modality to pursue when presented with confounding etiologies.

AvWS is not an indication for treatment based on latest guidelines by International Workshop on Chronic Lymphocytic Leukemia (iwCLL).[13] It is also not an indication for treatment based on Mayo Clinic criteria for SMM.[14] Our patient did not fulfill any criteria for "active disease" as defined by iwCLL. Additionally per Mayo 2018 risk-stratification system (also called the 20/2/20 criteria), our patient was low risk for SMM and thus observation was recommended. In situations similar to our patient's where underlying lymphoproliferative disorder is low risk, we believe an individualized approach should be pursued weighing the benefit of treating AvWS versus risk from the chemoimmunotherapy. Patients with mild occasional mucocutaneous bleeding can be managed symptomatically with desmopressin (DDAVP), vWF/FVIII concentrates, or antifibrinolytics such as aminocaproic acid or tranexamic acid. However, patients with significant bleeding or those who may require multiple surgeries/procedures in the future may benefit from treating underlying CLL, SMM, or both. Our patient had significant bleeding which resulted in profound anemia with hemoglobin of 3.5g/dL necessitating therapeutic intervention.

When presented with multiple possible etiologies for AvWS, it becomes important to decipher the underlying cause and then decide on appropriate treatment. In our case, initially it was unclear whether hypothyroidism, CLL, SMM, or a combination of the three was driving the AvWS. Considering that the patient's hypothyroidism resolved with levothyroxine without any change to her levels of FVIII activity, vWF:Ag, and vWF:RCo, it was felt that hypothyroidism was not the driving etiology of her AvWS. Although a significant number of patients diagnosed with AvWS have lymphoproliferative disorder, the exact prevalence remains unclear. Estimates range from 18–48%. Same studies have shown prevalence of MGUS in 14–23% of patients, and multiple myeloma in 2–9% of patients.[6]

We felt that the best way to determine the etiology of AvWS in our patient would be to target CLL first considering prior case reports linking CLL to AvWS. Thus far we have not come across any prior case report with association between SMM and AvWS. Alattar et al reported three cases of AvWS in patients with CLL.[15] Compared to our case, all three patients were diagnosed with CLL prior to eventual workup and identification of AvWS. Additionally compared to our patient who did not have "active disease" per iwCLL criteria, all three cases had "active disease" when treatment was initiated. The patient in case one was diagnosed with AvWS three years after development of CLL. Her AvWS symptoms were managed with aminocaproic acid mouth rinses until about two years later her CLL progressed, and she was treated with lenalidomide and rituximab. In case two, the patient with a history of severe melena secondary to duodenal bleeding was diagnosed with CLL after developing bulky lymphadenopathy. He was initially treated with a combination of rituximab, cyclophosphamide, doxorubicin, vincristine, and prednisolone. About four years later after a

second round of salvage therapy, the patient presented with GI bleed, and the workup revealed AvWS. In case three, the patient with CLL treated with fludarabine, cyclophosphamide, and rituximab was found to have prolonged bleeding after surgery and excision of his metastatic melanoma. He was ultimately diagnosed with AvWS. Khalife et al report a case of a patient who experienced multiple recurrent epistaxis about two years after the diagnosis of his CLL.[16] Patient was treated with chlorambucil and obinutuzumab with remission in both CLL and AvWS.

In a case of AvWS where multiple etiologies are present, the treatment can help elucidate the driving cause. We decided to treat our patient with rituximab to target CLL first. In this manner, if rituximab is successful in causing remission of AvWS, then the primary etiology is most likely CLL. However, if rituximab fails, it does not necessarily rule in or rule out either CLL or SMM as the underlying etiology. It may indicate that the patient needs a different set of therapeutic agents other than rituximab monotherapy to treat CLL, or the underlying etiology may be SMM. Our patient responded to rituximab with normalization of FVIII activity, vWF:Ag, and vWF:RCo levels which pointed to CLL as the driver of her AvWS with SMM as the innocent bystander. Even after her AvWS was in remission clinically and by laboratory parameters, the patient's SPEP, light chain ratio, and immunofixation continued to show stable monoclonal gammopathy. This helped establish that SMM was most likely not the underlying etiology of her AvWS. A similar case of confounding etiology was reported by Pardos-Gea et al.[17] In their case, the patient with underlying Sjorgen's syndrome and CLL was diagnosed with AvWS. The patient was first given a five-day course of IVIG to treat the autoimmune condition as the cause of the patient's AvWS. IVIG did not improve the laboratory parameters and bleeding associated with her AvWS. Next the patient's CLL was treated with rituximab and bendamustine, which led to remission of the patient's AvWS. After completion of treatment and remission of AvWS, the patient's autoantibody profile and clinical findings continued to show persistent Sjorgen's syndrome.

Two years after completing her maintenance therapy with rituximab, our patient represented with gum bleeding and relapse of her AvWS, at which point she was treated with obinutuzumab/venetoclax. Hegerova et al did report a case of a patient with AvWS secondary to CLL who underwent several rounds of chemotherapy.[18] The CLL responded to each round of chemotherapy; however, the patient's AvWS continued to be refractory to each treatment. Ultimately the patient underwent allogeneic stem cell transplant for CLL, which caused remission of her AvWS. At the time of this report, our patient was on obinutuzumab/venetoclax for six months with complete alleviation of her bleeding and normalization of FVIII activity, vWF:Ag, and vWF:RCo levels.

LEARNING POINTS

Whenever acquired von Willebrand's syndrome is suspected, it is important to investigate for any underlying myeloproliferative or lymphoproliferative disorder.

In a situation where multiple possible etiologies of AvWS are present, it may be worthwhile to direct the treatment at the most common etiology, and monitor the response rather than targeting multiple etiologies at the same time.

Patient should an integral part of the care as close follow-up is extremely important in monitoring the response to the treatment of AvWS.

References

1. Franchini M, Veneri D. Acquired coagulation inhibitor-associated bleeding disorders: An update. *Hematology*. 2005;10(6):443-449.
2. Krishnegowda M, Rajashekaraiah V. Platelet disorders: an overview. Blood Coagulation & Fibrinolysis. 2015;26(5):479-491.
3. Brennan Y, Levade M, Ward CM. Acquired platelet function disorders. *Thrombosis Research*. 2020;196:561-568.
4. Franchini M, Mannucci PM. Acquired von Willebrand syndrome: focused for hematologists. *Haematologica*. 2020;105(8):2032-2037.
5. Tiede A. Diagnosis and treatment of acquired von Willebrand syndrome. *Thromb Res*. 2012;130 Suppl 2:S2-6.
6. Federici AB, Budde U, Castaman G, Rand JH, Tiede A. Current diagnostic and therapeutic approaches to patients with acquired von Willebrand syndrome: a 2013 update. Semin Thromb Hemost. 2013;39(2):191-201.
7. Hallek M, Cheson BD, Catovsky D, et al. Guidelines for the diagnosis and treatment of chronic lymphocytic leukemia: a report from the International Workshop on Chronic Lymphocytic Leukemia updating the National Cancer Institute–Working Group 1996 guidelines. Blood. 2008;111(12):5446-5456.
8. Kyle RA, Remstein ED, Therneau TM, et al. Clinical course and prognosis of smoldering (Asymptomatic) multiple myeloma. N Engl J Med. 2007;356(25):2582-2590.
9. Dispenzieri A, Kyle RA, Katzmann JA, et al. Immunoglobulin free light chain ratio is an independent risk factor for progression of smoldering (Asymptomatic) multiple myeloma. Blood. 2008;111(2):785-789.
10. Rai KR, Sawitsky A, Cronkite EP, Chanana AD, Levy RN, Pasternack BS. Clinical staging of chronic lymphocytic leukemia. Blood. 1975;46(2):219-234.
11. Binet JL, Leporrier M, Dighiero G, et al. A clinical staging system for chronic lymphocytic leukemia: prognostic significance. Cancer. 1977;40(2):855-864.
12. Borchiellini A, Fijnvandraat K, ten Cate JW, et al. Quantitative analysis of von Willebrand factor propeptide release in vivo: effect of experimental endotoxemia and administration of 1-deamino-8-D-arginine vasopressin in humans. Blood. 1996;88(8):2951-2958.
13. Hallek M, Cheson BD, Catovsky D, et al. Iwcll guidelines for diagnosis, indications for treatment, response assessment, and supportive management of cll. Blood. 2018;131(25):2745-2760.
14. Lakshman A, Rajkumar SV, Buadi FK, et al. Risk stratification of smoldering multiple myeloma incorporating revised IMWG diagnostic criteria. Blood Cancer J. 2018;8(6):59.
15. Alattar ML, Ciccone M, Gaballa MR, et al. Bleeding diathesis associated with acquired von Willebrand Syndrome in three patients with chronic lymphocytic leukemia. Leuk Lymphoma. 2015;56(12):3452-3454.

16. Khalife R, Aw A, Duffett L, et al. To treat or not? Remission induction of acquired von willebrand syndrome secondary to chronic lymphocytic leukemia: a case report. Clin Lymphoma Myeloma Leuk. Published online January 13, 2021.
17. Pardos-Gea J, Martínez F, Abrisqueta P, Santamaría A, Bosch F. Acquired von Willebrand syndrome in a patient with small lymphocytic lymphoma and Sjögren's syndrome: which associated condition should be prioritized? Blood Coagul Fibrinolysis. 2019;30(5):239-242.
18. Hegerova L, He F, Zantek ND, Vercellotti GM, Holtan SG, Reding MT. Reversal of acquired von Willebrand syndrome with allogeneic stem cell transplant for chronic lymphocytic leukemia. Blood Cells Mol Dis. 2019;77:109-112.

Authors

Nirav Haribhakti, MD, PharmD, Division of Hematology and Oncology, Rhode Island Hospital, The Warren Alpert Medical School of Brown University, Providence, RI.

Hyun Lee, MD, Division of Hematology and Oncology, Rhode Island Hospital, The Warren Alpert Medical School of Brown University, Providence, RI.

Matthew Quesenberry, MD, Division of Hematology and Oncology, Rhode Island Hospital, The Warren Alpert Medical School of Brown University, Providence, RI.

John Reagan, MD, Division of Hematology and Oncology, Rhode Island Hospital, The Warren Alpert Medical School of Brown University, Providence, RI.

Financial Disclosures

None of the authors have any financial disclosures

Acknowledgment

None

Correspondence

Nirav Haribhakti
Rhode Island Hospital, George 312
593 Eddy Street, Providence, RI 02903
401-444-9375
Fax: 401-444-2330
nirav.haribhakti@tuhs.temple.edu

Escherichia coli Meningitis in a 72-year-old Woman

MALLIKARJUN R. KOMSANI, MD; NOUF K. ALMAGHLOUTH, MD; SWAPNA CHARLA; JENNIFER LI; MARIA D. MILENO, MD; MARGUERITE A. NEILL, MD; TAO HONG, PhD; JOHN R. LONKS, MD

ABSTRACT

Spontaneous community-acquired meningitis caused by *E. coli* is rare in the adult population. It is associated with a high risk of morbidity and mortality. We describe a case of a 72-year-old woman who presented with altered mental status and neck stiffness and was found to have *E. coli* meningitis. Urine cultures grew *E. coli*, representing a likely source. The *E. coli* strain was identified as sequence type 73 (*E. coli* ST73). Her symptoms and laboratory values improved following antibiotic initiation, and she was discharged from the hospital to a rehabilitation facility.

KEYWORDS: *E. coli* ST73, gram-negative meningitis, bacterial meningitis, urinary tract infection

INTRODUCTION

Bacterial meningitis occurs in approximately 0.9 per 100,000 individuals per year in high-income countries and is associated with a considerable risk of neurological sequelae (ranging from 9.4% to 25%) and mortality (ranging from 6% to 54%).[1-4] In adults, bacterial causes most commonly include *Streptococcus pneumoniae* and *Neisseria meningitidis*, as well as *Listeria monocytogenes* in those greater than 50 years of age.[1] Gram-negative bacillary meningitis is estimated to represent only 6.1% of bacterial meningitis cases in adults, with *Escherichia coli* specifically only occurring in 1% to 3% of cases.[5–8] We present a case of spontaneous community-acquired *E. coli* meningitis in a 72-year-old woman on chronic steroids, highlighting the importance of considering *E. coli* as a cause of meningitis.

CASE REPORT

A 72-year-old woman presented with altered mental status for one day with a five-day history of generalized weakness and a mild headache. Past medical history included nephrolithiasis (most recent ureteral stent and lithotripsy one year ago) complicated by multiple urinary tract infections, chronic kidney disease, cardiomyopathy with an ejection fraction of 28%, atrial fibrillation, anemia of chronic disease, and gout treated with chronic steroids. She had no history of ear or sinus infection, neurosurgical intervention or epidural injections, or previous episodes of meningitis. She fell at home one week prior and was cleared from any acute injuries following medical evaluation and imaging. She denied any additional current symptoms, including no photophobia, dysuria, urinary frequency, fevers, or chills.

Vital signs revealed a blood pressure of 128/71 mmHg, heart rate of 59 beats/min, and temperature of 36.7°C. On physical examination, she was confused with a Glasgow Coma Scale (GCS) score of 14 (eyes 4, verbal 4, motor 6). She had neck rigidity with a positive Brudzinski's sign but no focal motor or sensory deficits. The remainder of the physical examination was normal.

Complete blood count and comprehensive metabolic panel were notable for a white blood cell (WBC) count of 11.7×10^9/L with an absolute neutrophil count of 11.2×10^9/L, hemoglobin of 8.3 g/dL, and creatinine of 1.4 mg/dL (baseline 1.1–1.3 mg/dL). Two sets of blood cultures were obtained. Urinalysis demonstrated 64 WBC/hpf, 3+ leukocyte esterase, and negative nitrates. Computed tomography (CT) of the brain did not show evidence of any acute intracranial abnormalities. Following imaging, the patient underwent lumbar puncture, revealing clear cerebrospinal fluid (CSF) with 180 nucleated cells/ccm, 94% polymorphonuclear neutrophils, protein level of 97 mg/dL (normal 15–60 mg/dL), and glucose of 30 mg/dL (normal 50–80 mg/dL). Gram stain of CSF fluid showed many polymorphonuclear leukocytes, and organisms were seen. CT abdomen and pelvis was obtained, showing a likely left renal subcapsular hematoma and nonobstructing bilateral nephrolithiasis. There was no evidence of deep infection or abscess.

Empiric intravenous acyclovir (550 mg q8h), ceftriaxone (2g q12h), and ampicillin (2g q6h) were started less than two hours after the lumbar puncture was performed. She was admitted to the hospital.

Over the next several days, she remained hemodynamically stable with no fevers and with improvement in her neck symptoms. CSF culture grew *E. coli* susceptible to ceftriaxone (and ampicillin, cefepime, gentamicin, meropenem). Acyclovir was discontinued on day two of her hospitalization. Her WBC normalized. Urine culture grew >100,000 CFU/mL *E. coli* and >100,000 CFU/mL *Klebsiella pneumoniae*, both susceptible to ceftriaxone. Blood cultures obtained prior to antibiotics showed no growth. Ceftriaxone was continued and ampicillin was discontinued. Magnetic

resonance imaging (MRI) of the brain and cervical spine did not show any intracranial or spinal abscess. She continued to recover without any complications and was discharged to a short-term rehabilitation facility on day six of her hospitalization. She was continued on IV ceftriaxone for a total of 21 days.

Whole genome sequencing was performed in-house using Illumina iSeq platform. Resistance genes and point mutations associated with drug resistance in *E. coli* were detected using ResFinder, while virulence genes and *E. coli* serotypes were detected using VirulenceFinder and SerotypeFinder respectively. The *E. coli* was identified as sequence type (ST) 73, serotype O2 H1. No antibiotic-resistant gene and/or mutation was detected. Multiple virulence genes were detected: Surface attachment (papA_F43, papA F9, papC, iha, yeh A,B,C, D), iron acquisition (*iucC*, *iutA*, *fyuA*, *ireA*, *iroN*, *sitA*, *irp2*), serum resistance (*iss*, *traT*), Uropathogenic specific protein (usp), toxin (astA, senB, cnf1, hlyA), microcin (mchB, mchC, mchF), and ion resistance (terC).

DISCUSSION

Pathogens causing bacterial meningitis in adults include *Streptococcus pneumoniae* (72% of all cases) and *Neisseria meningitidis* (11% of all cases) and in those greater than 50 years of age, *Listeria monocytogenes*.[2] There is usually little to no reference to other pathogens.[1] Although *E. coli* is a common cause of neonatal meningitis, it rarely causes meningitis in adults.[2,9] Among 667 cases of meningitis in Rhode Island between 1976 to 1985, only 10 cases (1.5%) were of community onset meningitis due to coliform bacteria in adults.[10] Several more recent cohort studies in Europe of community-acquired bacterial meningitis found only 1% to 3% were caused by *E. coli*.[5–8] Risk factors for community-acquired *E. coli* meningitis include chronic alcoholism, liver disease, diabetes mellitus, immunocompromise, immunosuppressive drugs, and cancer.[8,9] *E. coli* meningitis can occur following penetration of the blood-brain barrier secondary to head and spinal trauma, CSF leak, and neurosurgical intervention and associated complications, including ventriculoperitoneal shunts and gastrointestinal perforation.[11,12] We present a rare case of an older patient with chronic steroid use who developed spontaneous community-acquired *E. coli* meningitis secondary to a UTI with *E. coli*.

The classic triad suggestive of meningitis includes fever, neck stiffness, and an altered mental status.[2,13] This triad occurs only in 41% of patients with acute bacterial meningitis (fever in 74%, neck stiffness in 74%, and altered mental status in 71%), though occurs more frequently in patients over 60 years of age.[14] By comparison, the classic meningitis triad is reported in only 25% of patients with *E. coli* meningitis with a low incidence (41%) of fever at presentation.[8] Consistent with prior literature, our patient presented with altered mental status and neck stiffness, but she did not have a fever at presentation and she did not develop a fever at any point during her admission. This low incidence of fever in *E. coli* meningitis may be a reflection of the patient cohort at higher risk of developing *E. coli* meningitis, including older patients and those on immunosuppression,[8] such as our patient. Overall, our case again highlights that reliance on the meningitis triad could lead to a missed or delayed meningitis diagnosis, especially with *E. coli* as the causative organism.

Gram-negative bacillary meningitis occurs more frequently as a complication from bacteremia in the setting of a distant infection, with one study reporting a distant source of infection in 77.5% with gram-negative bacillary meningitis compared to only 34.6% in other causes of meningitis.[15] For *E. coli* meningitis, urinary tract infection has been identified as the most common portal of entry, occurring in 24-48%.[8,9,16] Additional sources may include pneumonia, septic arthritis, ear infection, primary bacteremia, and peritonitis.[8,9,16] *E. coli* bacteremia is quite common in these patients with positive blood cultures identified in 76–79%. Interestingly, our patient had a distant source of infection (i.e., UTI) but no evidence of bacteremia. Several cases of *E. coli* meningitis with a urinary source have been described, but blood cultures are either positive or not enough information is given to determine the presence or absence of bacteremia.[8,16–18] Our whole genome sequencing of the *E. coli* identified it as *E. coli* ST73, the predominant invasive strain reported to cause urinary tract infections and bacteremia.[19,20] *E. coli ST73* carries a significant amount of virulence genes and it is an exclusive human pathogen.[20] In a recent genomic study, *E. coli* ST73 was also reported to cause community-acquired meningitis in adults.[21] Unlike pediatric *E. coli* meningitis, there is no predominant *E. coli* strain to cause adult meningitis. *E. coli* meningitis portends a high risk of morbidity, including neurologic complications (52–53%), ICU admission (47%), and organ failure (45%), as well as a high risk of mortality (36–48%).[8,9,16] Death from *E. coli* meningitis may be related to the virulence of the strains.[16]

Empiric treatment of bacterial meningitis should be promptly initiated when meningitis is suspected. For patients older than 50 years of age, empiric antibiotics include ceftriaxone plus ampicillin (plus Vancomycin where prevalence of cephalosporin-resistant pneumococcus is greater than 1%).[2,19] Ceftriaxone is used for the empiric treatment of bacterial meningitis when a gram stain of the CSF does not show any bacteria, because it crosses the blood-brain barrier and has activity against penicillin-resistant *Streptococcus pneumoniae* as well as *Neisseria meningitidis*. It is also the most commonly used antibiotic for *E. coli* meningitis in the literature[9,20] and is expected to be active against most strains of *E. coli* in areas of low prevalence extended spectrum beta-lactamase (ESBL) or carbapenemase producing (CPO) *E. coli*.[8] Antimicrobial susceptibility testing showed that our patient's *E. coli* was susceptible to ceftriaxone.

In conclusion, spontaneous community-acquired *E. coli* meningitis is a rare entity in adults. Fortunately, ceftriaxone, an antibiotic used for the empiric treatment of bacterial meningitis when no organisms are seen on CSF gram stain, is active against most isolates of *E. coli*. As highlighted in this case, patients may not present with the classic meningitis triad and frequently have a distant source of infection, such as a urinary tract infection. *E. coli* meningitis in adults portends a high risk of morbidity and mortality.

References

1. Hasbun R. Update and advances in community acquired bacterial meningitis. *Curr Opin Infect Dis*. 2019;32(3):233-238. doi:10.1097/QCO.0000000000000543
2. Hasbun R. Progress and Challenges in Bacterial Meningitis: A Review. *JAMA*. 2022;328(21):2147-2154. doi:10.1001/jama.2022.20521
3. van de Beek D, Brouwer MC, Koedel U, Wall EC. Community-acquired bacterial meningitis. *Lancet*. 2021;398(10306):1171-1183. doi:10.1016/S0140-6736(21)00883-7
4. GBD 2016 Causes of Death Collaborators. Global, regional, and national age-sex specific mortality for 264 causes of death, 1980-2016: a systematic analysis for the Global Burden of Disease Study 2016. *Lancet*. 2017;390(10100):1151-1210. doi:10.1016/S0140-6736(17)32152-9
5. Domingo P, Pomar V, de Benito N, Coll P. The spectrum of acute bacterial meningitis in elderly patients. *BMC Infect Dis*. 2013;13:108. doi:10.1186/1471-2334-13-108
6. Bichon A, Aubry C, Dubourg G, et al. Escherichia coli spontaneous community-acquired meningitis in adults: A case report and literature review. *Int J Infect Dis*. 2018;67:70-74. doi:10.1016/j.ijid.2017.12.003
7. Aronson SM, DeBuono BA, Buechner JS. Acute bacterial meningitis in Rhode Island: a survey of the years 1976 to 1985. *R I Med J (1976)*. 1991;74(1):33-36.
8. Cabellos C, Verdaguer R, Olmo M, et al. Community-acquired bacterial meningitis in elderly patients: experience over 30 years. *Medicine (Baltimore)*. 2009;88(2):115-119. doi:10.1097/MD.0b013e31819d50ef
9. Dzupova O, Rozsypal H, Prochazka B, Benes J. Acute bacterial meningitis in adults: predictors of outcome. *Scand J Infect Dis*. 2009;41(5):348-354. doi:10.1080/00365540902849391
10. Bodilsen J, Brouwer MC, Kjærgaard N, et al. Community-acquired meningitis in adults caused by Escherichia coli in Denmark and The Netherlands. *J Infect*. 2018;77(1):25-29. doi:10.1016/j.jinf.2018.05.009
11. Durand ML, Calderwood SB, Weber DJ, et al. Acute Bacterial Meningitis in Adults – A Review of 493 Episodes. *New England Journal of Medicine*. 1993;328(1):21-28. doi:10.1056/NEJM199301073280104
12. Bijlsma MW, Brouwer MC, Kasanmoentalib ES, et al. Community-acquired bacterial meningitis in adults in the Netherlands, 2006-14: a prospective cohort study. *Lancet Infect Dis*. 2016;16(3):339-347. doi:10.1016/S1473-3099(15)00430-2
13. Pomar V, Benito N, López-Contreras J, Coll P, Gurguí M, Domingo P. Spontaneous gram-negative bacillary meningitis in adult patients: characteristics and outcome. *BMC Infect Dis*. 2013;13:451. doi:10.1186/1471-2334-13-451
14. Moussiegt A, Birgy A, Cointe A, Duval X, Bidet P, Bonacorsi S. Escherichia coli community-acquired meningitis in adults: a case series of 29 patients in France. *Clin Microbiol Infect*. 2022;28(9):1304-1305. doi:10.1016/j.cmi.2022.04.020
15. Gilmore RL, Lebow R, Berk SL. Spontaneous Escherichia coli K1 meningitis in an adult. *South Med J*. 1983;76(9):1202-1203. doi:10.1097/00007611-198309000-00044
16. Ishida K, Noborio M, Nakamura M, Ieki Y, Sogabe T, Sadamitsu D. Spontaneous Escherichia coli bacterial meningitis mimicking heatstroke in an adult. *Clin Case Rep*. 2016;4(4):323-326. doi:10.1002/ccr3.509
17. Tunkel AR, Hartman BJ, Kaplan SL, et al. Practice guidelines for the management of bacterial meningitis. *Clin Infect Dis*. 2004;39(9):1267-1284. doi:10.1086/425368
18. Bouadma L, Schortgen F, Thomas R, et al. Adults with spontaneous aerobic Gram-negative bacillary meningitis admitted to the intensive care unit. *Clin Microbiol Infect*. 2006;12(3):287-290. doi:10.1111/j.1469-0691.2005.01346.x
19. Riley LW. Pandemic lineages of extraintestinal pathogenic Escherichia coli. Clin Microbiol Infect. 2014 May; 20(5):380–90. [PubMed: 24766445]
20. de Souza da-Silva AP, de Sousa VS, Martins N, da Silva Dias RC, Bonelli RR, Riley LW, Moreira BM. Escherichia coli sequence type 73 as a cause of community acquired urinary tract infection in men and women in Rio de Janeiro, Brazil. Diagn Microbiol Infect Dis. 2017 May;88(1):69-74. doi: 10.1016/j.diagmicrobio.2017.01.024. Epub 2017 Feb 7. PMID: 28214224; PMCID: PMC5392417.
21. Moussiegt A, Birgy A, Cointe A, Duval X, Bidet P, Bonacorsi S. Escherichia coli community-acquired meningitis in adults: a case series of 29 patients in France. Clin Microbiol Infect. 2022 Sep;28(9):1304-1305. doi: 10.1016/j.cmi.2022.04.020. Epub 2022 May 12. PMID: 35568305.

Authors

Mallikarjun R. Komsani, MD, The Miriam Hospital, Division of Infectious Diseases, Providence, Rhode Island.

Nouf K. Almaghlouth, MD, The Miriam Hospital, Division of Infectious Diseases, Warren Alpert Medical School of Brown University, Providence, Rhode Island.

Swapna Charla, Microbiology Laboratory, Department of Pathology, Lifespan, Providence, Rhode Island.

Jennifer Li, Clinical Informatics, Department of Pathology, Lifespan, Providence, Rhode Island.

Maria D. Mileno, MD, The Miriam Hospital, Division of Infectious Diseases, Warren Alpert Medical School of Brown University, Providence, Rhode Island.

Marguerite A. Neill, MD, The Miriam Hospital, Division of Infectious Diseases, Warren Alpert Medical School of Brown University, Providence, Rhode Island.

Tao Hong, PhD, Warren Alpert Medical School of Brown University, Providence, Rhode Island; Microbiology Laboratory, Department of Pathology, Lifespan.

John R. Lonks, MD, The Miriam Hospital, Division of Infectious Diseases, Warren Alpert Medical School of Brown University, Providence, Rhode Island.

Disclosures

No potential conflict of interest was reported by the authors.

Correspondence

John R. Lonks, MD
Division of Infectious Diseases
The Miriam Hospital
164 Summit Ave, Providence, RI, 02906
401-793-4620
Fax 401-793-4534
jlonks@lifespan.org

A Diagnostic Dilemma: Metastatic Neuroendocrine Tumor Mimicking Hepatocellular Carcinoma

FRANKLIN IHEANACHO, BA; KUNTAL BHOWMICK, MD; AKINDELE OLAGUNJU, MD; WEIBIAO CAO, MD; ALICE CHU, MD; KATHRYN DeCARLI, MD

ABSTRACT

Carcinoid syndrome arises from neuroendocrine tumors, characterized by the presence of neurosecretory granules. The diagnosis of carcinoid syndrome involves biochemical testing and various imaging techniques. We report the case of a 62-year-old man with Parkinson's Disease who was found to have new-onset cirrhosis and multiple hepatic lesions with necrosis on CT imaging. These findings were concerning for metastatic malignancy of unknown primary origin. Subsequent MRI characterization of the liver lesions indicated hepatocellular carcinoma as the most likely diagnosis. However, a transthoracic echocardiogram, performed for anasarca and dyspnea on exertion, revealed a thickened tricuspid leaflet, highly suspicious for carcinoid valvulitis. A biopsy of one of the hepatic lesions was consistent with neuroendocrine tumor, confirming the diagnosis of carcinoid syndrome. This case highlights the limitations of diagnostic imaging approaches in distinguishing hepatocellular carcinoma from neuroendocrine tumors.

KEYWORDS: neuroendocrine tumor, hepatocellular carcinoma, carcinoid syndrome, carcinoid valvulitis

BACKGROUND

Neuroendocrine tumors (NETs) are malignancies originating from the neuroendocrine system and are characterized by the presence of neurosecretory granules.[1] These tumors typically arise from the gastrointestinal tract, pancreas, or lungs and are classified by their grade of differentiation and malignancy.[2] Well-differentiated NETs exhibit low proliferation, while poorly differentiated ones have high proliferation rates.[3] The liver serves as the most common site for NET metastases and can mimic hepatocellular carcinoma (HCC) on presentation.[4]

CASE REPORT

A 62-year-old man with a history of Parkinson's disease, autism and schizophrenia was admitted to the hospital due to new findings on a CT scan that was ordered by his primary care provider [**Figure 1**]. The patient presented to his primary care physician with complaints of poor appetite and an unintentional 40-pound weight loss over the course of one year. He reported four months of exertional dyspnea, fatigue, generalized abdominal discomfort, intermittent diarrhea, nausea, and vomiting. The patient did not drink alcohol, and his colonoscopy two years prior was remarkable for a single tubular adenoma that was removed. Family history revealed siblings with rectal, breast, and prostate cancer.

Figure 1. Initial CT from outside facility, liver window demonstrating numerous hepatic lesions with stigmata of necrosis.

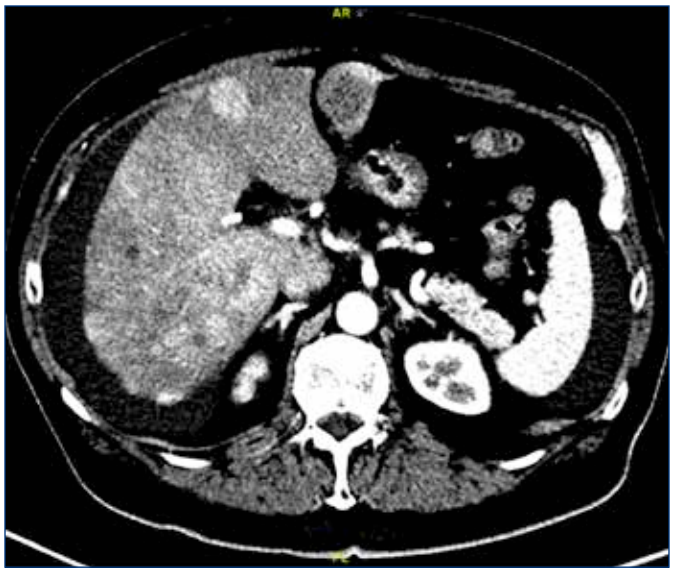

His initial physical exam noted significant pitting edema tracking from his lower extremities and up to his lower abdomen. His labs on admission were notable for acute kidney injury (AKI). His tumor markers, infectious disease laboratory results and antitrypsin levels are noted in **Table 1**. The CT scan of chest, abdomen, and pelvis demonstrated bilateral pulmonary nodules, obstructing right hydroureteronephrosis, cirrhosis, and numerous hepatic lesions with stigmata of necrosis.

The patient was started on diuretics for ascites and peripheral edema. A diagnostic and therapeutic paracentesis yielded 1.3 L of ascitic fluid with a serum ascites albumin gradient (SAAG) consistent with portal hypertension. His AKI worsened with his trial of diuresis.

A transthoracic echocardiogram (TTE) was performed and revealed severe tricuspid, mitral, and pulmonic insufficiency

Table 1. Inpatient Liver function test, cancer workup, and ascites workup values. (Abnormal values are bolded.)

AST (10–42 IU/L)	40	**117**	**508**
ALT (6–45 IU/L)	25	**16**	**60**
Alkaline Phosphatase (34–104 IU/L)	**154**	**111**	**107**
Total Protein (6–8 G/L)	7.3	**5.8**	**5.6**
Albumin (3.5–5 G/dL)	4.1	**3.4**	**3.4**
Total bilirubin (0.2–1.3 Mg/dL)	2.1	2.2	3.4
Direct bilirubin (0–0.3 Mg/dL)	0.8	—	—
Alpha 1 antitrypsin antinuelcar antibody (90–200 MG/DL)	233		
Alpha fetoprotein (AFP) (0.0–10 ng/mL)	3.6	—	—
Carbohydrate antigen 19–9 (CA 19–9) (0.0–35.0 U/ML)	4.5	—	—
Beta human chorionic gonadotropin (0.0–5.0 MIU/ML)	< 2.0	—	—
Lactate dehydrogenase (10 –200 IU/L)	172	—	—
Serum ascites albumin gradient (SAAG) (g/dL)	1.8	—	—

Table 2. Abbreviated basic metabolic panel and brain natriuretic peptide (Abnormal values are bolded.)

Labs (Reference Range)	Inital values	Day 8 values	Day 9 values
Sodium (135–145 mEQ/L)	**133**	**134**	135
BUN (6–24 Mg/dL)	**31**	**58**	**70**
Serum Creatinine (0.64–1.27 Mg/dL)	**1.85**	**3.07**	**3.78**
Brain natriuretic peptide (BNP)	820	—	—

as well as thickened tricuspid leaflets [**Figure 2**]. This was highly suspicious for carcinoid valvulitis. The patient's metastatic lesions were evaluated with further imaging. An MRI of the abdomen demonstrated washout consistent with hepatocellular carcinoma (HCC), as demonstrated in [**Figure 3**].

Based on the available data, the differential diagnosis included stage 4 HCC with Child Pugh Class B cirrhosis and carcinoid syndrome with resultant carcinoid valvulitis. The consulting oncology and cardiology teams recommended a liver biopsy and 24-hour urine 5-Hydroxyindoleacetic acid (5-HIAA) collection. A peripheral liver lesion was biopsied, and the urine collection was deferred due to biochemical interference from the patient's home carbidopa-levodopa.[5] On hospital day 8, the patient's laboratory values were remarkable for worsening AKI, and the patient became progressively encephalopathic and oliguric. The patient expired the following day.

The final liver biopsy report was released after the patient's death, and demonstrated, tumor cells positive for chromogranin and synaptophysin, supporting a neuroendocrine tumor diagnosis. The tumor cells were positive for CDX2, suggesting a primary gastrointestinal neoplasm. [**Figure 4**]

Figure 2. TTE valvular view demonstrating aortic regurgitation.

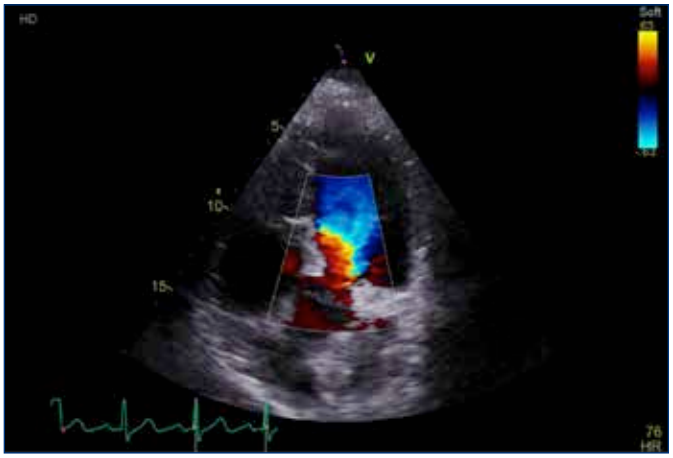

Figure 3. The image demonstrates multiple arterially enhancing lesions within the liver. The largest is a 3.8 x 4.6 cm enhancing lesion.

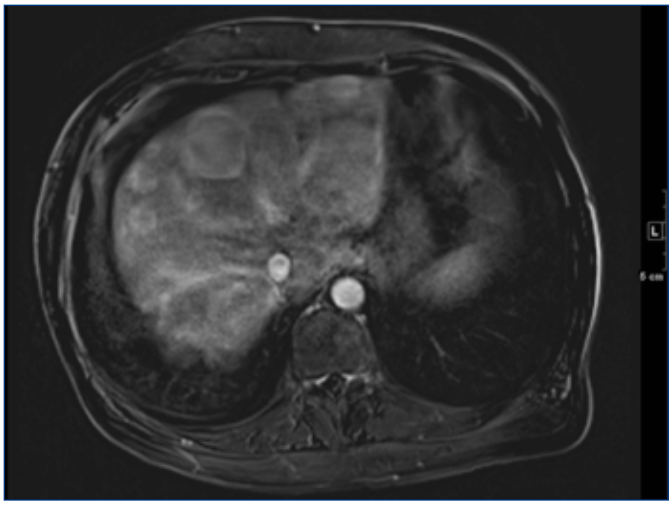

Figure 4. Histology slides of liver biopsy with CDX2 stain. Brown cells are positive for CDX2.

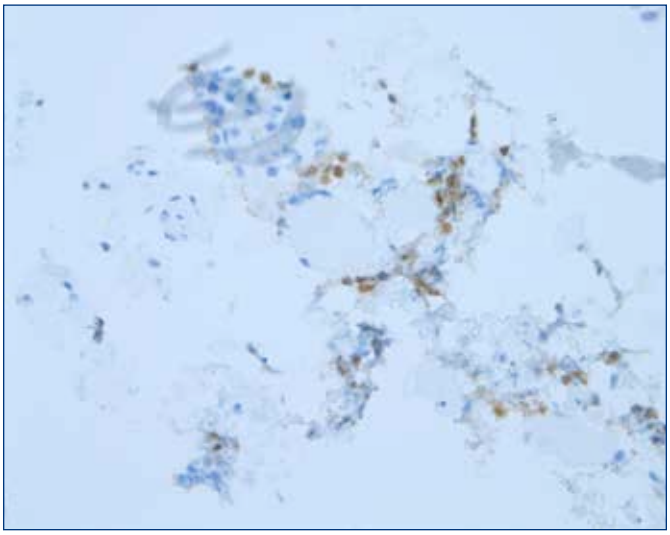

DISCUSSION/CONCLUSION

This report presents a rare case of NETs mimicking HCC. The classic presenting symptoms of HCC include right upper quadrant pain, weight loss, jaundice, and ascites.[6] The MRI findings strongly suggested a diagnosis of metastatic HCC. However, it was significant that the patient lacked the risk factors for HCC such as viral hepatitis infection, chronic alcohol consumption, and comorbidities of non-alcoholic fatty liver disease.[7] Furthermore, alpha fetoprotein was within normal limits.[8]

The characteristic TTE findings of carcinoid syndrome argued against a diagnosis of HCC. The natural history of carcinoid syndrome typically involves several years of vague abdominal pain, with characteristic systemic symptoms developing following metastasis to the liver. The classic symptoms of carcinoid syndrome subsequently develop flushing (84% of patients), diarrhea (70%), heart disease (37%), and bronchospasm (17%).[9] Carcinoid valvulitis results from the oversecretion of vasoactive amines, such as serotonin, leading to the fibrous, plaque-like deposits on the right side of the heart. Over time, the tricuspid leaflets become fixed, leading to stenosis and regurgitation.[10]

Imaging plays a central role in the diagnosis of HCC. For diagnostic testing, multiphasic, contrast-enhanced, multidetector row CT or MRI is recommended. Arterial enhancement is required for hepatic lesions to be considered suspicious for HCC, and washout on portal or delayed phases are additional features of HCC. Washout refers to hypodense or hypointense appearance of lesions compared to liver parenchyma. According to the American Association for the Study of Liver Diseases (AASLD) guidelines, a single modality CT or MRI is sufficient when hallmark features are present in nodules >1 cm.[11] Based on these guidelines, radiologists might favor a diagnosis of HCC. However, metastatic hepatic NETs have similar imaging findings. The unique imaging feature that helps differentiate metastatic hepatic NETs is Gallium-68 DOTATATE uptake on nuclear imaging, which takes advantage of somatostatin receptors in NETs.[12] Some studies have documented somatostatin receptors in more than one-third of HCCs, and a case report has noted HCC mimicking NETs on Gallium-68 DOTATATE imaging.[13] This highlights the need for specific imaging biomarkers that employ tumor biology to aid in the differentiation of NET from HCC. A radiotracer currently under investigation using this approach is [68Ga] Ga-NOTA-MAL-Cys39-exendin-4. This tracer involves labeling the peptide Exendin-4 with Gallium-68. Exendin-4 acts as an agonist for the Glucagon-like peptide-1 receptor (GLP-1R), which is expressed in insulinomas, a common type of functional pancreatic NET. [68Ga] Ga-NOTA-MAL-Cys39-exendin-4 demonstrates high accuracy in localizing insulinomas, eliminating the need for somatostatin receptor binding, which is typically absent in insulinomas.[14]

References

1. Vinik AI, Chaya C. Clinical Presentation and Diagnosis of Neuroendocrine Tumors. *Hematol Oncol Clin North Am*. 2016;30(1):21-48.
2. Ramage JK, Davies AHG, Ardill J, et al. Guidelines for the management of gastroenteropancreatic neuroendocrine (including carcinoid) tumours. *Gut*. 2005;54 Suppl 4(Suppl 4):iv1-iv16.
3. Nagtegaal ID, Odze RD, Klimstra D, et al. The 2019 WHO classification of tumours of the digestive system. *Histopathology*. 2020;76(2):182-188.
4. Jin M, Zhao X, Yearsley M, Frankel WL. Liver metastases of neuroendocrine tumors rarely show overlapping immunoprofile with hepatocellular carcinomas. Endocrine Pathology, 2016;27(3), 253–258. https://doi.org/10.1007/s12022-016-9442-7
5. Ewang-Emukowhate M, Nair D, Caplin M. The role of 5-hydroxyindoleacetic acid in neuroendocrine tumors: the journey so far. International Journal of Endocrine Oncology. 2019;6(2):IJE17.
6. Sun VCY, Sarna L. Symptom management in hepatocellular carcinoma. Clin J Oncol Nurs. 2008;12(5):759-766.
7. Janevska D, Chaloska-Ivanova V, Janevski V. Hepatocellular Carcinoma: Risk Factors, Diagnosis and Treatment. Open Access Maced J Med Sci. 2015;3(4):732-736.8.
8. Tsukuma H, Hiyama T, Tanaka S, et al. Risk factors for hepatocellular carcinoma among patients with chronic liver disease. N Engl J Med. 1993;328(25):1797-1801.
9. Vinik A, Hughes MS, Feliberti E, et al. Carcinoid Tumors. MDText.com, Inc.; 2018.
10. 1Miyasaka R, Mehta A, Pettersson GB, Desai MY. Carcinoid Tricuspid Valve Disease. Circulation: Cardiovascular Imaging, 2019;12(12), e009555. https://doi.org/10.1161/CIRCIMAGING.119.009555
11. Bota S, Piscaglia F, Marinelli S, Pecorelli A, Terzi E, Bolondi L. Comparison of international guidelines for noninvasive diagnosis of hepatocellular carcinoma. Liver Cancer. 2012;1(3-4):190-200.
12. Houat A de P, von Atzingen AC, Velloni FG, de Oliveira RAS, Torres UDS, D'Ippolito G. Hepatic neuroendocrine neoplasm: imaging patterns. Radiol Bras. 2020;53(3):195-200.
13. Ulaner GA, Bodei L. Hepatocellular Carcinoma Mimicking Neuroendocrine Tumor Metastasis on 68Ga-DOTATATE PET/CT. Clin Nucl Med. 2019;44(4):330-331
14. Fortunati E, Argalia G, Zanoni L, Fanti S, Ambrosini V. New PET Radiotracers for the Imaging of Neuroendocrine Neoplasms. Current Treatment Options in Oncology, 2022;23(5), 703–720. https://doi.org/10.1007/s11864-022-00967-z

Authors

Franklin Iheanacho, BA, Warren Alpert Medical School of Brown University

Kuntal Bhowmick, MD, Warren Alpert Medical School of Brown University, Department of Internal Medicine

Akindele Olagunju, MD, Warren Alpert Medical School of Brown University, Department of Diagnostic Radiology

Weibiao Cao, MD, Warren Alpert Medical School of Brown University, Department of Pathology and Laboratory Medicine

Alice Chu, MD, Warren Alpert Medical School of Brown University

Kathryn DeCarli, MD, Warren Alpert Medical School of Brown University, Department of Internal Medicine, Division of Hematology/Oncology

Disclosures

IRB approval: Not applicable

Conflict of Interest: The authors declare no conflicts of interest.

Financial disclosures: The authors declare no financial disclosures

Correspondence

Franklin Iheanacho

222 Richmond St, Providence, RI 02903

Franklin_Iheanacho@Brown.edu

Extensive Bilateral Cervicofacial Lymphadenitis Caused by Atypical Mycobacterium

SARAH NUSS, BS; NEEL VISHWANATH, BS; ANTHONY HAYWARD, MD, PhD; JAN C. GROBLEWSKI, MD

ABSTRACT

Non-tuberculous mycobacterial (NTM) lymphadenitis typically presents as a unilateral, non-tender, slowly enlarging cervical, submandibular, or pre-auricular lymph node in children. Disseminated NTM infection is most often seen in immunocompromised children. Here, we present an unusual case of extensive bilateral cervical and retropharyngeal lymphadenitis caused by Mycobacterium Avium Complex (MAC) in an ostensibly immunocompetent pediatric patient.

KEYWORDS: Disseminated mycobacterium; lymphadenitis; non-tuberculous mycobacterium; pediatric; Castleman disease

INTRODUCTION

Non-tuberculous mycobacterial (NTM) lymphadenitis is a significant cause of cervicofacial lymphadenitis in immunocompetent children ages 1–5.[1] The most common pathogen for this population is Mycobacterium Avium Complex (MAC), acquired through oral mucosa from environmental sources such as contaminated water or soil.[1] Children with NTM lymphadenitis usually present with a non-tender, unilateral, slowly enlarging sub-mandibular, cervical, or pre-auricular node. Infected nodes can become necrotic, suppurate, and fistulize; the indolent presentation can delay proper diagnosis and treatment for NTM lymphadenitis.[2]

Disseminated NTM is uncommon and occurs most frequently in immunocompromised patients. Deficiencies in IL-12 and IFN-γ, which play an important role in cell-mediated immunity, have been increasingly recognized to be associated with disseminated NTM infection.[3] Isolated cases of disseminated NTM in immunocompetent hosts have been reported in the literature.[4,5] Symptomatology in these cases vary, but include spondylitis, skin and soft tissue infection, septic arthritis, and severe pulmonary infection. Such reports are primarily internationally based and involve middle-aged or elderly patients. Scant literature exists describing cases of NTM in immunocompetent children. As such, susceptibility factors for this population are largely unknown. We present an unusual case of extensive disseminated cervical lymphadenitis caused by *Mycobacterium Avium* in an immunocompetent host.

CASE REPORT

An 18-month-old male presented with bronchiolitis and a right-sided neck mass, enlarging over several weeks. Ultrasound demonstrated a four cm right post-auricular complex hypoechoic collection. Computed Tomography (CT) neck scan showed a large fluid filled mass extending from the right to left neck. Intervention was delayed due to bronchiolitis. Two weeks later the patient developed fever of 102° F and an enlarging right-sided neck mass that did not respond to amoxicillin, along with infra-auricular fullness with central fluctuance and overlying erythema and surrounding induration. He did not have night sweats, fatigue, cough, dysphagia, or limited range of motion. C-Reactive protein was 12.8 mg/L, and the Sedimentation Rate was 95 mm/hr.

He was admitted for intravenous ampicillin-sulbactam 200mg/kg/day and interventional radiology guided needle

Figure 1. [**A**] Patient's new left-sided neck mass, and [**B**] right-sided neck mass with fistula.

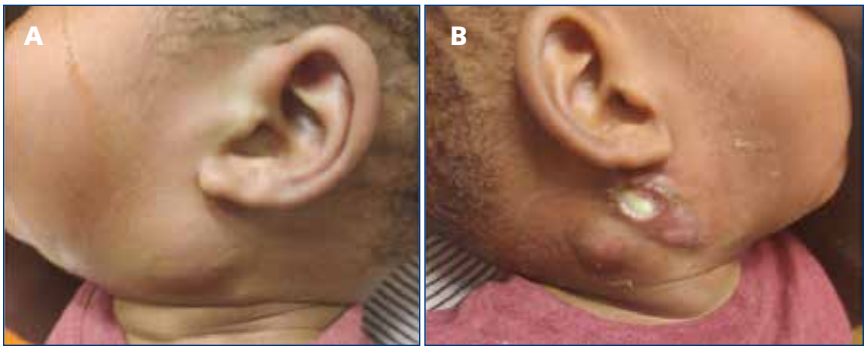

Figure 2. Patient's right-sided neck mass with fistula

drainage. Gram stain of aspirated fluid was negative. A Purified Protein Derivative (PPD) test was positive, and cultures were positive for Mycobacterium Avium Complex (MAC). Shortly after discharge, the patient again developed bronchiolitis, was briefly admitted, and was started on azithromycin 10mg/kg and rifampin 10mg/kg.

Three weeks later, the patient's right-sided neck mass fistulized, and he developed a new left sided neck mass (**Figures 1,2**). Routine immune function tests (IL-12, IL-23, or interferon production. IgM, IgA, and IgG levels and T-cell counts) were normal but an Invitae primary immunodeficiency panel identified a nucleotide-binding oligomerization domain-containing protein 2 (NOD2) variant (c.2104C>T (p.Arg702Trp), that is associated with Crohn's disease. Antibodies to IFN gamma were negative.

He was started on azithromycin, rifampin, and ethambutol. The patient underwent transoral needle aspiration of retropharyngeal fluid collection and selective left-sided neck dissection for debulking. The left-sided neck mass was removed successfully, and the patient was discharged the following day. Surgical pathology was notable for possible Castleman disease.

The patient returned for a right selective neck dissection after six weeks of antibiotics. Multiple inflamed lymph nodes in level IIA, IIB, III, and V were excised. A skin fistula was excised by right superficial parotidectomy, with closure by cervicofacial advancement flap. Antibiotics were discontinued after seven months. There were no complications and the patient recovered well through nine months of follow-up.

DISCUSSION

We describe an unusual case of a disseminated *M. avium* infection in an immunocompetent host. Definitive diagnosis of NTM is via biopsy and culture, although culture yield is only approximately 50%.[2] Acid fast stains and tuberculin skin tests may also suggest NTM. The preferred management strategy for NTM lymphadenitis is surgical excision of the affected node.[6] Other strategies include directed primary or adjuvant antimicrobial therapy, fine needle aspiration, incision and drainage, curettage, and observation; but have lower cure rates and higher recurrence rates.[6] Non-operative management of NTM lymphadenitis may be considered for patients with recurrence or high-risk surgical candidates.

Although the standard of care for NTM lymphadenitis is surgical excision, surgery was delayed due to concern that our patient was not an appropriate surgical candidate given his multiple episodes of bronchiolitis. Due to the delay, the right mass fistulized. Operative removal of the left-sided neck mass was therefore prioritized to prevent fistulization of the left side while attempting to reduce the size of the right neck mass with antibiotics prior to operation.

The patient's episodes of bronchiolitis and diffuse cervical lymphadenitis suggested an immunodeficiency. Disseminated NTM is associated with HIV positivity, or, in HIV negative adults, with anti-IFN-γ IgG autoantibodies.[7] Our patient was negative for HIV and anti-IFN-γ IgG autoantibodies, although his recurrent bronchiolitis suggested possible immunodeficiency, suggesting a possible alterative mechanism of cell-mediated immunodeficiency associated with disseminated NTM.

Gene sequencing for our patient found a heterozygous variant in NOD2, which is involved in immune recognition of mycobacterial antigens.[8] Specific polymorphisms of NOD2 are associated with impaired cytokine production and can lead to susceptibility or resistance to Mycobacterium tuberculum or Mycobacterium leprae.[8] NOD2 variants are also associated with inflammatory and granulomatous disease such as IBD and Blau syndrome.[9] Given the link between NOD2 polymorphisms and other granulomatous diseases, future studies should investigate a possible link between NOD2 polymorphism and reactive skin disease in disseminated NTM.

Surgical pathology for this patient was notable for histology features suggestive of possible Castleman disease, a lymphoproliferative disease of unknown etiology. Common pathological findings of Castleman disease include lymphoid hyperplasia, germinal center formation, capillary proliferation, and endothelial hyperplasia. While this patient had no other clinical features of Castleman's disease, there are case reports that describe Castleman's with a similar presentation to mycobacterial lymphadenitis, or possible overlap between the two conditions. TAFRO syndrome, a multicentric idiopathic form of Castleman's disease, can mimic disseminated mycobacterium.[10] Conversely, there have also been reports of mycobacterial infections mimicking Castleman histologic features, or triggering Castleman's disease.[11]

This unique patient extends our knowledge on clinical presentation of NTM in the pediatric population and highlights the need for further study on mechanisms which predispose HIV and anti-IFN-γ negative patients to disseminated infection. We specifically urge further evaluation on the growing body of literature of both NOD2 polymorphism and Castleman's disease as they pertain to mycobacterium infection.

References

1. To K, Cao R, Yegiazaryan A, Owens J, Venketaraman V. General Overview of Nontuberculous Mycobacteria Opportunistic Pathogens: Mycobacterium avium and Mycobacterium abscessus. *J Clin Med*. 2020;9(8):2541. doi:10.3390/jcm9082541
2. Zimmermann P, Tebruegge M, Curtis N, Ritz N. The management of non-tuberculous cervicofacial lymphadenitis in children: A systematic review and meta-analysis. *J Infect*. 2015;71(1):9-18. doi:10.1016/j.jinf.2015.02.010

3. Phoompoung P, Ankasekwinai N, Pithukpakorn M, et al. Factors associated with acquired Anti IFN-γ autoantibody in patients with nontuberculous mycobacterial infection. *PLoS ONE*. 2017;12(4):e0176342. doi:10.1371/journal.pone.0176342
4. Al Mamari A, Al Tamtami W, Al A'amri K, Al Lawati H, Al Kalbani S, Al Muqbali I. First report of disseminated Mycobacterium abscessus in an immunocompetent adult patient in Oman. *IJID Reg*. 2022;2:162-164. doi:10.1016/j.ijregi.2022.01.010
5. Chang HY, Tsai WC, Lee TF, Sheng WH. Mycobacterium gordonae infection in immunocompromised and immunocompetent hosts: A series of seven cases and literature review. *J Formos Med Assoc Taiwan Yi Zhi*. 2021;120(1 Pt 2):524-532. doi:10.1016/j.jfma.2020.06.029
6. Harb JL, Pascal E, Compton RA, Scott AR. What is the optimal management of pediatric nontuberculous mycobacterial cervicofacial lymphadenitis? *The Laryngoscope*. 2020;130(6):1359-1361. doi:10.1002/lary.28459
7. Henry MT, Inamdar L, O'Riordain D, Schweiger M, Watson JP. Nontuberculous mycobacteria in non-HIV patients: epidemiology, treatment and response. *Eur Respir J*. 2004;23(5):741-746. doi: 10.1183/09031936.04.00114004
8. Cubillos-Angulo JM, Fernandes CD, Araújo DN, Carmo CA, Arriaga MB, Andrade BB. The influence of single nucleotide polymorphisms of NOD2 or CD14 on the risk of Mycobacterium tuberculosis diseases: a systematic review. *Syst Rev*. 2021;10:174. doi:10.1186/s13643-021-01729-y
9. Caso F, Galozzi P, Costa L, Sfriso P, Cantarini L, Punzi L. Autoinflammatory granulomatous diseases: from Blau syndrome and early-onset sarcoidosis to NOD2-mediated disease and Crohn's disease. *RMD Open*. 2015;1(1):e000097. doi:10.1136/rmdopen-2015-000097
10. Oka K, Yamane M, Yokota Y, et al. Disseminated Mycobacterium genavense infection mimicking TAFRO syndrome. *J Infect Chemother Off J Jpn Soc Chemother*. 2020;26(10):1095-1099. doi:10.1016/j.jiac.2020.06.020
11. Anand AS, Kuriakose VG, Govindan K, Nachimuthu K, John RM, Meloot SS. Multicentric Castleman's Disease with Mycobacterium cosmeticum Infection. *Arch Surg Oncol*. 2017;03(01). doi:10.4172/2471-2671.1000120

Authors

Sarah Nuss, BS, Warren Alpert Medical School, Brown University, Providence, RI

Neel Vishwanath, BS, Warren Alpert Medical School, Brown University, Providence, RI

Anthony Hayward, MD, PhD, Warren Alpert Medical School, Brown University, Providence, RI

Jan C. Groblewski, MD, Warren Alpert Medical School, Brown University; Division of Pediatric Otolaryngology, Hasbro Children's Hospital, Providence, RI

Acknowledgments

SN, NV assisted with concept development, manuscript writing, manuscript revision. AH and JG assisted with concept development and manuscript revisions.

Financial Disclosures

None

Correspondence

Sarah Nuss
Sarah_nuss@brown.edu

An Adolescent with Undiagnosed Ulcerative Colitis Presenting with Toxic Megacolon and Cavitary Pulmonary Nodules

RAHIYA REHMAN, MD; STEPHANIE CAMHI, MD; JASON SHAPIRO, MD; SHOVA SUBEDI, MD; LINDA SHALON, MD

ABSTRACT

Toxic megacolon and pulmonary nodules are not seen frequently on diagnosis in pediatric ulcerative colitis patients. This report emphasizes the importance of carefully evaluating and managing complications in pediatric ulcerative colitis cases, especially in the presence of pulmonary nodules.

KEYWORDS: pediatrics, ulcerative colitis, inflammatory bowel disease, lung nodules

INTRODUCTION

Toxic megacolon (TM) is an infrequent complication of ulcerative colitis (UC), especially in children, with a reported incidence of only 1–2%.[1] TM is characterized by colonic dilation (≥5–6 cm), along with signs of system toxicity.TM is most often associated with infectious colitides, such as *Clostridioides difficile* (*C. difficile*) and cytomegalovirus.[1,2] It can lead to mortality if left untreated. Inflammatory bowel disease (IBD) can also lead to several extra intestinal manifestations including rare occurrence of cavitary pulmonary nodules (CPN) which can be a diagnostic dilemma due to their resemblance to other infectious conditions.[3,4] We present a unique case of a pediatric patient who initially presented with two rare complications of ulcerative colitis (UC): TM and CPN.

CASE PRESENTATION

A 12-year-old girl came to the emergency department with a four-week history of abdominal pain, poor appetite, diarrhea, and weight loss. She had an unremarkable exam except for persistent tachycardia. Labs showed microcytic anemia, leukocytosis with bandemia, elevated erythrocyte sedimentation rate, and hypoalbuminemia. Tachycardia initially responded to fluid resuscitation; however, next day she developed abdominal tenderness and bloody diarrhea. Abdominal X-ray showed dilated transverse colon. Chest X-ray revealed right-sided atelectasis vs pneumonia. Magnetic resonance enterography (MRE) showed diffuse colonic distention (~6–8 cm in diameter) with circumferential thickening and hyperenhancement of the colon without terminal ileum involvement (**Figure 1**). She received antibiotics and red blood cell transfusions. Stool infectious studies including Clostridium difficle were negative and high dose steroids were started for presumed inflammatory bowel disease (IBD). Further review of the MRE demonstrated basal lung nodules. Follow-up chest computed tomography (CT) revealed bilateral pulmonary nodules with a basilar and peripheral predominance, and cavitation (**Figure 2**) suggestive of either septic emboli or inflammatory nodules seen in IBD. Tuberculosis infection was ruled out with QuantiFERON gold testing. Her colitis was unresponsive to high-dose steroids, and therapy with anti-tumor necrosis factor (anti-TNF) agent was initiated given patient's hesitancy for any surgical intervention. However, she developed a bowel perforation resulting in subtotal colectomy and ileostomy. Distal sigmoid colon and rectum appeared healthy and were left in place at that time given unclear diagnosis while the remaining inflamed colon was removed. Histopathology was consistent with UC, further confirming diagnosis of UC. After four weeks she was discharged home with plans for future completion proctocolectomy, creation of J pouch and eventual ileostomy closure following nutritional rehabilitation in future. A repeat chest X-ray and CT scan at follow-up visit demonstrated almost complete resolution of the pulmonary nodules.

Figure 1. MRE of the abdomen showed diffuse distention of the colon along with air-fluid levels, marrow edema, circumferential wall thickening and hyperenhancement on postcontrast images.

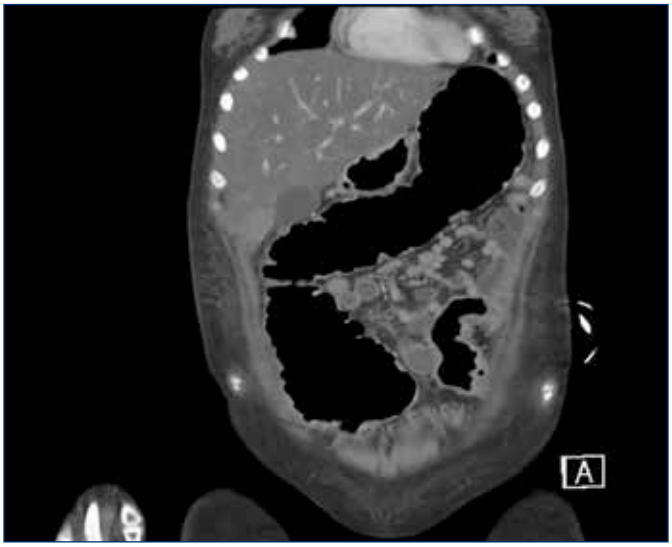

Figure 2A,2B. CT scan of chest with IV contrast showed innumerable pulmonary nodules noted throughout the lungs with a basilar and peripheral predominance along with some cavitation.

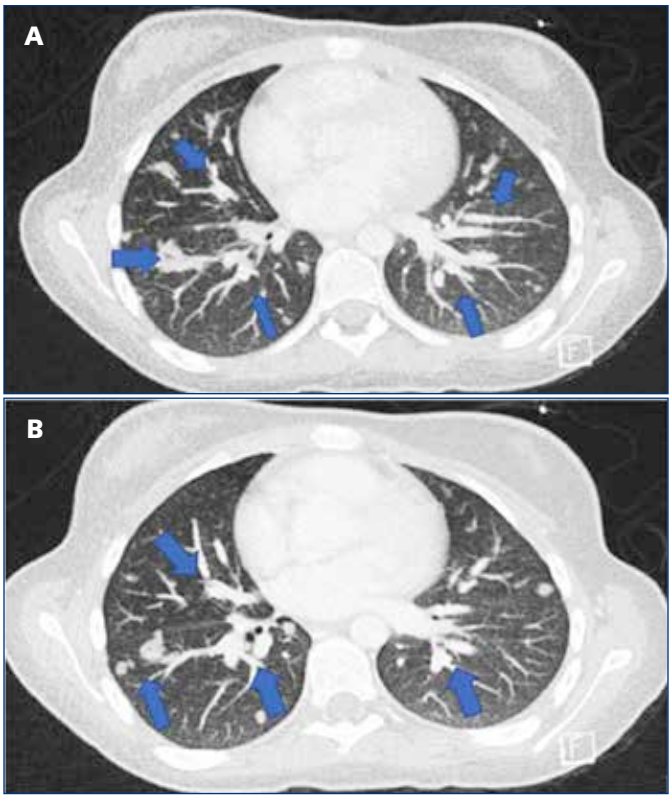

DISCUSSION

Our case highlights two rare complications of ulcerative colitis in an adolescent: acute severe ulcerative colitis presenting as toxic megacolon and pulmonary nodules. Acute severe UC is managed initially with high-dose steroids, but this decision must be carefully weighed in a patient with lung nodules of uncertain etiology. Parenchymal lung disease and lung nodules seen in UC can mimic autoimmune processes such as granulomatosis with polyangiitis, sarcoidosis and vasculitis, and are commonly confused with septic pulmonary emboli.[5,6] Both septic emboli and necrobiotic nodules may appear as cavitating lesions on imaging. Septic emboli are suggested by bilateral peripheral nodules with identifiable feeding vessels and may have accompanying lung abscesses with a predominant neutrophilic infiltrate on histopathology.[7] Inflammatory pulmonary nodules are also bilateral but have a necrotic granulomatous infiltrate on histopathology.[5,6] While septic emboli always respond to antimicrobial therapy, they usually get worse with immunosuppressive therapy. Inflammatory nodules on the other hand do not respond to antibiotics but show a favorable response to steroids and anti-TNF therapy.[6-8] Lung biopsy was not recommended in our patient given the acuity of her illness. She likely had inflammatory nodules as suggested by the lack of documented infection and near complete resolution of lung nodules on follow-up imaging after treatment of her ulcerative colitis.

To the best of our knowledge, this is the first report of a pediatric patient presenting with both TM and CPN as initial presentation of UC. This case highlights the dilemma of treating acute severe colitis in the presence of CPN.

References

1. Russell RK, Protheroe A, Roughton M, Croft NM, Murphy MS, Spray C, et al. Contemporary outcomes for ulcerative colitis inpatients admitted to pediatric hospitals in the United Kingdom. Inflamm Bowel Dis. 2013;19: 1434–1440. PMID: 23624885
2. Benchimol EI, Turner D, Mann EH, Thomas KE, Gomes T, McLernon RA, et al. Toxic megacolon in children with inflammatory bowel disease: clinical and radiographic characteristics. Am J Gastroenterol. 2008;103: 1524–1531. PMID: 18510624
3. Barfield E, Deshmukh F, Slighton E, Lentine J, Lu Y, Ma X, et al. Pulmonary Manifestations in Adolescents with Inflammatory Bowel Disease. Clin Pediatr. 2020;59: 573–579. PMID: 32146830
4. Pemmasani G, Loftus EV, Tremaine WJ. Prevalence of Pulmonary Diseases in Association with Inflammatory Bowel Disease. Dig Dis Sci. 2022. PMID: 35142913
5. Turner D, Ruemmele FM, Orlanski-Meyer E, Griffiths AM, de Carpi JM, Bronsky J, et al. Management of Paediatric Ulcerative Colitis, Part 2: Acute Severe Colitis-An Evidence-based Consensus Guideline from the European Crohn's and Colitis Organization and the European Society of Paediatric Gastroenterology, Hepatology and Nutrition. J Pediatr Gastroenterol Nutr. 2018;67: 292–310. PMID: 30044358
6. Mukherjee S, Harne P, Mirchia K, Sharma A, Manocha D. Necrobiotic Pulmonary Nodules in Ulcerative Colitis: Not Just a "Crohnic" Phenomenon. ACG Case Rep J. 2020;7: e00438. PMID: 32903944
7. Weerakkody Y, Murphy A, Lukies M, et al. Septic pulmonary emboli. Reference article, Radiopaedia.org (Accessed on 23 Jul 2023) https://doi.org/10.53347/rID-22848
8. Kellish A, Soal V, Caskey E, Hassinger G, Terrigno N. Pulmonary Necrobiotic Nodules at Time of Diagnosis in a Patient with Ulcerative Colitis. Cureus. 2020;12: e7474. PMID: 32351852

Authors

Rahiya Rehman, MD, Brown Pediatric Gastroenterology Fellow, Division of Pediatric Gastroenterology, Hepatology and Nutrition, Hasbro Children's Hospital, and Department of Pediatrics, The Warren Alpert Medical School of Brown University, Providence, RI.

Stephanie Camhi, MD, Brown Pediatric Resident, Department of Pediatrics, The Warren Alpert Medical School of Brown University, Providence, RI.

Jason Shapiro, MD, Attending Physician, Division of Pediatric Gastroenterology, Hepatology and Nutrition, Hasbro Children's Hospital, and Department of Pediatrics, The Warren Alpert Medical School of Brown University, Providence, RI.

Shova Subedi, MD, Attending Physician, Division of Pediatric Gastroenterology, Hepatology and Nutrition, Hasbro Children's Hospital, and Department of Pediatrics, The Warren Alpert Medical School of Brown University, Providence, RI.

Linda Shalon, MD, Attending Physician, Division of Pediatric Gastroenterology, Hepatology and Nutrition, Hasbro Children's Hospital, and Department of Pediatrics, The Warren Alpert Medical School of Brown University, Providence, RI.

Disclosures

There are no conflict of interest or financial disclosures to report.

Correspondence

Rahiya Rehman, MD
Division of Pediatric Gastroenterology, Hepatology and Nutrition
Hasbro Children's Hospital, 593 Eddy St, Providence RI 02903
401-444-2851
Rahiya_rehman@brown.edu

Burkholderia cepacia: A Rare Source of Endocarditis

JESSICA M. GONZALEZ, MD; GABRIEL LOWENHAAR, MD; MOTI RAMGOPAL, MD; PRASAD CHALASANI, MD

ABSTRACT

A 37-year-old male with a past medical history of previous mitral valve replacement due to bacterial endocarditis and intravenous (IV) drug use was found to have *Burkholderia cepacia* bacteremia. Transesophageal echocardiogram revealed large mitral and tricuspid valve vegetations. Medical management was initially attempted but his bacteremia persisted, and he required urgent prosthetic mitral valve replacement and native tricuspid valve replacement. Prosthetic valve endocarditis has been associated with surgery in 48.9% of patients and a mortality of 22.8%. In patients with prosthetic valve endocarditis due to *B. cepacia,* valve replacement occurred in approximately 61.5% of patients and mortality is estimated to be 33.3%. To our knowledge, this is one of only a few prosthetic valve endocarditis cases caused solely by *B. cepacia* and our case is the first to affect multiple valves including prosthetic and native valves.

KEYWORDS: *Burkholderia cepacian,* infective endocarditis, prosthetic valve endocarditis

INTRODUCTION

Infective endocarditis (IE) is an infection of the native valves, prosthetic valves, or endocardium that can cause significant morbidity and mortality in those affected. Mortality estimates are as high as 25%.[1] The incidence of IE in the United States increased from 11 per 100,000 population to 15 per100,000 population over a 10-year period (2000–2011).[2]

Most cases are caused by *Streptococci viridans*, *Staphylococcus aureus,* and enterococci.[2] Primary risk factors include structural heart disease, congenital heart defects, prosthetic heart valves, and intravenous drug use (IVDU). Clinical manifestations are variable; patients may present with fever, chills, anorexia, myalgia, night sweats, and weight loss.[3] Diagnosis of infective endocarditis is made using the Modified Duke Criteria.[3] Medical treatment options can be elucidated by susceptibility studies, while size of vegetations, valve function, and ejection fraction can help determine need for surgical intervention. For rare pathogens, it is important to review both susceptibility studies and prior literature to determine best treatment modalities.

CASE REPORT

A 37-year-old male presented to the hospital with two weeks of progressive and ongoing night sweats, chills, chest discomfort, and shortness of breath. He admitted to polysubstance intravenous drug abuse. Past medical history was relevant for Hepatitis C, hypertension, cerebrovascular accident with

Figure 1. TEE showing large vegetation in mitral valve.

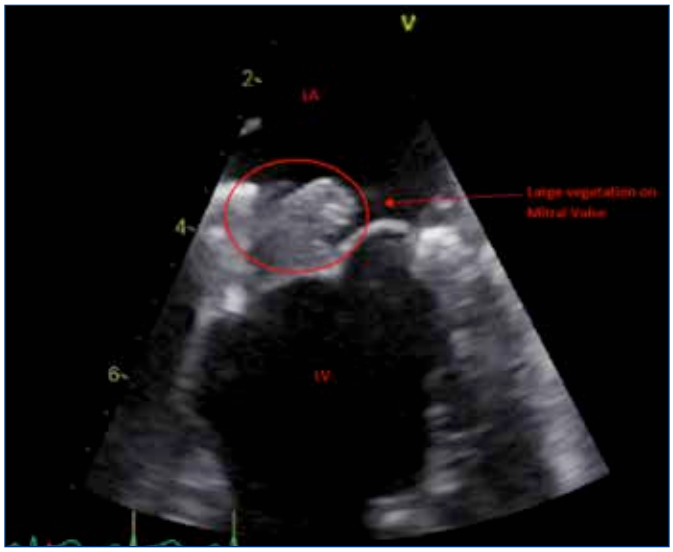

Figure 2. TEE showing large tricuspid valve vegetation.

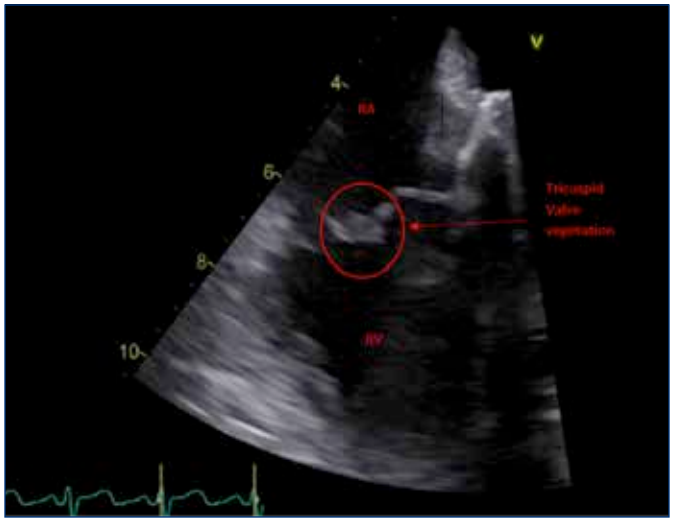

Figure 3. Gross image showing very large vegetation.

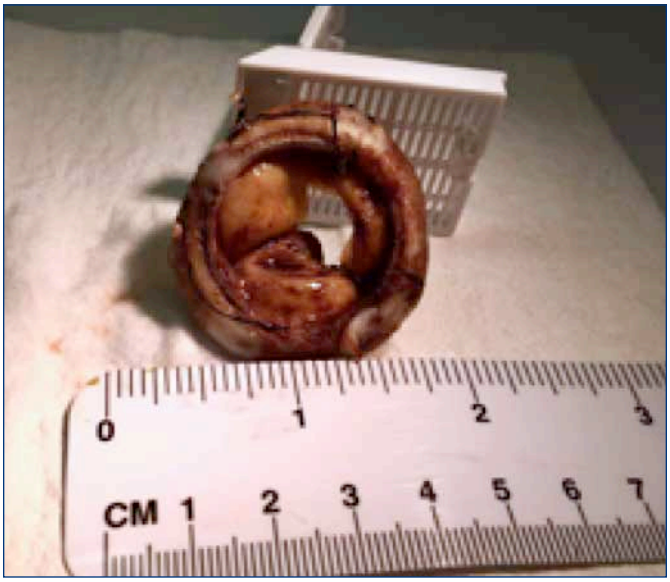

chronic, residual, left-sided deficit, and mitral valve replacement due to bacterial endocarditis with an uncomplicated hospital course in 2018.

Three years later, he developed chest discomfort and progressive shortness of breath, leading him to seek care at an outside hospital, where he received broad-spectrum antibiotic therapy. He eloped two days later from their facility, after initiating treatment there with vancomycin and piperacillin/tazobactam. Several days later, he re-presented to our hospital. He was tachycardic and afebrile on presentation. His labs revealed leukocytosis. Serial blood cultures revealed bacteremia with *Burkholderia cepacia.* Transthoracic (TTE) and transesophageal (TEE) echocardiography demonstrated a mobile mass in his prosthetic mitral and native tricuspid valves (**Figures 1,2**). Mild tricuspid and mitral insufficiency were originally noted with an ejection fraction (EF) of 50%. Ceftriaxone and doxycycline were initially given, but he was transitioned to ceftazidime, meropenem, and sulfamethoxazole-trimethoprim. The patient's bacteremia persisted despite treatment. Subsequently, he was taken to the operating room for an urgent mitral valve replacement. During the operation, it was revealed that his prosthetic mitral valve was completely destroyed with vegetations (**Figure 3**). He also needed a tricuspid valve replacement. Postoperative hospital course was uncomplicated, and the patient was discharged with outpatient follow-up.

DISCUSSION AND LITERATURE REVIEW

Our patient was found to have *Burkholderia cepacia* endocarditis in both native and prosthetic valves. This microbe is a catalase-positive, aerobic, lactose-producing, gram-negative bacillus that mostly affects immunocompromised individuals.[4] It has a predilection for cystic fibrosis (CF) and chronic granulomatous disease (CGD) patients.[4] It also affects patients with intravenous drug use (IVDU).[4] This bacterium is ubiquitous and is commonly found in water and soil; it can survive in harsh environments and can live in 10% iodine solution for greater than one year.[5]

Only 15 cases of infective endocarditis attributed to *B. cepacia* have been reported in English-language literature.[5] Prior cases describe patients with similar comorbidities of IVDU and prior history of endocarditis. These patients were mostly treated with combinations of vancomycin and cefepime, or Sulfamethoxazole-trimethoprim and meropenem. Despite medical treatment, most of these patients ultimately required valvular surgery.[4,6,7,8] Only one patient, an immunocompetent woman with no known risk factors, was found to have *B. cepacia* endocarditis. She was medically managed with ceftazidime for six weeks and then outpatient ciprofloxacin for two weeks; she continued to do well at a two-year follow-up.[9] Sulfamethoxazole-trimethoprim is the drug of choice for *B. cepacia* infection. Prior to initiation of antibiotics, cultures should be obtained; sensitivity analysis should be performed due to high resistance. Antibiotics should be continued for six weeks.[4]

We treated our patient with ceftazidime, meropenem, and sulfamethoxazole-trimethoprim. His bacteremia persisted despite optimal medical treatment. Based on American Heart Association/American College of Cardiology and the European Society of Cardiology guidelines, early surgery is considered in patients with severe valvular pathology, signs of heart failure, heart block, annular abscess, fungal or highly resistant organisms, and in recurring emboli or enlarging vegetations.[10] Our patient ultimately required both native and prosthetic valve replacements.

Few cases of prosthetic valve endocarditis (PVE) have been reported.[11] Surgery was performed in 48.9% of PVE patients (repair or replacement). An associated mortality of 22.8% has been reported for PVE.[6,9,12] Heart failure is the most common complication of PVE, with an incidence of up to 56%.[13] The most common cause of sudden death is disruption of the valve .[13] It is necessary to perform TEE on patients with suspected prosthetic valve endocarditis, as sensitivity ranges from 82% to 96% in comparison to TTE with the sensitivity of 17% to 36%.[13] TEE is the gold standard for the diagnosis of PVE.

Incorporating our case to prior literature review data on PVE caused by B *cepacia*[6] results in valve replacement rate of 61.5% and a mortality rate of 33.3%, which are higher than seen in PVE of all sources. There seems to be increased mortality and necessity for prosthetic valve replacement in IE associated with *B. cepacia.* We hypothesize that the increased morbidity and mortality associated to this organism is due to its virulence factors and immune-mediated tissue damage. This organism is known to induce virulence through exopolysaccharide production associated

with evasion of host response and lipopolysaccharides contributing to immune-mediated tissue damage.[13] There may be a similar pathogenesis contributing to increased tissue damage in patients with IE.

Further research will be required to understand the pathogenesis of this organism in IE. To our knowledge, our patient is the first to have native tricuspid valve endocarditis and prosthetic mitral valve endocarditis attributed to a single pathogen origin of *B. cepacia.*

References

1. Ambrosioni J, Hernandez-Meneses M, Téllez A, et al. The Changing Epidemiology of Infective Endocarditis in the Twenty-First Century. *Curr Infect Dis Rep*. 2017;19(5):21.
2. Pant S, Patel NJ, Deshmukh A, et al. Trends in infective endocarditis incidence, microbiology, and valve replacement in the United States from 2000 to 2011. *J Am Coll Cardiol*. 2015;65(19):2070-2076.
3. Cahill TJ, Prendergast BD. Infective endocarditis. *Lancet*. 2016;387(10021):882-893.
4. Nnaoma C, Chika-Nwosuh O, Sossou C. A Rare Culprit of Infective Endocarditis in an IV Drug User: *Burkholderia cepacia*. *Case Rep Med*. 2019;2019:6403943.
5. Luk KS, Tsang YM, Ho AY, To WK, Wong BK, Wong MM, Wong YC. Invasive Burkholderia cepacia Complex Infections among Persons Who Inject Drugs, Hong Kong, China, 2016-2019. Emerg Infect Dis. 2022 Feb;28(2):323-330. doi: 10.3201/eid2802.210945. Epub 2021 Dec 14. PMID: 34906288; PMCID: PMC8798689.
6. Dellalana LE, Byrge KC, Gandelman JS, Lines T, Aronoff DM, Person AK. A Unique Case of *Burkholderia cepacia* Prosthetic Mitral Valve Endocarditis and Literature Review. *Infect Dis Clin Pract (Baltim Md)*. 2019;27(3):123-125.
7. Sabir N, Ikram A, Gardezi A, et al. Native valve dual pathogen endocarditis caused by *Burkholderia cepacia* and *Aspergillus flavus* - a case report. *JMM Case Rep*. 2018;5(9):e005143.
8. Ki HK, Kim SH, Han SW, Cheong HS. A case of native valve endocarditis caused by Burkholderia cepacia without predisposing factors. *BMC Infect Dis*. 2011;11:114.
9. Russo M, Nardi P, Saitto G, et al. Paravalvular leak of a mechanical mitral valve prosthesis associated with *Burkholderia cepacia* subacute endocarditis: a rare case successfully treated by multidisciplinary approach. *Kardiochir Torakochirurgia Pol*. 2017;14(3):200-202.
10. Kang D. Timing of surgery in infective endocarditis *Heart*. 2015;101:1786-1791.
11. Wang A, Athan E, Pappas PA, et al. Contemporary clinical profile and outcome of prosthetic valve endocarditis. *JAMA*. 2007;297(12):1354-1361.
12. Ivanovic B, Trifunovic D, Matic S, Petrovic J, Sacic D, Tadic M. Prosthetic valve endocarditis - a trouble or a challenge? J. Cardiol. 2019;73:126–133. doi:10.1016/j.jjcc.2018.08.007
13. Zlosnik JE, Costa PS, Brant R, et al. Mucoid and nonmucoid Burkholderia cepacia complex bacteria in cystic fibrosis infections. *Am J Respir Crit Care Med*. 2011;183(1):67-72.

Authors

Jessica M. Gonzalez, MD, Brown University Department of Internal Medicine, Providence, RI

Gabriel Lowenhaar, MD, Brown University Department of Emergency Medicine, Providence, RI

Moti Ramgopal, MD, Florida State University College of Medicine, Infectious Disease, Fort Pierce, FL

Prasad Chalasani, MD, Florida State University College of Medicine Cardiology Fort Pierce, FL

Disclosures

Conflicts of interest: The authors declare that there is no conflict of interest.

Disclosures/Disclaimers: No disclosures or disclaimers

Correspondence

Jessica M. Gonzalez
jlowenhaar@gmail.com

Varicella Zoster Associated Vasculopathy and Retinitis with Natalizumab Use in Multiple Sclerosis

ERIKA L. THAYER, DO; RIZVI A. SYED, MD; GLENN A. TUNG, MD

ABSTRACT

Natalizumab (Tysabri®, NTZ) is a monoclonal autoantibody approved for treatment of relapsing-remitting multiple sclerosis. NTZ inhibits leukocyte migration across the blood-brain barrier, preventing autoreactive cells from inciting an inflammatory immune response. This immunosuppression is highly efficacious in attenuating the risk of relapse of disease, but has been associated with opportunistic central nervous system (CNS) infections, most notably progressive multifocal leukoencephalopathy. Varicella-zoster and herpes simplex viruses have-also been associated with NTZ, inciting a spectrum of disease, including encephalitis, meningitis, and acute retinal necrosis. While rare, these infections can result in devastating outcomes even when promptly identified and treated.

We present a case of combined CNS varicella zoster vasculitis and acute retinal necrosis in a 57-year-old woman maintained on monthly Natalizumab therapy, who presented with headache and visual field deficits.

KEYWORDS: multiple sclerosis, immunotherapy, CNS, retina

HISTORY

A 57-year old female with relapsing-remitting multiple sclerosis (MS) was maintained on monthly infusions of Natalizumab (Tysabri®) since 2009, with good compliance. The last clinical flare of MS occurred over 20 years ago. She presented to the emergency department with a 10-day history of visual changes. She reported symptoms of blurry vision and a light headache 10 days prior, which lasted for one day and resolved without intervention. Symptoms returned five days later with blurry vision, floaters, and retro-orbital headaches. Despite no prior history of migraine headaches, the presentation was believed to be related to migraine with aura, for which the patient was prescribed sumatriptan. Her visual complaints continued to progress to a complete left-sided visual field deficit, prompting her to seek emergent medical care.

On examination there were visual field restrictions involving left superior temporal and superior nasal and right superior and inferior nasal fields, with 2mm pupils that responded sluggishly to light. The remainder of the neurological examination was unremarkable.

The patient had normal ophthalmologic examinations in the past, though she had not been seen by an ophthalmologist in the past few years. At presentation, fundoscopic images of both eyes revealed retinal necrosis with associated hemorrhage, particularly along the inferior arcade (**Figure 1**).

T2-weighted fluid-attenuated inversion recovery (FLAIR) MR imaging obtained 17 months prior to presentation demonstrated characteristic findings of multiple sclerosis, including both juxtacortical and periventricular white matter lesions (**Figure 2A**). T2-FLAIR on admission showed unchanged white matter lesions (**Figure 2B**). Axial diffusion-weighted images (DWI) showed new punctate foci of reduced diffusivity, notably at the grey-white matter interface (**Figure 3A**) and in the bilateral thalami (**Figure 3B**). Gadolinium-enhanced T1-weighted MR images demonstrated punctate foci of enhancement, some of which corresponded to diffusion-restricted lesions (**Figure 3C).**

Diagnosis of vasculitis and acute retinal necrosis caused

Figure 1. Fundoscopic images of the right eye (OD) demonstrates retinal necrosis along the inferior arcade with temporal dot-blot hemorrhages and of the left eye (OS) shows extensive retinal necrosis particularly along the inferior arcade with associated hemorrhage.

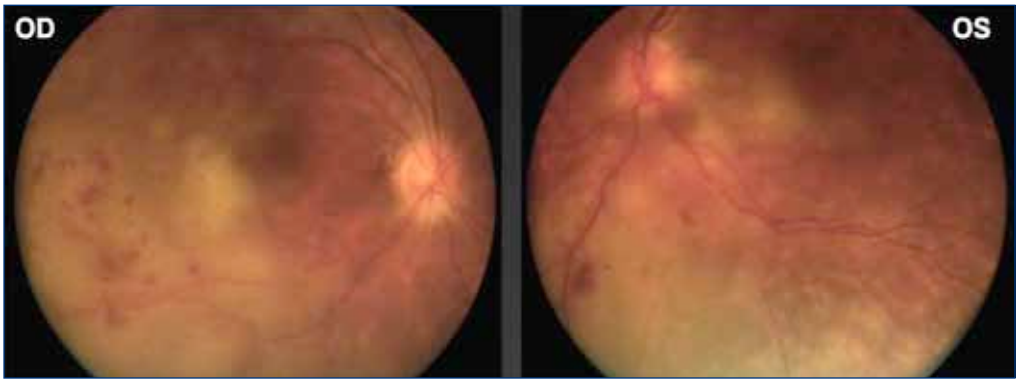

Figure 2. [**A**] Axial T2-FLAIR MR imaging performed 17 months prior to presentation demonstrates typical juxtacortical and periventricular white matter hyperintensities seen in multiple sclerosis. [**B**] Axial T2-FLAIR imaging performed at time of presentation shows near identical appearance of lesions, consistent with chronic multiple sclerosis.

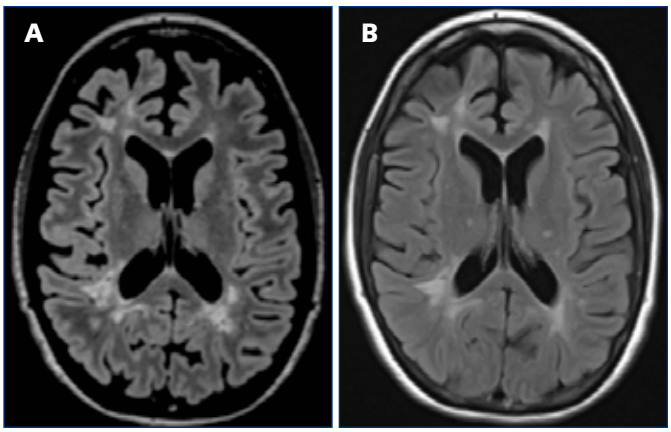

Figure 3. [**A**] Axial DWI MR imaging performed at time of presentation show multiple foci of reduced diffusivity including in the right middle frontal gyrus and [**B**] bilateral thalami. [**C**] Post-contrast Axial T2-weighted MR imaging shows punctate foci of enhancement, including a focus of enhancement which corresponds to diffusion restricting lesion in the left thalamus.

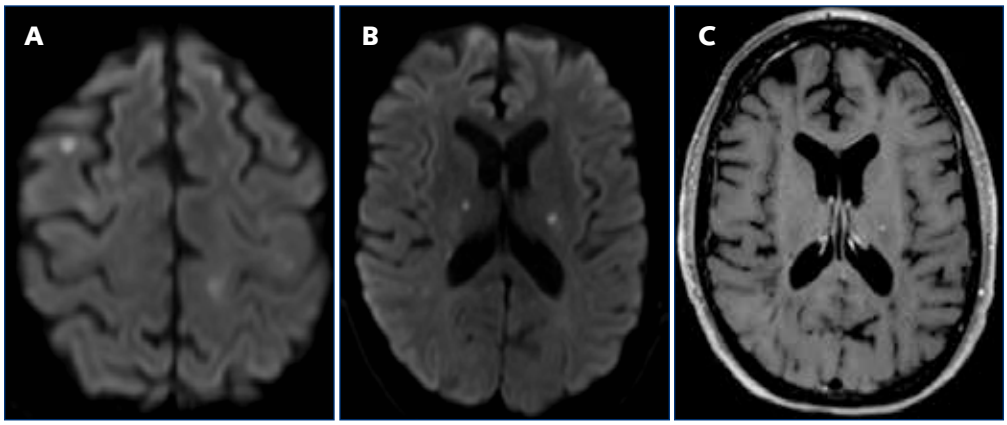

by infection with varicella zoster virus (VZV) was confirmed by the presence of anti-VZV antibodies in the cerebral spinal fluid (CSF) and polymerase chain reaction (PCR) of anterior chamber paracentesis with greater than 8 million copies/mL of VZV. Serum human immunodeficiency virus (HIV) screening was negative. Cytomegalovirus (CMV) and herpes simplex virus 1 and 2 (HSV) PCR testing in the CSF and intraocular fluid were negative. Bilateral acute retinal necrosis was treated with intravitreal ganciclovir and foscarnet but progressed to bilateral retinal detachment. She was systemically treated for VZV vasculopathy with intravenous acyclovir for two weeks, then transitioned to oral valacyclovir to complete therapy as an outpatient.

DISCUSSION

Natalizumab has been implicated in the development of opportunistic infections, including-CNS infections. To date only a few case reports of VZV reactivation with the development of acute retinal necrosis and small-vessel vasculopathy have been reported with use of NTZ.

Natalizumab is a monoclonal antibody approved for treatment of relapsing-remitting MS and Crohn's Disease. NTZ binds to the alpha4-integrin expressed on activated T-cells and other leukocytes by antagonizing the interaction with adhesion molecules on endothelial cells such as VCAM-1. This inhibits transmigration of T-cells and autoreactive leukocytes across the vascular wall into the CNS.[1,2] However, NTZ substantially decreases the CD4(+)/CD8(+) ratio in CSF compared with peripheral blood, resulting in impaired immune surveillance.[3] Consequently, NTZ has been associated with severe CNS infections. For this reason, NTZ was briefly removed from the market following the development of cases of progressive multifocal leukoencephalopathy. The medication was reintroduced, but with mandatory surveillance through the Tysabri Outreach: Unified Commitment to Health (TOUCH) Prescribing Program.[2] While rare, there is also an increased risk for NTZ associated herpes infection, most commonly encephalitis and meningitis. Even less frequent are cases of vasculitis and retinitis, only described in the setting of varicella zoster virus.[4,5]

Primary infection with VZV produces the viral exanthem chickenpox, following which the virus establishes latency in ganglionic neurons along the neuroaxis. With advancing age or immunosuppression, a decline in VZV-specific cell-mediated immunity results in viral reactivation, causing herpes zoster, which may be complicated by postherpetic neuralgia, neurological disorders, and ocular disease. The most common manifestation of VZV reactivation in the central nervous system is vasculitis. Meningitis, encephalitis, and myelitis are less common. A diagnosis can be confirmed by demonstration of intrathecal synthesis of anti-VZV antibodies, presence of viral DNA in CSF, or temporal association of herpetic rash with disease onset, either alone or in combination.[6]

Natalizumab has also been implicated in the development of acute retinal necrosis (ARN), a rare condition characterized by necrotizing retinitis, retinal detachment, and vitritis. Varicella zoster virus is the leading cause of ARN

accounting for 50% to 80% of cases, followed by herpes simplex virus types 1 and 2. Since the incidence of ARN in the general population is only 0.63–2.0 per million, it is posited that the risk for VZV-associated ARN in patients treated with NTZ may be increased by as much as 16 times.[7] Severe vision loss often occurs despite expeditious medical treatment with intravitreal and systemic antivirals.

In summary, this is a case of small-vessel vasculopathy and acute retinal necrosis caused by varicella zoster virus infection in a patient whose long-standing multiple sclerosis had been well-controlled on Natalizumab. In addition to both fundoscopy and MR imaging, this diagnosis was confirmed by presence of anti-VZV antibodies in CSF and identification of VZV by PCR in anterior chamber aqueous humor. The chronically immunocompromised state from NTZ treatment was believed to be primary etiology for reactivation of VZV. Following confirmation of the diagnosis, acute retinal necrosis was treated with intravitreal ganciclovir and foscarnet, but progressed to bilateral retinal detachments. Treatment with intravenous acyclovir and oral valacyclovir led to stabilization of MR imaging signs of vasculitis with resolution of multiple diffusion restricting and enhancing foci on follow-up imaging obtained one month after presentation.

References

1. Fine AJ, Sorbello A, Kortepeter C, Scarazzini L. Central nervous system herpes simplex and varicella zoster virus infections in natalizumab-treated patients. Clin Infect Dis [Internet]. 2013;57(6):849–52. Available from: http://dx.doi.org/10.1093/cid/cit376
2. Selewski DT, Shah GV, Segal BM, Rajdev PA, Mukherji SK. Natalizumab (tysabri). AJNR Am J Neuroradiol [Internet]. 2010;31(9):1588–90. Available from: http://dx.doi.org/10.3174/ajnr.A2226
3. Stüve O, Marra CM, Bar-Or A, Niino M, Cravens PD, Cepok S, et al. Altered CD4+/CD8+ T-cell ratios in cerebrospinal fluid of natalizumab-treated patients with multiple sclerosis. Arch Neurol [Internet]. 2006;63(10):1383–7. Available from: http://dx.doi.org/10.1001/archneur.63.10.1383
4. van Kempen ZLE, van Rossum JA, Hoogervorst E, Strijbis E, Toorop A, Bosscha MI, et al. Varicella zoster-associated acute retinal necrosis and central nervous system complications in natalizumab treated MS patients. Mult Scler Relat Disord [Internet]. 2021;50(102838):102838. Available from: http://dx.doi.org/10.1016/j.msard.2021.102838
5. Kobeleva X, Wegner F, Brunotte I, Dadak M, Dengler R, Stangel M. Varicella zoster-associated retinal and central nervous system vasculitis in a patient with multiple sclerosis treated with natalizumab. J Neuroinflammation [Internet]. 2014;11(1):19. Available from: http://dx.doi.org/10.1186/1742-2094-11-19
6. Nagel MA, Gilden D. Neurological complications of varicella zoster virus reactivation. Curr Opin Neurol [Internet]. 2014;27(3):356–60. Available from: http://dx.doi.org/10.1097/WCO.0000000000000092
7. Muthiah MN, Michaelides M, Child CS, Mitchell SM. Acute retinal necrosis: a national population-based study to assess the incidence, methods of diagnosis, treatment strategies and outcomes in the UK. Br J Ophthalmol [Internet]. 2007;91(11):1452–5. Available from: http://dx.doi.org/10.1136/bjo.2007.114884

Authors

Erika L. Thayer, DO, The Warren Alpert Medical School of Brown University; Rhode Island Hospital Department of Diagnostic Imaging, Providence, RI.

Syed A. Rizvi, MD, The Warren Alpert Medical School of Brown University; Rhode Island Hospital Department of Neurology, Providence, RI.

Glenn A. Tung, MD, The Warren Alpert Medical School of Brown University; Rhode Island Hospital Department of Diagnostic Imaging, Providence, RI.

Correspondence

Erika Thayer, DO
593 Eddy Street
Providence, RI 02903
401-444-5828
ethayer@lifespan.org

Caught by POCUS: Post-TAVR Pericardial Effusion

KENNETH N. JOHN, MD; MICHAEL CRADEUR; GEOFFREY HAYWARD, MD; SHYAMAL ASHER, MD

ABSTRACT

Point-of-care ultrasound (POCUS) is becoming increasingly popular in the field of anesthesiology and is being incorporated into anesthesia resident education. Ultrasound provides a portable, quick, and inexpensive diagnostic tool to help guide clinicians in their decision making and management of medically complex patients. One important utilization of POCUS is helping to guide management of undifferentiated hypotension. We present a case of a patient who underwent a Transcatheter Aortic Valve Replacement (TAVR) procedure who then suffered from hypotension in the post-anesthesia care unit (PACU). POCUS was used to help identify the cause of the patient's hypotension and led to the diagnosis of a pericardial effusion.

INTRODUCTION

The pericardium is the outermost layer of the heart, providing lubrication and support for the myocardium.[1] Fluid accumulation in this space is known as a pericardial effusion.[2] As fluid accumulates, patients progress from asymptomatic to the most severe forms, which obstruct venous return to the heart, causing a decrease in cardiac output. The latter is known as cardiac tamponade and is a medical emergency requiring prompt recognition and treatment.[3]

Transcatheter Aortic Valve Replacement (TAVR) procedures have become more common over the past decade with rapidly advancing technology.[4] One complication associated with this procedure is a pericardial effusion.[5] In this case report, we describe a clinical scenario of a patient who underwent a TAVR and developed hypotension at the end of the case. A POCUS exam in the PACU helped diagnose a new pericardial effusion causing hypotension and helped to direct appropriate medical therapy for this patient.

CASE PRESENTATION

Our patient was a 89-year-old female with a past medical history that included hypothyroidism, atrial fibrillation, a permanent pacemaker (PPM) due to sick sinus syndrome, and a bicuspid aortic valve with severe aortic stenosis (AS). A transthoracic echocardiogram (TTE) demonstrated an aortic valve area (AVA) of 0.6 cm^2 with mildly reduced left ventricular function (LVEF 51%) and no other remarkable findings. After consultation with the structural heart clinic, the patient was scheduled for an elective TAVR.

On the day of the procedure, the patient received moderate sedation with midazolam, fentanyl, and dexmedetomidine. An arterial line was placed for hemodynamic monitoring and supplemental oxygen was provided via facemask. After a seemingly uneventful valve deployment, an intraoperative TTE was done which was unremarkable in its findings. Post procedure, the patient's blood pressure began

Figure 1. Cardiac POCUS Imaging

[**A**] Subcostal 4-Chamber view: arrows and circle show the pericardial effusion adjacent to the right atrium and ventricle. [**B**] Parasternal Short-Axis view: arrows and circles show the pericardial effusion below the inferior wall of the left ventricle.

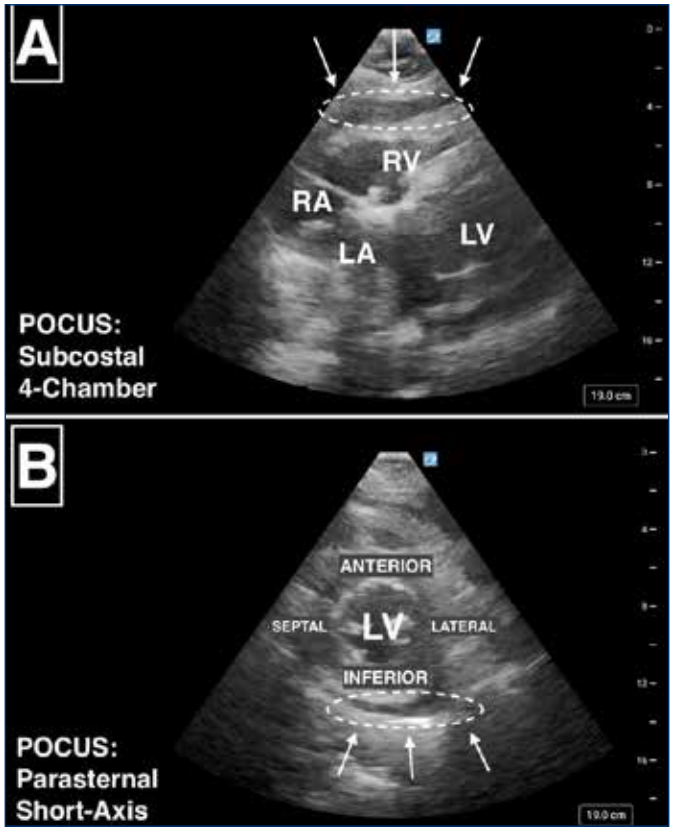

RA = right atrium, RV = right ventricle, LA = left atrium, LV = left ventricle

to slowly downtrend, requiring fluid boluses and a phenylephrine infusion to restore normotension. Due to her deteriorating clinical picture, a cardiac POCUS examination was performed to evaluate the cause of the patient's persistent hypotension. A pericardial effusion was noted (**Figure 1**) and the interventional cardiac procedural team was notified.

Considerations raised with the procedural team included the adequacy of heparin anticoagulation reversal, the urgency to drain the pericardial effusion, and further resuscitative efforts. Ultimately, the decision was made to continue observing the patient in the PACU for any further hemodynamic compromise and to monitor the pericardial effusion for any further expansion. Subsequently, a formal TTE in the CCU demonstrated a moderate circumferential pericardial effusion, a plethoric IVC without respiratory variation, no right atrial systolic collapse, some right ventricle diastolic compression, and some fibrinous material in the pericardium (**Figure 2**). Repeat echocardiograms later in the day showed a stable effusion without signs of worsening tamponade physiology. With further resuscitative efforts, the patient was eventually weaned off of phenylephrine. Follow-up TTE the next day showed a stable effusion and the patient was ultimately discharged home.

Figure 2. Formal Transthoracic Echocardiogram

[**A**] Subcostal 4-Chamber View and [**B**] Parasternal Short-Axis show the pericardial effusion outside of both ventricles (demonstrated by the arrows and circles). [**C**] Subcostal Long-Axis of the IVC shows a plethoric inferior vena cava dilated to 2.34cm. [**D**] Apical 4-Chamber shows fibrinous material in the pericardial space as demonstrated by the circle with the arrows pointing towards the pericardial effusion wrapping around the LV.

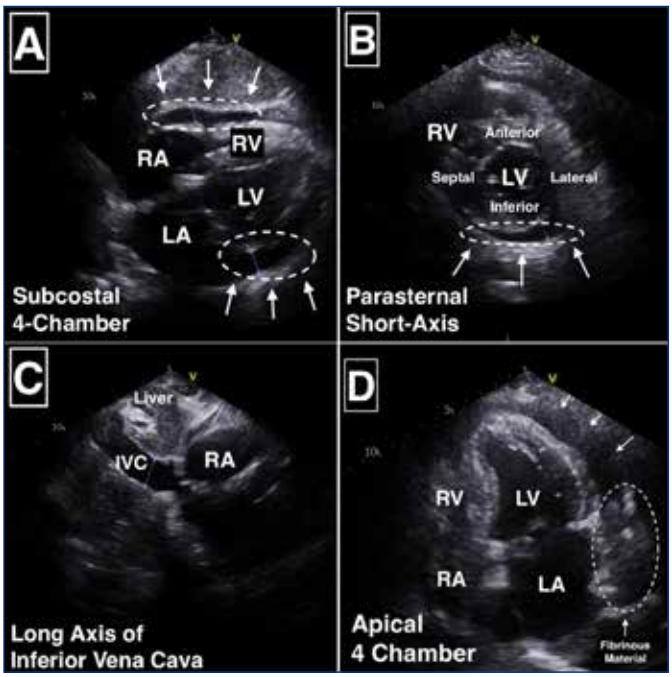

RA = right atrium, RV = right ventricle, LA = left atrium, LV = left ventricle

DISCUSSION

One of the benefits of TAVR over open surgical valve replacement (SAVR) is the relative non-invasive nature of the procedure. In the past two decades, the typical anesthetic plan has shifted towards moderate sedation over GA for TAVR procedures.[5] There are two major benefits to this technique. The first is early recognition of neurologic dysfunction if the patient requires less time to regain consciousness after moderate sedation as compared to GA. The second is allowing the anesthesia provider to focus more on procedural causes of hypotension rather than anesthetic causes such as: valve malposition, paravalvular regurgitation, conduction abnormalities, coronary hypoperfusion, hypovolemia, and pericardial effusions.[6]

POCUS is a bedside tool that can be used to evaluate the heart and lungs to aid in diagnosis, medical intervention, and acute procedures.[6] The cardiac assessment is a particularly helpful tool in the evaluation of hypotension, specifically looking at cardiac function, volume status, valvulopathies, and a pericardial effusion causing tamponade physiology. Determining the specific cause of the patient's hypotension may lead to the correct treatment to fix the underlying problem. Ultimately, we discovered an effusion best visualized in the subcostal 4-chamber and parasternal short-axis views (**Figure 1**).

Echocardiography is a simple, accurate, and reliable tool to assess the size, location, and hemodynamic impact of an effusion.[7] These qualifications make it very valuable for diagnosis and classification of pericardial effusions.

CONCLUSION

While the clinical presentation of pericardial effusions may seem insidious and complex, physicians can make a rapid and accurate diagnosis of effusion and hemodynamic impact using a combination of clinical signs and symptoms augmented with the diagnostic advantage of a bedside POCUS evaluation, leading to the appropriate management of the patient.

References

1. Bonow RO, et al. Braunwald's heart disease e-book: A textbook of cardiovascular medicine. 2011: Elsevier Health Sciences.
2. Hoit BD. *Pericardial effusion and cardiac tamponade in the new millennium.* Current Cardiology Reports, 2017;19(7):1-11.
3. Appleton C, Gillam L, Koulogiannis K. *Cardiac tamponade.* Cardiology clinics, 2017; 35(4):525-537.
4. Butala NM, et al. *Conscious sedation versus general anesthesia for transcatheter aortic valve replacement: variation in practice and outcomes.* Cardiovascular Interventions, 2020; 13(11): 1277-87.
5. Laborde JC, Brecker SJD, Roy D, Jahangiri M. *Complications at the Time of Transcatheter Aortic Valve Implantation.* Methodist DeBakey CVJ, 2012;**7**(2): 38-41.
6. Naji A, Chappidi M, et al. *Perioperative Point-Of-Care Ultrasound Use by Anesthesiologist.* Cureus, 2021;13(5):e15217.
7. Feigenbaum H, Waldhausen JA, Hyde LP. *Ultrasound diagnosis of pericardial effusion.* Jama, 1965;191(9):711-714.

Authors

Kenneth N. John, MD, Department of Anesthesiology at Rhode Island Hospital; Warren Alpert Medical School of Brown University, Providence, RI.

Michael Cradeur, Department of Anesthesiology at Rhode Island Hospital; Warren Alpert Medical School of Brown University, Providence, RI.

Geoffrey Hayward, MD, Department of Anesthesiology at Rhode Island Hospital; Warren Alpert Medical School of Brown University, Providence, RI.

Shyamal Asher, MD, Department of Anesthesiology at Rhode Island Hospital; Warren Alpert Medical School of Brown University, Providence, RI.

Disclosures

Conflict of Interest: The authors of this paper have no conflicts of interest to disclose.

Funding: None

Correspondence

Kenneth N. John, MD
kjohn1@bidmc.harvard.edu

Postherpetic Neuralgia After Herpes Zoster Ophthalmicus

MARY M. KELLY, MD; SOKUNVICHET LONG, MD; CELINE SAADE, MD; GLENN A. TUNG, MD, FACR

CLINICAL HISTORY

A 77-year-old woman presented to the emergency department with severe right eye pain, periorbital swelling and blurry vision. Five days prior to presentation, she developed itching around her right eye followed by a vesicular rash on the right side of her face. She was prescribed antibiotics but had progressive worsening of her symptoms. The patient reported a history of chickenpox as a child and shingles vaccination as an adult.

On presentation she was febrile with physical examination notable for a vesicular rash with honey-colored crusting over the right eye, forehead and upper nose. Skin swab from a lesion on her forehead was positive for varicella zoster virus (VZV). CT (**Figure 1**) and MR imaging of the brain and orbits revealed diffuse right periorbital and facial soft tissue edema with a periorbital rim-enhancing fluid collection.

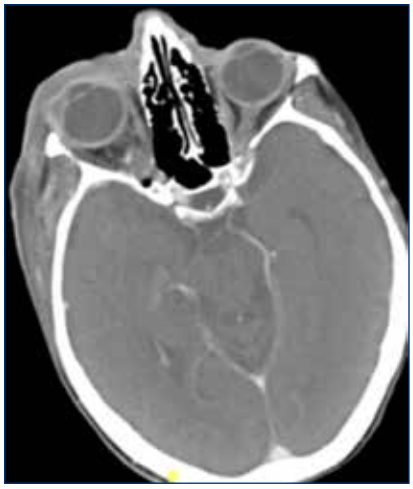

Figure 1. Herpes Ophthalmicus. Axial contrast-enhanced CT demonstrates right periorbital and lateral facial soft tissue edema.

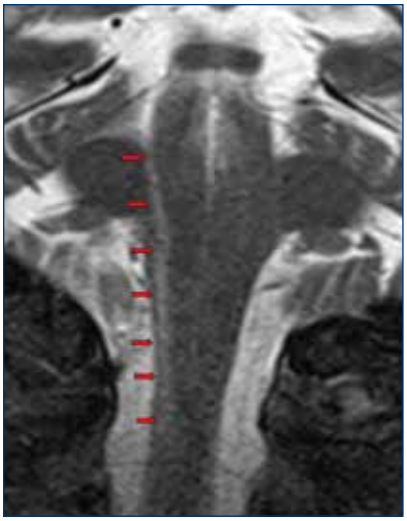

Figure 3. Post-herpetic neuralgia manifesting as hyperintense signal on coronal T2-weighted MRI in the right trigeminal spinal nucleus. Coronal T2-weighted MR magnified inset shows linear hyperintense signal corresponding to trigeminal spinal nucleus (red arrow) from pons to upper cervical cord.

The patient was admitted and initially treated with intravenous acyclovir as well as ampicillin/sulbactam, vancomycin, and linezolid. On the day of discharge, repeat MRI demonstrated linear T2-hyperintense signal within the right dorsolateral medulla extending into the cervical spinal cord (**Figures 2,3**). The following week she was seen in clinic, where she reported intermittent pain around her eye. Residual crusting was observed around her eye on physical examination. She completed her final course of antibiotics two weeks after discharge with a plan for continued follow-up with ophthalmology.

Figure 2. Post-herpetic neuralgia manifesting as hyperintense signal on serial transverse axial T2-weighted MR images in the right trigeminal spinal nucleus. [**A**] Transverse axial MR imaging from mid-pons, [**B**] through medulla, and [**C**] upper cervical cord show focal hyperintense signal along course of right trigeminal spinal nucleus (red arrow).

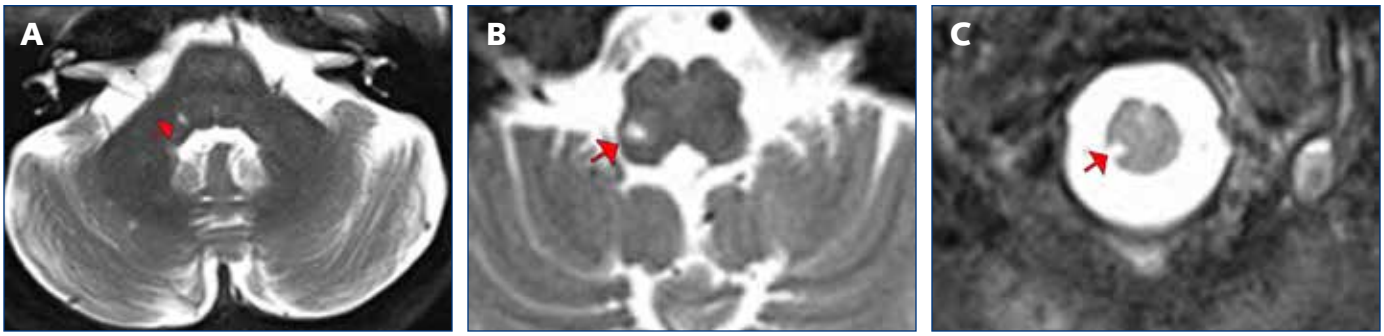

DISCUSSION

Herpes zoster is a viral infection caused by reactivation of the varicella-zoster virus (VZV). The virus remains latent in the dorsal root ganglion after primary varicella infection until reactivation later in life. Herpes zoster can damage peripheral nerves and result in a neuropathic pain condition called postherpetic neuralgia (PHN). Wilcox et al studied the association of chronic neuropathic pain with anatomic changes. Compared with pain-free controls, patients with chronic trigeminal neuropathy had decreased volume of the spinal trigeminal nucleus as well as decreased mean diffusivity and increased fractional anisotropy on diffusion tensor imaging.[1] Haanpaa et al found an association between MRI abnormalities and the subsequent development of PHN: 56% of patients who had positive MRI findings of herpes zoster reported pain three months after infection, whereas all patients who had a normal initial MRI were pain-free.[2] MRI may therefore be a useful predictor of which patients will suffer long-term pain.

Herpes zoster ophthalmicus specifically refers to infection in the distribution of the ophthalmic branch of the trigeminal nerve (V_1), which provides sensory information from the upper face and scalp including the eye. Patients have involvement of the spinal nucleus of the trigeminal nerve, which receives sensory information from the ipsilateral face with input from the trigeminal, facial, glossopharyngeal and vagus nerves. The trigeminal nucleus extends from the dorsolateral pons and medulla to the level of the C3 vertebral body (**Figure 4**). This corresponds to the site of abnormal signal intensity that we report in this patient. Case reports have suggested the possibility of trans-axonal migration of VZV, including spread of the virus to the spinal trigeminal nucleus from the trigeminal ganglion in Meckel's cave,[3] geniculate ganglion,[4] and glossopharyngeal ganglion.[5]

While there have been case reports of patients with herpes zoster ophthalmicus with abnormalities of the spinal trigeminal nucleus and tract on MRI,[6-8] these findings are thought to be rare. Our case of postherpetic neuralgia after herpes zoster ophthalmicus with corresponding increased T2/FLAIR signal intensity in the ipsilateral trigeminal spinal nucleus is consistent with trans-axonal migration of VZV from the ophthalmic nerve (V_1) to the spinal nucleus of the trigeminal nerve.

Figure 4. Spinal Nucleus of the Trigeminal Nerve. The trigeminal nuclei are depicted on this parasagittal figure of the brainstem: mesencephalic (m), main (M) and spinal. Spinal trigeminal nucleus (red arrow) receives information about deep and crude touch, pain and temperature from the ipsilateral face and extends from pons through the medulla and to level of upper cervical cord, approximately C2 to C3, where it becomes continuous with dorsal horn of cervical cord. V, trigeminal cranial nerve; V1, ophthalmic nerve; V2, maxillary nerve; V3, mandibular nerve.

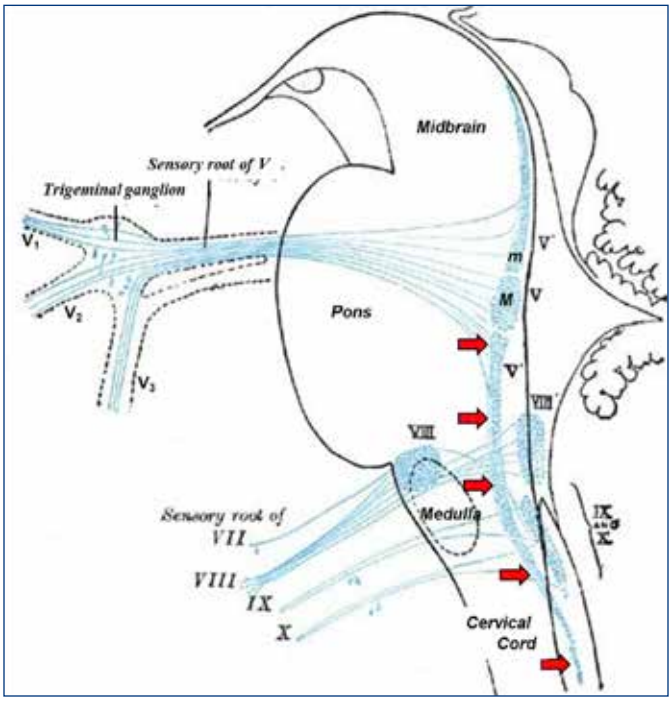

References

1. Wilcox SL, Gustin SM, Macey PM, et al. Anatomical changes at the level of the primary synapse in neuropathic pain: evidence from the spinal trigeminal nucleus. *The Journal of neuroscience.* 2015;35(6):2508-15. doi:10.1523/JNEUROSCI.3756-14.2015
2. Haanpää M, Dastidar P, Weinberg A, et al. "CSF and MRI findings in patients with acute herpes zoster." *Neurology*. 1998;51(5):1405-11. doi:10.1212/wnl.51.5.1405
3. Nagane Y, Utsugisawa K, Yonezawa H, et al. [A case with trigeminal herpes zoster manifesting a long lesion of the spinal trigeminal nucleus and tract on MR T2-weighted image]. *Rinsho shinkeigaku.* 2001;41(1):56-9.
4. Nogueira RG, Steeley WW. Ramsay Hunt syndrome associated with spinal trigeminal nucleus and tract involvement on MRI. *Neurology.* 2003;61(9):1306-7. doi:10.1212/wnl.61.9.1306-a
5. Clerke-Lamalice O, Savage J, Fisch C. Long-term MRI signal change in the spinal trigeminal nucleus and tract after Ramsay-Hunt syndrome and trigeminal herpes zoster. *Neurographics.* 2015;5(2):68-71. doi: 10.3174/ng.2150107
6. Aribandi M, Aribandi L. MRI of trigeminal zoster. *Neurology.* Dec 2005;65(11):1812. doi: 10.1212/01.wnl.0000190261.55547.97
7. Mufti M, Shackles C, Alvi E, et al. Herpes zoster ophthalmicus caught in the (Tr)act! *Emerg Radiol.* 2018;25:557–559. doi: 10.1007/s10140-018-1622-y
8. Yong H, Wallace C, Kapadia R. 'Trigeminal Tract Sign' in Patients With Herpes Zoster Ophthalmicus: A Case Series of a Novel Imaging Finding. *Neurology.* Dec 2022;99(23 Supplement 2) S70-77. doi: 10.1212/01.wnl.0000903564.62886.c1

Authors

Mary M. Kelly, MD, Department of Diagnostic Imaging, Rhode Island Hospital, Providence, RI.

Sokunvichet Long, MD, Department of Internal Medicine, Rhode Island Hospital, Providence, RI.

Celine Saade, MD, Department of Ophthalmology, Brown University, Providence, RI.

Glenn A. Tung, MD, FACR, Professor of Diagnostic Imaging, Brown University, Providence, RI.

Correspondence

Mary M. Kelly, MD

Rhode Island Hospital, 593 Eddy St, Providence, RI, 02903

mkel244@gmail.com

Internal Versus External Intrapartum Monitoring and Birthing Persons Perception of Control During Childbirth

BROCK E. POLNASZEK, MD; ANNA R. WHELAN, MD; OLIVIA RECABO, MD; JULIA ROSSEN, BA; ADAM K. LEWKOWITZ, MD, MPHS; NINA K. AYALA, MD

KEYWORDS: Labour agentry scale, internal monitors, amnioinfusion

INTRODUCTION

Perception of control over labor and birth has been demonstrated to significantly affect a birthing person's experience and potentially impact postpartum wellbeing.[1-4] Internal monitors (i.e., fetal scalp electrode (FSE) and intrauterine pressure catheter (IUPC) with/without amnioinfusion (AI)) are invasive monitors used for management of labor complications including non-reassuring fetal status.[5] There has been no published research which explores how the presence or absence of internal monitors affects birthing persons' perception of control during childbirth. In this study, we investigated the association of internal compared to external intrapartum monitors with birthing person's perception of control during childbirth.

METHODS

We performed a secondary analysis of a cross-sectional survey of 149 nulliparous birthing persons who were pregnant at ≥ 37 weeks with singleton gestations and admitted to a large academic medical center in July–August 2021.[1] Birthing persons were ineligible in the primary study if scheduled for cesarean birth, had a contraindication to trial of labor, or were non-English speaking.[1] Birthing persons were identified for inclusion via chart review and all were approached during their postpartum hospital stay during the study period. Following delivery, birthing persons completed the LAS, a validated tool to assess perceived control over childbirth in which lower scores represent lower perceived control or agentry.[1,3] A post-hoc sample size calculation based on median LAS score from prior literature determined that 120 patients would provide 80% power (with two sided type I error of 5%) to detect a difference of 16 points on LAS.

Demographics, perinatal outcomes, and LAS scores were compared between birthing persons with internal (i.e. FSE, IUPC, AI) and external monitors intrapartum. LAS scores were stratified by specific internal monitor utilized and compared to only external monitoring. Multivariable linear regression for LAS scores by internal versus external monitors were calculated, controlling for mode of delivery, length of labor, and medical comorbidities based on bivariate analysis. The study was approved by the Institutional Review Board (IRB) before study enrollment #1691795, March 30, 2021.

RESULTS

Of the 160 participants from the primary study, 49 (30.6%) had internal monitors during their labor course. There were no differences in maternal age, race, gestational age at delivery, or select perinatal outcomes between those who had internal versus external monitors. Birthing persons who had internal monitors were more likely to have a medical comorbidity (44.9% vs 25.7%, p-value 0.02) and to deliver by cesarean section (57.1% vs 16.8%, p-value <0.001) compared to those with external monitors. Bivariate analysis of LAS scores revealed lower scores among those requiring internal monitors compared to external monitors (median [interquartile range/IQR] 146 [135–162] versus (162 [145–181]), p-value <0.001) **Table 1**. However, after controlling for mode of delivery, length of labor, and medical comorbidities, no significant difference in LAS scores were identified between those monitored internally versus externally (165 versus 162, p-value 0.42).

When analyzed by specific internal monitor, birthing persons who required IUPC had lower LAS scores (n=47; 145 [132–158]) while FSE (n=18; 155 [144–177]) and AI (n=14; 152 [141–166]) demonstrated no differences in LAS scores compared to birthing persons with external monitors respectively.

DISCUSSION

Among birthing persons who required the use of internal monitors (e.g. FSE, IUPC with or without AI), lower perceived control over labor was associated with labor ending in cesarean delivery, not the presence of internal monitors alone. Despite no difference in perceived control of childbirth overall, there were differences in birthing persons perceived control over labor by specific monitor (i.e. n=47 IUPC 146 [132-158] and n= 18 FSE 155 [144–177) but not with amnioinfusion alone (i.e. n=14 AI 152 [141–166]). These data add new understanding to the perceptions that birthing people experience during labor and childbirth communications

Table 1. Perinatal outcomes by intrapartum monitoring method and patients' perception of control

	External monitors N=111	Internal monitors† N=49	p–value
Labour Agentry Scale score, median (IQR)	162 (145–181)	146 (135–162)	<0.001
Maternal age, median (IQR)	29 (25–32)	28 (24–32)	0.44
Gestational age, median (IQR)	39.7 (38.9–40.6)	39.7 (38.7–41)	0.39
Self-reported race/ethnicity			
White	82 (72.6)	30 (61.2)	0.20
Black	7 (6.2)	2 (4.1)	0.72
Latina	20 (17.7)	14 (28.6)	0.14
Indigenous	3 (2.7)	2 (4.1)	0.64
Asian/Pacific Islander	1 (0.9)	1 (2.0)	0.52
Primary insurance			0.89
Public	31 (29.5)	14 (32.6)	
Private	73 (69.5)	29 (67.4)	
Self-pay	1 (1.0)	0	
Highest level of education			0.06
High School/GED or less	29 (27.5)	19 (44.2)	
Above High School	75 (72.4)	24 (55.8)	
Maternal comorbidities§	29 (25.7)	22 (44.9)	0.02
Chronic hypertension	6 (5.7)	11 (25.6)	0.001
Hypertensive disorders of pregnancy	7 (6.7)	15 (34.9)	<0.001
Pregestational diabetes	1 (1.0)	1 (2.3)	0.50
Gestational diabetes	6 (5.7)	4 (9.3)	0.48
Thyroid disease	6 (5.7)	3 (7.0)	0.72
SARS-CoV-2 infection	2 (1.9)	4 (9.3)	0.05
Mode of delivery			<0.001
Spontaneous vaginal delivery	87 (77.0)	19 (38.8)	
Operative vaginal delivery	7 (6.2)	2 (4.1)	
Cesarean delivery	19 (16.8)	28 (57.1)	
Method of anesthesia			
Neuraxial	95 (90.5)	42 (97.7)	0.18
Nitrous oxide	3 (2.9)	2 (4.7)	0.63
Intravenous	5 (4.8)	0	0.32
Local	7 (6.7)	1 (2.3)	0.44
Birthweight grams, median [interquartile]	3360 [3028–3695]	3415 [3010–3679]	0.75
NICU Admission	8 (7.2)	7 (14.3)	0.24
Neonatal therapy*	16 (14.2)	8 (16.3)	0.81

Data are N(%) unless otherwise stated. Significance at p<0.05.

Fisher's exact and Wilcoxon Ranksum tests used for analysis.

IQR = interquartile range, NICU = NICU

†Fetal scalp electrode, intrauterine pressure catheter, and/or amnioinfusion

‡Adjusted for maternal comorbidities, length of labor, and cesarean delivery

§Maternal medical comorbidities include: chronic hypertension, hypertensive disorders of pregnancy, pregestational diabetes and gestational diabetes, thyroid disease and SARS-CoV-2 infection.

*Neonatal therapy = need for supplemental oxygen, phototherapy for jaundice, neonatal antibiotics

with their obstetric providers.[1,6-11] Provider concerns for labor ending in cesarean delivery should be communicated as early as possible during intrapartum care to improve patients' perception of control.

The association between a birthing persons experience in childbirth and their perinatal mental health is particularly relevant as the American College of Obstetricians and Gynecologist report that perinatal mental health conditions affect more than one in five birthing people and are among the most common complications during the first year after childbirth.[6-12] Future studies should examine if perinatal interventions designed to improve LAS will reduced traumatic childbirth and potentially subsequent perinatal mental health disorders.

LIMITATIONS

These results must be interpreted within the limitations of our secondary analysis as it is a single institution, observational data, and predominantly white birthing people. These data do not represent a comprehensive and diverse patient population which is important from a health equity and for provider-birthing person communication. Additionally, there were only 1/3 of the primary study cohort who required internal monitors which limits the interpretation of LAS scores by specific internal monitoring.

CONCLUSION

Among birthing persons who required the use of internal monitors, lower perceived control over labor was driven predominantly by cesarean delivery, not the presence of internal monitors. Future studies should focus on how to improve a birthing person's perception of control during childbirth when labor may result in cesarean delivery.

References

1. Whelan AR, Recabo O, Ayala NK, Clark MA, Lewkowitz AK. The Association of Perceived Labor Agentry and Depression and/or Anxiety. Am J Perinatol. 2023 Apr 10. doi: 10.1055/a-2051-2433. Epub ahead of print. PMID: 36894161.
2. Nilsson C, Lundgren I, Karlström A, Hildingsson I. Self reported fear of childbirth and its association with women's birth experience and mode of delivery: a longitudinal population-based study. *Women Birth*. Sep 2012;25(3):114-21. doi:10.1016/j.wombi.2011.06.001
3. Pang MW, Leung TN, Lau TK, Hang Chung TK. Impact of first childbirth on changes in women's preference for mode of delivery: follow-up of a longitudinal observational study. *Birth*. Jun 2008;35(2):121-8. doi:10.1111/j.1523-536X.2008.00225.x
4. Hodnett ED, Simmons-Tropea DA. The labour agentry scale: Psychometric properties of an instrument measuring control during childbirth. Research in Nursing; Health. 1987;10(5):301–310. https://doi.org/10.1002/nur.4770100503
5. ACOG Practice Bulletin No. 106: Intrapartum fetal heart rate monitoring: nomenclature, interpretation, and general management principles. *Obstet Gynecol*. Jul 2009;114(1):192-202. doi:10.1097/AOG.0b013e3181aef106
6. Floris L, Irion O, Courvoisier D. Influence of obstetrical events on satisfaction and anxiety during childbirth: a prospective longitudinal study. Psychol Health Med. Sep 2017;22(8):969-977. doi:10.1080/13548506.2016.1258480
7. Molgora S, Saita E, Barbieri Carones M, Ferrazzi E, Facchin F. Predictors of Postpartum Depression among Italian Women: A Longitudinal Study. Int J Environ Res Public Health. Jan 29 2022;19(3)doi:10.3390/ijerph19031553
8. Garthus-Niegel S, von Soest T, Vollrath ME, Eberhard-Gran M. The impact of subjective birth experiences on post-traumatic stress symptoms: a longitudinal study. Arch Women Ment Health. 2013;16(01):1–10
9. Allen S. A qualitative analysis of the process, mediating variables and impact of traumatic childbirth. J Reprod Infant Psychol. 1998;16(2–3):107–131
10. Czarnocka J, Slade P. Prevalence and predictors of post-traumatic stress symptoms following childbirth. Br J Clin Psychol. 2000;39(01):35–51
11. Soet JE, Brack GA, DiIorio C. Prevalence and predictors of women's experience of psychological trauma during childbirth. Birth. 2003;30(01):36–46
12. Screening and diagnosis of mental health conditions during pregnancy and postpartum. Clinical Practice Guideline No. 4. American College of Obstetricians and Gynecologists. Obstet Gynecol. 2023;141:1232–61

Authors

Brock E. Polnaszek, MD, Warren Alpert Medical School of Brown University, Department of Obstetrics and Gynecology, Division of Maternal Fetal Medicine, Women & Infants Hospital, Providence, Rhode Island.

Anna R. Whelan, MD, Warren Alpert Medical School of Brown University, Department of Obstetrics and Gynecology, Division of Maternal Fetal Medicine, Women & Infants Hospital, Providence, Rhode Island.

Olivia Recabo, MD, New York Medical College, Valhalla, New York.

Julia Rossen, BA, Warren Alpert Medical School of Brown University, Providence, Rhode Island.

Adam K. Lewkowitz, MD, MPHS, Warren Alpert Medical School of Brown University, Department of Obstetrics and Gynecology, Division of Maternal Fetal Medicine, Women & Infants Hospital, Providence, Rhode Island.

Nina K. Ayala, MD, Warren Alpert Medical School of Brown University, Department of Obstetrics and Gynecology, Division of Maternal Fetal Medicine, Women & Infants Hospital, Providence, Rhode Island.

Acknowledgment

Poster presentation February 9th 2023, Society of Maternal Fetal Medicine Annual Research Meeting #138 Patient's perception of control: Does the presence of internal or external fetal monitoring matter intrapartum?

Conflict of Interest

The authors report no conflict of interest.

Financial Disclosures

BEP receives funding from the Foundation for Society of Maternal Fetal Medicine Danielle Peress MD Memorial Fund and Gerber Foundation. AKL is supported by the NICHD (K23 HD103961) and has served on a medical advisory board for Pharmacosmos Therapeutics, Incorporated within the last year and on a medical advisory board for Shields Pharmaceuticals within the last three years. NKA is a recipient of the Robert A. Winn Diversity in Clinical Trials Career Development Award, funded by Gilead Sciences.

Correspondence

Brock Polnaszek, MD
Division of Maternal Fetal Medicine
Women & Infants Hospital
Providence, Rhode Island 02885
bpolnaszek@wihri.org

Psyche: The 5th 'P' and its Associated Impact on the Second Stage of Labor

ALEXIS C. GIMOVSKY, MD; STEPHEN S. RASIAH, MD; CHRYSTAL VERGARA-LOPEZ, PhD; PHINNARA HAS, MS; NINA K. AYALA, MD; LAURA R. STROUD, PhD

ABSTRACT

OBJECTIVE: Patients with depression during labor display dysregulated patterns of oxytocin release and this may impact second stage of labor. The objective of this study was to evaluate the association between maternal preconception and antenatal depressive disorders on the duration of second stage of labor and perinatal outcomes.

STUDY DESIGN: Secondary analysis of patients enrolled in the Behavioral and Mood in Mothers, Behavior in Infants study who reached the second stage of labor. Participants were assigned to: pre-conception only major depressive disorder (MDD), prenatal major depressive disorder, and non-depressed controls. Primary outcome was prolonged second stage of labor. Secondary outcomes included perinatal morbidities.

RESULTS: 172 patients were included. 24.4% (42/172) participants had preconception-only MDD, 42.4% (73/172) patients had prenatal MDD, and 33.1% (57/172) patients had as non-depressed controls. The adjusted pair-wise analysis between groups showed no significant difference in the duration of second stage. No statistically significant differences were noted between groups for adverse neonatal outcomes.

CONCLUSION: Maternal depressive disorders did not impact length of second stage of labor or immediate perinatal outcomes.

KEYWORDS: depression; anxiety; labor; psyche

INTRODUCTION

The adage of the "Four P's" of labor has been described for decades. The "P's" are defined as power (strength of contractions/pushing), passage (shape of maternal pelvis), passenger (size of fetus) and position (of the fetus with respect to the pelvis).[1] Although there are many other factors that contribute to the outcome of the second stage of labor, such as maternal height, age, parity, presence of diabetes, epidural anesthesia, and fetal position, the four "P's" remain clinically important and relevant to the success and/or length of the second stage of labor.[2,3]

There has been consideration of a "5th P," defined as "psyche," which reflects the psychologic state of the parturient.[1] Maternal psychiatric disorders are commonly encountered during pregnancy, with an incidence of depression in approximately 12% of pregnancies.[4] Depression in pregnancy is associated with poor perinatal outcomes including preterm birth, fetal growth restriction (FGR), and low birth weight.[5-8] In addition, maternal depression frequently co-occurs with other factors that are linked to adverse pregnancy outcomes, such as smoking, substance abuse, hypertension, and diabetes.[7]

Previous studies have shown an association between maternal anxiety and catecholamine levels which result in a longer duration of labor.[9,10] Interestingly, maternal anxiety has been proposed to have developed as an evolutionary advantage to early humans, who had to evade predators in order to survive.[11] Anxiety could have represented a response that prioritized survival. Additionally, there is some evidence that patients with depression during labor display dysregulated patterns of oxytocin release, which suggests that maternal "psyche" may have a biologically plausible impact on dysfunctional labor.[12]

Maternal depression has the potential to play a role in second stage of labor duration and could influence maternal pushing ability. Prior studies of the second stage of labor, have yielded inconsistent data regarding the optimal time to intervene by operative vaginal birth or cesarean birth during prolonged second stage labor.[13,14] Prolonged second stage of labor has been associated with maternal complications such as chorioamnionitis and obstetric anal sphincter injury, and neonatal outcomes are mixed after a prolonged second stage of labor.[15-17] There is limited evidence investigating links between maternal depressive disorders and the duration of the 2nd stage of labor despite known complications related to a prolonged 2nd stage of labor. It is important to understand the relationship between depression and the duration of the second stage as depression could potentially contribute to increased maternal and neonatal morbidity during labor.

Thus, we wanted to examine a potential association between patients with preconception only or pregnancy associated major depressive disorder (MDD) on the outcomes of the second stage of labor. We hypothesized that maternal depression would influence maternal pushing ability and therefore increase the length of the second stage of labor. The objective of this study was to evaluate the effect of preconception and prenatal MDD on the duration of the second stage of labor. Secondary outcomes regarding maternal and neonatal outcomes related to the second stage of labor were also evaluated.

MATERIALS AND METHODS

This is a secondary analysis of women enrolled in the Behavioral and Mood in Mothers, Behavior in Infants (BAMBI) study, which was performed between March 2008 and January 2013 in Rhode Island. The BAMBI study was a prospective study over-sampled for women with prenatal and preconception MDD examining several behavioral and biochemical outcomes in pregnant women and their infants.[18] For this analysis, we included patients with non-anomalous, singleton gestations in cephalic presentation who reached the second stage of labor.

Patients were assigned to one of three groups: preconception-only MDD, prenatal MDD, and non-depressed control. The preconception MDD group included women with a history of one or more lifetime major or minor depressive episodes before the current pregnancy and conception window. The prenatal MDD group included women who met criteria for major or minor depressive episode at any time during the current pregnancy or within three months of conception. Patients in the prenatal MDD group included those with and without episodes of lifetime preconception MDD. Control patients were free of lifetime and current mood disorder diagnoses.

Participants completed up to three interviews between 18 and 39 weeks of pregnancy, and immediately post-birth interview on postpartum day one or two, and an interview at one month postpartum. Evaluation for prenatal MDD included the 3rd trimester and immediate postpartum period during the birthing hospitalization. At the first interview, patients completed the mood, anxiety and psychotic screen modules of the Structured Clinical Interview for Diagnostic and Statistical Manual of Mental Disorders, Fourth Edition, Text Revision (DSM-IV-TR) Axis I Disorders-Research Version, Non-patient Edition.[19] Major depressive episodes were based on DSM-IV criteria; minor depressive episodes were based on DSM-IV appendix B criteria. Patients reported on lifetime and current mood disorders during the first interview. At each subsequent interview, the Structured Clinical Interview for DSM-IV current mood disorders module was administered to assess for major/minor depressive episodes since the prior assessment.

Patients also completed the Inventory of Depressive Symptomatology-Self-Rated (IDS-SR) at each prenatal interview, which included four-point Likert ratings of 21 depressive symptoms over the previous week.[20] This study converted IDS scores into Quick Inventory of Depression Symptomology (QIDS) scores to quantify the level of depression, since the QIDS scores incorporate the specific areas (mood, interest/pleasure in activities, weight/appetite, sleep, psychomotor agitation/retardation, fatigue, self-criticism, concentration, thoughts of death/suicide) used to categorize depressive disorders in the DSM-IV.[19] QIDS was designed to measure overall severity of the MDD by assessing each of the nine symptom domains that define the syndrome. The IDS assesses the same nine domains and other commonly associated symptoms (e.g., anxiety, irritability). The total QIDS scoring system ranges from 0 to 27 to quantify the degree of depression; a score of less than 5 indicates no depression, 6 to 10 signifies mild depression, 11 to 15 is moderate depression, 16 to 20 is consistent with severe depression, and a score greater than 20 is concerning for very severe depression.

In addition, Hamilton Anxiety Rating Scale (HAM-A) total scores were utilized to quantify the level of anxiety in study patients.[21] This scale uses 14 items that are scaled from 0 to 4 to quantify the level of anxiety; a score less than 17 is characterized as mild anxiety, 18 to 24 is mild/moderate anxiety, and a score greater than 24 represents severe anxiety.

The primary outcome was prolonged second stage of labor. The American College of Obstetricians and Gynecologists (ACOG) define a prolonged second stage of labor as greater than 2 hours in multiparous patients (3 hours with epidural anesthesia) and 3 hours in primiparous patients (4 hours with epidural anesthesia).[22] The definition used for prolonged second stage of labor in this study was greater than three hours, given that the patients included in the study were a combination of nulliparas and multiparas, with mixed usage of epidural anesthesia and because the BAMBI data was collected prior to 2014 and before new guidelines were implemented.

Maternal secondary outcomes included mode of birth, presence of shoulder dystocia, indication for cesarean birth (CB) (if applicable), duration of second stage of labor, rupture of membrane (ROM) type, i.e., spontaneous or artificial, and social services utilization. In addition, QIDS and HAM-A scores from maternal interviews were examined in the prenatal MDD group to evaluate if timing of diagnosis of prenatal MDD during pregnancy was associated with a prolonged second stage of labor. Neonatal outcomes included birthweight, growth percentile, small for gestational age categorization, presence of meconium during birth, jaundice, special care admission, and neonatal intensive care unit (NICU) admission.

Univariate assessments of all variables were examined. Bivariable comparisons between the preconception MDD and prenatal MDD were performed using Wilcoxon rank-sum for continuous variables. The Kruskal-Wallis test was used for comparisons between the three groups. Categorical variables were compared using Fisher's exact test. Simple and multivariable linear regression models were used to examine the association between depression study groups and duration of 2nd stage. Duration of the second stage of labor was log-transformed in order to approximate normal distribution. Statistical analysis was performed using Stata/SE 15.1 (College Station, TX).

The institutional review board at Women and Infants Hospital considered this study exempt since this was a secondary analysis using de-identified data set.

RESULTS

A total of 172 patients were included for analysis. 42 patients were characterized as having preconception only MDD (42/172, 24.4%), 73 patients were categorized as having prenatal MDD, (73/172, 42.4%) and 57 patients 33.1% (57/172, 33.1%) patients were classified as the control group. The demographic data of included patients were significantly different for maternal age, parity, race, insurance type (**Table 1**). The preconception only MDD group included 57.1% (25/41) nulliparas and 80.5% (33/41) utilized epidural anesthesia. The prenatal MDD group included 47.9% (34/69) nulliparas and 76.8% (53/69) utilized epidural anesthesia. Lastly, the control group included 70.2% (40/55) nulliparas and 81.8% (45/55) utilized epidural anesthesia.

The second stage of labor was prolonged in 13.8% (4/29) of the preconception MDD group, in 8.3% (4/48) of the prenatal MDD group, and 10.0% (4/40) of the control group (p = 0.69). The average duration of the second stage of labor was 64.0, 56.6, and 81.7 minutes for the preconception MDD, prenatal MDD, and control groups, respectively (p = 0.08). Maternal outcomes are seen in **Table 2**. 75.6% (31/41) of patients delivered vaginally in the preconception MDD group, 85.9% (61/71) delivered vaginally in the prenatal MDD group, and 81.8% (45/55) delivered vaginally in the control group (p = 0.38). There was a statistically significant difference between the groups with regards to number of CB's due to arrest of descent. Of the patients that delivered via CB in the second stage of labor, arrest of descent was the indication for 10% of the preconception MDD group (1/10), 60% of the prenatal MDD group (6/10), and 70% of the control group (7/10) (p = 0.02). In addition, there was a statistically significant difference in the utility of hospital social services, which was more common in the prenatal MDD group at 68.6% (n=70) in comparison to the preconception

Table 1. Demographic Data of included subjects

	Preconception only major depression disorder (n=42)	Prenatal major depression disorder (n=73)	Control (n=57)	p-value
Maternal age, Mean (SD)	28.0 (4.9)	25.4 (5.4)	25.8 (5.7)	0.02[a]
Gestational age at birth, Mean (SD)	39.8 (1.0)	39.7 (1.0)	39.9 (0.96)	0.64[a]
Pre-pregnancy BMI (kg/m2) Mean (SD)	26.9 (7.1)	26.3 (7.5)	23.9 (3.8)	0.11[a]
Parity, Median (Min-Max)	0 (0-4)	1 (0-6)	0 (0-5)	0.03[a]
Race				0.02[a]
AI/AN	1 (2.4)	0 (—)	1 (1.8)	
Asian	2 (4.8)	2 (2.8)	4 (7.0)	
NH/PI	0 (—)	1 (1.4)	0 (—)	
Black	2 (4.8)	15 (20.8)	10 (17.5)	
White	30 (71.4)	26 (36.1)	28 (49.1)	
Multiracial	3 (7.1)	9 (12.5)	4 (7.0)	
Unknown	4 (9.5)	19 (26.4)	10 (17.5)	
Ethnicity				0.33[a]
Hispanic/Latino	8 (19.1)	27 (38.0)	14 (24.6)	
Portuguese	1 (2.4)	2 (2.8)	3 (5.3)	
Cape Verdean	1 (2.4)	4 (5.6)	1 (1.8)	
Not Hispanic/Latino	30 (71.4)	33 (46.5)	32 (56.1)	
Other	2 (4.8)	4 (5.6)	5 (8.8)	
Unknown	0 (—)	1 (1.4)	2 (3.5)	
Insurance type				<0.001[a]
Public	16 (40.0)	52 (77.6)	29 (52.7)	
Private	24 (60.0)	14 (20.9)	25 (45.5)	
Both public and private	0 (—-)	1 (1.5)	1 (1.8)	
3rd Trimester Depression Symptoms[e]				<0.01[a]
Mean (SD)	4.4 (3.3)	7.2 (4.3)	2.9 (2.5)	
Median (Min-Max)	4 (0–12)	7 (0–19)	3 (0–9)	
IQR (Q1-Q3)	(2–6)	(4–10)	(0–4)	
3rd Trimester Anxiety Symptoms[f]				<0.01[a]
Mean (SD)	8.1 (6.3)	10.1 (4.9)	4.8 (3.5)	
Median (Min-Max)	7 (0–28)	10 (0–23)	4 (0–15)	
IQR (Q1-Q3)	(4–12)	(7–13)	(2–7)	
Antidepressant use	1 (2.4)	7 (9.6)	1 (1.8)	0.13[b]
Epidural	33 (80.5)	53 (76.8)	45 (81.8)	0.81[b]
Induction	12 (29.3)	20 (28.6)	21 (38.2)	0.51[b]
Oxytocin	25 (59.5)	34 (46.6)	35 (61.4)	0.19[b]

Categorical data are N(%)

[a] Kruskal-Wallis

[b] Fisher's exact test

[c] Depression at delivery- QIDS score immediately post partum

[d] Anxiety symptoms at delivery- HAM-A score

[e] 3rd Trimester Depression- QIDS score 3rd trimester

[f] 3rd Trimester Anxiety- HAM-A score 3rd trimester

Note: The total QIDS scoring system ranges from 0 to 27 to quantify the degree of depression; a score of less than 5 indicates no depression, 6 to 10 signifies mild depression, 11 to 15 is moderate depression, 16 to 20 is consistent with severe depression, and a score greater than 20 is concerning for very severe depression. In addition, Hamilton Anxiety Rating Scale (HAM-A) total scores were utilized to quantify the level of anxiety in study patients.[23] This scale uses 14 items that are scaled from 0 to 4 to quantify the level of anxiety; a score less than 17 is characterized as mild anxiety, 18 to 24 is mild/moderate anxiety, and a score greater than 24 represents severe anxiety

Total n for each variable range from 69-73 for prenatal depression, 38-42 for preconception depression and 55-57 for control.

Abbreviations: SD- standard deviation, Min- minimum, Max- maximum, IQR- interquartile range, BMI- body mass index, AI/AN- American Indian / Alaska Native, NH/PI- Native Hawaiian / Pacific Islander

Table 2. Maternal Outcomes by Classification of Maternal Depression

	Preconception only major depression disorder (n=42)	Prenatal major depression disorder (n=73)	Control (n=57)	p-value
Prolonged 2nd stage (>3hrs)	4 (13.8)	4 (8.3)	4 (10.0)	0.69a
Spontaneous vaginal birth	31 (75.6)	61 (85.9)	45 (81.8)	0.38a
Cesarean birth	10 (24.4)	10 (14.1)	10 (18.2)	0.38a
Forceps assisted	0 (—)	2 (3.4)	0 (—)	0.50a
Vacuum assisted	0 (—)	5 (8.5)	2 (4.4)	0.28a
Shoulder dystocia	1 (3.2)	2 (3.4)	0 (—)	0.46a
Indication for CB				
Elective	0 (—)	2 (20.0)	1 (10.0)	0.75a
Nonreassuring fetal status	6 (60.0)	6 (60.0)	6 (60.0)	1.00a
Arrest of descent	1 (10.0)	6 (60.0)	7 (70.0)	0.02a
Total time of 2nd stage (minutes)				
Mean (SD)	64.0 (87.0)	56.6 (71.9)	81.7 (86.7)	0.08a
Median (Min-Max)	23.0 (7.0–349.9)	23.0 (2.0–330.0)	49.0 (9.0–397.0)	
Rupture of membranes type				
Spontaneous	13 (32.5)	28 (40.6)	24 (43.6)	0.93a
Assisted	20 (50.0)	30 (43.5)	25 (45.5)	
Unknown	6 (15.0)	9 (13.0)	5 (9.1)	
C-section	1 (2.5)	2 (2.9)	1 (1.8)	
Hospital social services	15 (36.6)	48 (68.6)	17 (30.9)	<0.001a

Categorical data are N(%)
aFisher's exact test
Total n for each variable ranges from 10–73 for prenatal depression, 10–42 for preconception depression and 10–57 for control.
Abbreviations: CB-Cesarean birth, SD-standard deviation, Min-minimum, Max-maximum

Table 3. Crude and Adjusted Linear Regression Models for Duration of Second Stage of Labor[1]

Depression study group	β coefficient (95% CI)	p-value	Adjusted β (95% CI)2	p-value
Control	Referent	Referent	Referent	Referent
Preconception only major depression disorder	–0.45 (–0.99, 0.08)	0.09	–0.44 (–0.98, 0.11)	0.11
Prenatal major depression disorder	0.53 (–1.01, –0.06)	0.03	–0.26 (–0.75, 0.22)	0.28

[1] Duration of 2nd stage log-transformed to approximate normal distribution
[2] Adjusted for age, race, gravidity, parity and insurance type

MDD (36.6% (15/41)) and control groups (30.9% (17/55)) ($p < 0.001$).

Pair-wise analysis between groups (preconception-only MDD versus control, prenatal MDD versus control and preconception-only MDD versus prenatal MDD) showed no significant difference in the duration of the second stage of labor between any of the groups after adjustment for confounders.

When linear regression was utilized to compare the three groups to the log-transformed duration of the second stage of labor, the preconception-only MDD group was noted to have a shorter duration of the second stage of labor compared to the control group; however, after adjusting for confounders, no statistically significant difference was noted (**Table 3**).

When we evaluated the data to determine if timing of depression or anxiety (3rd trimester versus during the delivery hospitalization) impacted the length of second stage, there was no difference in length of second stage of labor (**Table 5**).

Neonatal outcomes are shown in **Table 4**. No statistically significant differences were noted between the groups. The mean birth weight was 3458 grams in the preconception MDD group, 3356 grams in the prenatal MDD group, and 3420 grams in the control group ($p = 0.47$). NICU admission 4.9% (2/41) in the preconception MDD group, was 2.9% (2/70) in the prenatal MDD group, and 12.7% (7/55) in the control group, ($p = 0.09$).

The QIDS and HAM-A scores did not differ in women with MDD between the third trimester and postpartum period for women with prolonged second stage of labor or normal second stage of labor. The QIDS and HAM-A scores were similar for women with MDD regardless of length of the second stage of labor (**Table 5**).

Table 4. Neonatal Outcomes by Classification of Maternal Depression

	Preconception only major depression disorder (n=42)	Prenatal major depression disorder (n=73)	Control (n=57)	p-value
Birthweight (grams) Mean (SD)	3458 (415)	3356 (463)	3420 (409)	0.47[a]
Growth percentile Mean (SD)	49 (25.9)	44.1 (27.1)	45.8 (24.3)	0.62[a]
SGA (<10%)	1 (2.5)	1 (1.6)	2 (3.6)	0.15[b]
Oxygen	5 (12.2)	7 (10.1)	8 (14.6)	0.76[b]
Intubation	2 (4.9)	3 (4.4)	2 (3.6)	1.00[b]
Delee suction	6 (14.6)	6 (8.7)	3 (5.5)	0.31[b]
Chest physiotherapy	1 (2.4)	1 (1.5)	1 (1.8)	1.00[b]
Meconium during birth	6 (14.6)	19 (27.5)	13 (23.6)	0.29[b]
Special care admission	1 (2.4)	1 (1.4)	1 (1.8)	1.00[b]
NICU admission	2 (4.9)	2 (2.9)	7 (12.7)	0.09[b]
NICU length of stay (hours) Mean (SD)	(n=2) 85.3 (117.0)	(n=2) 19.0 (24.0)	(n=7) 108.7 (66.0)	0.13[a]
Jaundice	35 (85.4)	55 (79.7)	46 (83.6)	0.76[b]

Categorical data are N (%)

[a] Kruskal-Wallis

[b] Fisher's exact test

Total n for each variable were 55 for prenatal depression, 69-70 for preconception depression and 40-41 for control unless otherwise noted.

Abbreviations: SD-standard deviation, Min-minimum, Max-maximum, IQR-interquartile range, SGA-small for gestational age, NICU-Neonatal intensive care unit

Table 5. Prolonged Second Stage of Labor based on Timing of Maternal Depression during Pregnancy

	No prolonged 2nd stage (n=107)	Prolonged 2nd stage (n=13)	p-value[a]
Depression at delivery[b] Mean (SD) Median (Min-Max) IQR (Q1-Q3)	 4.6 (3.5) 4 (0–14) (2–6)	 3.9 (2.8) 4 (0–8) (1–6)	0.75
Anxiety symptoms at delivery[c] Mean (SD) Median (Min-Max) IQR (Q1-Q3)	 5.9 (4.6) 5 (0–21) (3–9)	 5.4 (2.2) 5 (2–9) (3–7)	0.93
3rd Trimester Depression[d] Mean (SD) Median (Min-Max) IQR (Q1-Q3)	 5.2 (4.1) 4 (0–19) (2–7)	 3.9 (2.9) 4 (0–9) (2–6)	0.39
3rd Trimester Anxiety[e] Mean (SD) Median (Min–Max) IQR (Q1–Q3)	 7.9 (5.4) 7 (0–28) (4–10)	 6.7 (4.4) 7 (1–15) (2–10)	0.66

[a]Wilcoxon rank-sum

Total n for each variable range from 10-73 for prenatal depression, 10-42 for preconception depression and 10-57 for control.

[b] Depression at delivery- QIDS score immediately post partum

[c] Anxiety symptoms at delivery- HAM-A score

[d] 3rd Trimester Depression- QIDS score 3rd trimester

[e] 3rd Trimester Anxiety- HAM-A score 3rd trimester

Note: The total QIDS scoring system ranges from 0 to 27 to quantify the degree of depression; a score of less than 5 indicates no depression, 6 to 10 signifies mild depression, 11 to 15 is moderate depression, 16 to 20 is consistent with severe depression, and a score greater than 20 is concerning for very severe depression. In addition, Hamilton Anxiety Rating Scale (HAM-A) total scores were utilized to quantify the level of anxiety in study patients.[23] This scale uses 14 items that are scaled from 0 to 4 to quantify the level of anxiety; a score less than 17 is characterized as mild anxiety, 18 to 24 is mild/moderate anxiety, and a score greater than 24 represents severe anxiety

Total n for each variable range from 69-73 for prenatal depression, 38-42 for preconception depression and 55-57 for control.

Abbreviations: SD- standard deviation, Min- minimum, Max- maximum, IQR- interquartile range

DISCUSSION

Principal Findings

This study showed no association between maternal preconception MDD or maternal prenatal MDD and the duration of the second stage of labor. There was an increase in CB performed for arrest of descent in the prenatal MDD and control groups compared to the preconception only MDD group, as well as an increase in hospital social services utilization in the prenatal MDD group. There were no statistically significant differences in neonatal outcomes. In addition, analysis of continuous depression and anxiety levels showed that there was no association between depression and anxiety severity during 3rd trimester or at delivery and the presence of a prolonged second stage of labor. The results of this study suggest that the fifth "P" for maternal psyche – at least in terms of depression – may not be connected with clinically measurable outcomes in relation to the second stage of labor.

Results

There are limited studies in the literature which examine an association between maternal preconception or maternal prenatal MDD and the length of the second stage of labor. While one prior study showed that women with depression have more dysregulated patterns of oxytocin release when assigned with tasks that stimulate oxytocin release, thus one could infer a potential effect of depression on oxytocin release during labor, this study was not performed in a labor setting.[12] Oxytocin regulation is also likely more important in the first stage of labor compared with the second stage.

Several studies by Lederman et al. show a correlation between maternal anxiety and catecholamine levels, leading to an association with a longer duration of the first stage of labor. These studies examined patient anxiety through subjective reports as well as from objective observations by medical/nursing staff, which may have decreased external validity. In addition, these studies exclusively analyzed the first stage of labor.[9,10]

Clinical implications

Although there was no significant difference in the second stage of labor duration between the groups, there were more CB's performed due to arrest of descent in the control group (70%, 7/10) and the prenatal MDD group (60%, 6/10), compared to the preconception-only MDD group (10%, 1/10) ($p = 0.02$). This finding is likely related to the small number of patients included in this study. Post-hoc analyses are limited to the dataset that is used, and so it is unclear if other factors may have played a role in these second stage CB's, especially since non-reassuring fetal status also played a role in the control group (60%, 6/10), the prenatal MDD group (60%, 6/10), and the preconception MDD group (60%, 6/10). There could certainly be overlap in indications for mode of delivery, with some patients having multiple indications for CB. In addition, it is unclear whether other interventions were considered, such as manual rotation, operative vaginal birth, or allowing more time in the second stage. Neonatal outcomes were similar in all three groups, which is consistent with a previous study that demonstrated no adverse neonatal outcomes in pregnancies with a prolonged second stage of labor.[23] QIDS scores and HAM-A were similar between women with prolonged second stage and women with a normal second stage, however the small sample size of the prolonged second stage group could have influenced these results and so further studies to examine these relationships are needed.

The protocol of the BAMBI study specifically differentiated between preconception and prenatal MDD in order to elucidate the connection of prenatal and preconception MDD on programming of fetal hypothalamic-pituitary-adrenal (HPA) axis regulation.[18] This is important because patients with preconception MDD could have confounders such as hormonal alterations from previous lifetime episodes of depression or a possible genetic predisposition to depression. Therefore, the BAMBI study was able to specifically examine the impact of prenatal MDD. The results demonstrated that in some patients, prenatal MDD showed more significant fetal glucocorticoid regulation than in preconception MDD or controls. This design allowed our secondary analysis to specifically differentiate between the effects of preconception-only and prenatal MDD on the duration of the second stage of labor.

Research implications

This information is important and may play a role in labor management of patients with MDD. The BAMBI study showed that women with prenatal MDD, in comparison to women with preconception MDD had an increased impact on fetal HPA axis, which could alter long term health and behavioral outcomes in these infants.[18] Given the prevalence of maternal depression and the impact that it has on other pregnancy outcomes, future studies are required to further elucidate the impact of preconception and prenatal MDD on other aspects of labor. Additionally, studies are needed to explore the need for oxytocin dose and duration as well. Furthermore, given that this was performed in a small population of mixed parity and mixed use of labor analgesia, it will be important to confirm in a larger study focusing on nulliparous patients, where an established threshold for prolonged second stage can be utilized.

Strengths and limitations

The major strength of our study is the design of the original protocol which included the utility of specific DSM criteria, depression and anxiety severity scores, therefore incorporating standardized assessments that provided validated and objective data. Since our study is one of the first in the literature to examine thelink between preconception and prenatal MDD on the duration of the second stage of labor,

the utilization of these standardized assessments improves the replicability of this study and may establish preliminary data for future studies to further examine the connection between maternal depression and labor.

Limitations to this study include that the baseline characteristics differed between the groups such as age, parity, insurance type and history of panic disorder or post-traumatic stress disorder. While these variables were adjusted for in multivariable analysis, omitted-variable bias may still exist. In addition, prolonged second stage was defined as duration of greater than 3 hours due to the small number of patients in the sample size and due to the fact that data collected for the original BAMBI study was prior to 2014 and before new guidelines were implemented. Therefore, our results did not account for the possible confounding effects of parity and epidural anesthesia, which may have been significant.[24] Another limitation with this data set, as with all post-hoc analyses on labor, is the difficulty in accurately measuring the duration of the second stage of labor, since the second stage is not documented until a vaginal exam shows complete dilation, and the true second stage of labor duration is frequently underestimated. Lastly, the authors acknowledge the limitation regarding granularity of oxytocin use and dose during participants labor course as well as the moderate sample size.

CONCLUSIONS

There was no association noted between preconception or prenatal MDD during pregnancy and prolonged duration of the second stage of labor in this cohort. Further research is needed to determine if maternal depression impacts other aspects of labor.

References

1. Gill P, Henning JM, Van Hook MJ. Abnormal Labor. StatPearls. Treasure Island (FL)2020.
2. Piper JM, Bolling DR, Newton ER. The second stage of labor: factors influencing duration. Am J Obstet Gynecol. 1991;165(4 Pt 1):976-979.
3. Schiessl B, Janni W, Jundt K, Rammel G, Peschers U, Kainer F. Obstetrical parameters influencing the duration of the second stage of labor. Eur J Obstet Gynecol Reprod Biol. 2005;118(1):17-20.
4. Bennett HA, Einarson A, Taddio A, Koren G, Einarson TR. Prevalence of depression during pregnancy: systematic review. Obstet Gynecol. 2004;103(4):698-709.
5. Alder J, Fink N, Bitzer J, Hosli I, Holzgreve W. Depression and anxiety during pregnancy: a risk factor for obstetric, fetal and neonatal outcome? A critical review of the literature. J Matern Fetal Neonatal Med. 2007;20(3):189-209.
6. Mochache K, Mathai M, Gachuno O, Vander Stoep A, Kumar M. Depression during pregnancy and preterm delivery: a prospective cohort study among women attending antenatal clinic at Pumwani Maternity Hospital. Ann Gen Psychiatry. 2018;17:31.
7. Grote NK, Bridge JA, Gavin AR, Melville JL, Iyengar S, Katon WJ. A meta-analysis of depression during pregnancy and the risk of preterm birth, low birth weight, and intrauterine growth restriction. Arch Gen Psychiatry. 2010;67(10):1012-1024.
8. Grigoriadis S, VonderPorten EH, Mamisashvili L, et al. The impact of maternal depression during pregnancy on perinatal outcomes: a systematic review and meta-analysis. J Clin Psychiatry. 2013;74(4):e321-341.
9. Lederman RP, Lederman E, Work B, Jr., McCann DS. Anxiety and epinephrine in multiparous women in labor: relationship to duration of labor and fetal heart rate pattern. Am J Obstet Gynecol. 1985;153(8):870-877.
10. Lederman RP, Lederman E, Work BA, Jr., McCann DS. The relationship of maternal anxiety, plasma catecholamines, and plasma cortisol to progress in labor. Am J Obstet Gynecol. 1978;132(5):495-500.
11. Hishikawa K, Kusaka T, Fukuda T, Kohata Y, Inoue H. Anxiety or Nervousness Disturbs the Progress of Birth Based on Human Behavioral Evolutionary Biology. J Perinat Educ. 2019;28(4): 218-223.
12. Cyranowski JM, Hofkens TL, Frank E, Seltman H, Cai HM, Amico JA. Evidence of dysregulated peripheral oxytocin release among depressed women. Psychosom Med. 2008;70(9):967-975.
13. Gimovsky AC, Berghella V. Randomized controlled trial of prolonged second stage: extending the time limit vs usual guidelines. Am J Obstet Gynecol. 2016;214(3):361.e361-366.
14. Gimovsky AC, Guarente J, Berghella V. Prolonged second stage in nulliparous with epidurals: a systematic review. J Matern Fetal Neonatal Med. 2017;30(4):461-465.
15. Sandstrom A, Altman M, Cnattingius S, Johansson S, Ahlberg M, Stephansson O. Durations of second stage of labor and pushing, and adverse neonatal outcomes: a population-based cohort study. J Perinatol. 2017;37(3):236-242.
16. Laughon SK, Berghella V, Reddy UM, Sundaram R, Lu Z, Hoffman MK. Neonatal and maternal outcomes with prolonged second stage of labor. Obstet Gynecol. 2014;124(1):57-67.
17. Cheng YW, Hopkins LM, Caughey AB. How long is too long: Does a prolonged second stage of labor in nulliparous women affect maternal and neonatal outcomes? Am J Obstet Gynecol. 2004;191(3):933-938.
18. Stroud LR, Papandonatos GD, Parade SH, et al. Prenatal Major Depressive Disorder, Placenta Glucocorticoid and Serotonergic Signaling, and Infant Cortisol Response. Psychosom Med. 2016;78(9):979-990.
19. First MB. Structured clinical interview for DSM-IV axis I disorders. Biometrics Research Department. 1997.
20. Rush AJ, Gullion CM, Basco MR, Jarrett RB, Trivedi MH. The Inventory of Depressive Symptomatology (IDS): psychometric properties. Psychol Med. 1996;26(3):477-486.
21. Hamilton M. The assessment of anxiety states by rating. Br J Med Psychol. 1959;32(1):50-55.
22. Caughey AB, Cahill AG, Guise JM, Rouse DJ. Safe prevention of the primary cesarean delivery. Am J Obstet Gynecol. 2014;210(3):179-193.
23. Altman MR, Lydon-Rochelle MT. Prolonged second stage of labor and risk of adverse maternal and perinatal outcomes: a systematic review. Birth. 2006;33(4):315-322.
24. Spong CY, Berghella V, Wenstrom KD, Mercer BM, Saade GR. Preventing the first cesarean delivery: summary of a joint Eunice Kennedy Shriver National Institute of Child Health and Human Development, Society for Maternal-Fetal Medicine, and American College of Obstetricians and Gynecologists Workshop. Obstet Gynecol. 2012;120(5):1181-1193.

Authors

Alexis C. Gimovsky, MD, Division of Maternal Fetal Medicine, Department of Obstetrics and Gynecology, Alpert Medical School of Brown University, Providence, RI.

Stephen S. Rasiah, MD, Division of Maternal Fetal Medicine, Department of Obstetrics and Gynecology, Alpert Medical School of Brown University, Providence, RI.

Chrystal Vergara-Lopez, PhD, Center for Behavioral and Preventive Medicine, The Miriam Hospital; Department of Psychiatry and Human Behavior, Warren Alpert Medical School, Brown University, Providence, RI.

Phinnara Has, MS, Lifespan Biostatistics, Epidemiology and Research Design, Rhode Island Hospital, Alpert Medical School of Brown University, Providence, RI.

Nina K. Ayala, MD, Division of Maternal Fetal Medicine, Department of Obstetrics and Gynecology, Alpert Medical School of Brown University, Providence, RI.

Laura R. Stroud, PhD, Center for Behavioral and Preventive Medicine, The Miriam Hospital; Department of Psychiatry and Human Behavior, Warren Alpert Medical School, Brown University, Providence, RI.

Acknowledgment

Funding**:** This research was partially supported by R01MH079153 and R01DA044504 to LRS. This research was partially supported by the National Institute of General Medical Sciences P20GM139767 to LRS with a research project to CVL.

Disclaimer

The views expressed herein are those of the authors.

Disclosures

Competing interests: The authors report no relevant financial or non-financial interests to disclose.

Correspondence

Alexis Gimovsky, MD
Women & Infants Hospital of Rhode Island
101 Plain St. 7th Floor
Providence, RI, 02905
P 401-274-1122
Fax 401-453-7622
agimovsky@wihri.org

Potentially Preventable Emergency Department Utilization, Rhode Island, 2022

GAYATRI KUNCHAY, MPH; JUNHIE OH, MPH

INTRODUCTION

Emergency department (ED) visits for certain conditions are potentially avoidable and better managed in outpatient physicians' offices, clinics, or urgent care facilities.[1] "Preventable" ED visits impose considerable pressure on the healthcare system, contributing to higher ED costs and overcrowding.[2] A previous study in 2010 estimated that 13–27% of ED visits in the US could be preventable.[3]

For specific and uniform measurements of preventable ED utilizations across the nation, the Agency for Healthcare Research and Quality (AHRQ), in the U.S. Department of Health & Human Services, developed Prevention Quality Indicators (PQIs), that identifies conditions for which access to quality ambulatory care can reduce the likelihood of hospital care.[4] This can be employed to identify regions or demographic groups where reinforcing ambulatory care systems could potentially prevent unnecessary and costly emergency care.[4]

The objectives of this report are to: (a) document the extent of preventable ED visits in Rhode Island (RI); (b) assess the preventable ED visits by patient demographics and ED admission day and time; and (c) discuss opportunities and future initiatives to reduce these potentially preventable ED visits.

METHODOLOGY

The data used for this analysis were obtained from the RI Hospital Discharge Data (HDD).[5] All hospitals licensed by the Rhode Island Department of Health (RIDOH) are required to report financial and discharge data on a quarterly basis, using a statewide uniform reporting system. Data on inpatient admissions and ED encounters are currently submitted by 13 RI non-federal acute-care and specialty hospitals. Of these 13, 11 hospitals operate EDs from which ED data between January 1, 2022, and December 31, 2022, were extracted for this study.

AHRQ's PQIs were used to define and measure the preventable ED visits that consist of five indicators: (1) visits for Non-Traumatic Dental Conditions (NTDC), (2) visits for Chronic Ambulatory Care Sensitive Conditions (ACSC), (3) visits for Acute ACSC, (4) visits for Asthma, and (5) visits for Back Pain (**Table 1**). AHRQ ED PQI Beta v2023 software was downloaded from: SAS QI Software (ahrq.gov) and modified to create the analytic dataset that included discharges from EDs but not admitted for inpatient stays (i.e., treat-and-release visits). The fifth indicator (back pain-related) was not included in this report, as explained in Table 1. SAS® v9.4 was used for descriptive statistics of the preventable ED visits (PQI 1–PQI 4), and by patient's sex, age group, race/ethnicity, and primary expected payer. Additionally, the patients' ED admission day (in a week) and time (in a day) were assessed if the visits were within or outside of the usual physician's office days and hours.

RESULTS

Figure 1 presents the ED PQIs in 2022. Of a total of 312,798 ED visits in 11 study hospitals, 21,383 (6.4%) visits were potentially preventable visits. The majority of these visits were attributed to Acute ACSC, followed by Chronic ACSC, NTDC, and Asthma. Evaluating specific diagnoses (**Table 2**), upper respiratory infection was the most common diagnosis, representing almost half of the visits for Acute ACSC (49.6%), and nearly a third of all preventable ED visits (29.6%). Cellulitis was the second most frequent condition.

Patient characteristics were distinct by ED PQI indicator (**Table 3**). For Acute ACSC, NTDC, and Asthma ED PQIs, patients were more likely to be young adults (aged 20-39 years) compared to those in other age groups. Meanwhile, among adults analyzed for Chronic ACSC, non-elderly individuals aged 40-64 years had more frequent ED visits than elderly adults aged 65 and older (53.2% *vs.* 46.8%). For NTDC and Asthma, males and females exhibited nearly equal likelihood of visiting ED; for Acute and Chronic ACSCs, females were more likely to seek ED care compared to males. Patients who reported their racial and ethnic background as non-Hispanic White had higher numbers of ED visits for all PQIs, than racial/ethnic minorities (the White population is the largest in the state). However, Hispanic children and younger adults' ED visits for asthma were as common as the counterpart non-Hispanic White populations (37.3% and 38.7%, respectively). Finally, patients with Medicaid showed a higher likelihood of having ED PQI visits across all conditions than those with other sources of primary payment, except for Chronic ACSC.

Figure 2 summarizes the preventable ED visits by admission day and time. Between 30% and 42% of the ED visits

Table 1. Emergency Department Prevention Quality Indicators (ED PQIs) Defined by Agency for Healthcare Research and Quality (AHRQ)

ED PQI*	Patient population by age (at ED admission)	Description§
ED Visits for NTDC	Children & Adults (ages ≥5 years)	Principal diagnosis of caries, gum disease, oral soft tissue conditions, caries, gum disease, oral soft tissue conditions, or dental conditions NOS; Included is tooth pain; Excluded is facial trauma.
ED Visits for Chronic ACSC	Adults (ages ≥40 years)	Principal diagnosis of asthma, chronic obstructive pulmonary disease (COPD), heart failure, acute diabetic hyper- and hypoglycemic complications, or chronic kidney disease; Principal diagnosis of lower respiratory infection with a second-listed diagnosis of COPD or asthma.
ED Visits for Acute ACSC	Children & Non-elderly adults (ages ≥3 months and <65 years)	Principal diagnosis of uncomplicated cystitis (among women ages 18 to 34 years), upper respiratory infection, chronic and acute otitis media, allergic rhinitis, viral syndrome, influenza without pneumonia, cellulitis (with no secondary diagnosis of diabetes), pyoderma, or local skin infection.
ED Visits for Asthma	Children & Young adults (ages ≥5 years and <40 years)	Principal diagnosis of asthma (with/without exacerbation or status asthmaticus), or bronchitis (with a secondary diagnosis of asthma); Excluded are cystic fibrosis, respiratory anomalies, or pneumonia.
ED Visits for Back Pain‡	Adults (ages ≥18 years)	Patients who visited ED >2 times within a year with principal diagnosis of back pain or back disorders, including spinal stenosis, back pain, lumbago, sciatica, neuritis or radiculitis, disorders of the sacrum, spondylosis, intervertebral disc disorders, and spinal degeneration.

* ED encounters in 11 RI hospitals that did not result in an admission to the same hospital. The measures exclude more severe cases, for which delay in seeking care to avoid the ED may harm the patient.

‡ Not included in this report: Unlike other indicators, visits for back pain require person-level data to identity patients with two or more back pain visits in a year. A single back pain encounter, which may involve severe pain or immobilization may require treatment in the ED, but subsequent visits may be avoided by correct initial diagnosis or high-quality ambulatory care.

§ Detailed information with lists of ICD-10-CM codes for each ED PQIs are available at: AHRQ QI: PQI Technical Specifications Updates

Figure 1. Preventable ED visits by ED PQI, RI HDD 2022 (Total=21,383 Visits)

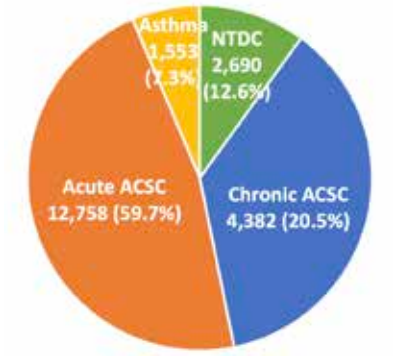

Table 2. The Most Common Diagnoses Associated with Preventable ED Visits, RI HDD 2022 (Total=21,383 Visits)

	Diagnoses (ED PQI)*	ED Visits Count (%)
1	Upper Respiratory Infection (ED PQI-Acute ACSC)	6,329 (29.6.)
2	Cellulitis (ED PQI-Acute ACSC)	3,012 (14.1)
3	NTDC	2,690 (12.6)
4	Influenza (ED PQI-Acute ACSC)	2,599 (12.2)
5	Asthma (ED PQI-Asthma)	1,553 (7.3%)

* Detailed information with lists of ICD-10-CM codes for each ED PQIs are available at: AHRQ QI: PQI Technical Specifications Updates.

Table 3. Patient Characteristics by ED PQI, RI HDD 2022

Patient Characteristic*	ED PQI			
	Acute ACSC Count (%)	Chronic ACSC Count (%)	NTDC Count (%)	Asthma Count (%)
Age Group (Years)				
0–4	1,926 (15.1)	*	*	*
5–10	1,616 (12.7)	*	85 (3.2)	507 (32.7)
11–19	1,638 (12.8)	*	120 (4.5)	280 (18.3)
20–39	4,739 (37.2)	*	1,436 (53.4)	766 (49.3)
40–64	2,839 (22.3)	2,331 (53.2)	891 (33.1)	*
≥65	*	2,051 (46.8)	158 (5.9)	*
Sex				
Male	5,670 (44.4)	2,005 (45.7)	1,394 (51.8)	745 (48.0)
Female	7,088 (55.5)	2,377 (54.2)	1,296 (48.2)	808 (52.0)
Race/Ethnicity				
Non-Hispanic Black	1,541 (12.1)	969 (9.7)	445 (16.5)	252 (16.2)
Hispanic	4,267 (33.5)	1,193 (11.9)	561 (20.9)	579 (37.3)
Non-Hispanic White	5,916 (46.4)	7,400 (73.8)	1,518 (56.4)	601 (38.7)
Non-Hispanic Other	801 (6.3)	345 (3.4)	139 (5.2)	100 (6.4)
Expected Payer†				
Commercial	3,532 (27.7)	615 (14.0)	486 (18.1)	396 (25.5)
Medicaid	7,554 (59.2)	1,046 (23.9)	1,618 (60.2)	1,035 (66.6)
Medicare	591 (4.6)	2,435 (55.6)	334 (12.4)	29 (1.9)
Self-Pay	760 (6.0)	168 (3.8)	204 (7.6)	68 (4.4)
Other	321 (2.5)	118 (3.0)	48 (1.8)	25 (1.7)

*Each ED PQI is based on different priority population by patient's age.

† Expected primary source of payment identified in hospital's initial admission records

Figure 2. Preventable ED visits by ED Admission Day and Time, RI HDD 2022

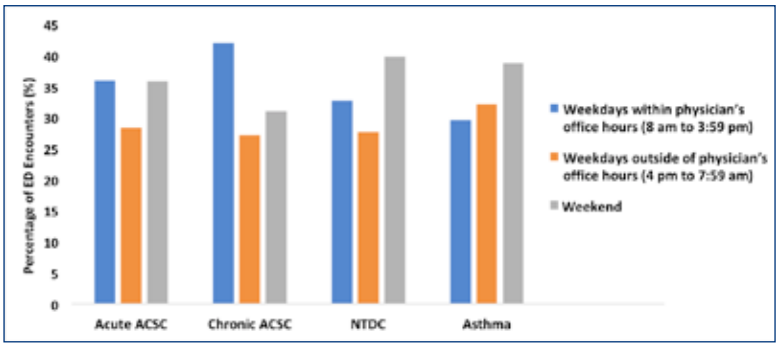

were observed during the usual physician's office hours in weekdays (29.6% for Asthma; 32.7% for NTDC; 38.9% for Acute ACSC; 41.9% for Chronic ACSC). Greater proportions of the visits for all ED PQIs were made outside of these hours, combining admissions during weekend and in the evening through overnight hours during weekdays.

DISCUSSION

Our study using the AHRQ's proven method to identify and measure ED PQIs provides critical insights into healthcare utilization across diverse demographic groups in RI. A substantial number of yearly encounters – more than 21,000 – were potentially preventable through timely, accessible, and quality outpatient care in 2022. Furthermore, the fact that ED visits for Acute ACSC, NTDC, and asthma made up nearly 80% of the preventable ED visits during the study year supports a need to address over-reliance on emergency services for acute illnesses, NTDCs, and asthma (particularly among children and young adults).[6,7,8] Additionally, over 20% of the preventable ED visits were among both non-elderly and elderly individuals for Chronic ACSC. This finding emphasizes the public and private health programs' efforts for better management of common chronic diseases, such as diabetes, hypertension, cardiovascular diseases, COPD, and some respiratory diseases. Notably, our findings reveal that ED visits for asthma among Hispanic children and younger adults were as common as their non-Hispanic White counterparts, which can be interpreted as a disproportionately higher rate, given the 17% representation of the Hispanic population in RI. To address these health disparities effectively, culturally competent outreach, community engagement, and initiatives aimed at improving healthcare access become imperative, promoting equitable health outcomes.[9]

Our study also reports that patients with Medicaid insurance were more likely to have ED PQI visits across various conditions. This aligns with existing literature that Medicaid, uninsured, and residents from low-income families were frequent ED users, indicative of limited access to primary and routine care.[10] This finding prompts a closer examination of the factors contributing to increased ED visits among individuals with limited healthcare coverage, necessitating policy considerations for enhanced preventive care.

Patient's seeking care in ED for ACSC during the usual physician's office hours suggests an unmet need during the timeframe when outpatient physician's offices, clinics, or urgent care facilities are available. Potential explanations for this may include challenges in finding and scheduling with a provider for same-day or next-day appointment. Conversely, ED visits during weekend and in the evening through overnight hours during weekdays for Acute and Chronic ACSC, asthma and NTDC may be indicative of acute exacerbations or worsening symptoms that prompt individuals to seek emergency care during these days and time. Initiatives focused on improving healthcare accessibility during off-office hours, including weekends, may contribute to reducing preventable ED visits, particularly for patients who cannot seek routine care during the weekdays due to work schedule, transportation or other systemic barriers. This could involve the expansion of urgent care services, increased availability of outpatient care during evenings, and promoting community health clinics.[11]

STRENGTHS AND LIMITATIONS

A strength of this study is use of the RI HDD, a statewide public health surveillance system. Utilizing complete discharge reports from 11 hospitals that operate EDs in RI, assessments of preventable ED utilizations among RI residents were possible. The database provides comprehensive information about patient demographics and clinical details such as principal and secondary diagnoses that explain main reasons for hospital admissions.

In comparison to existing literature, the percentage of potentially preventable ED visits in our report appears to be relatively lower. This discrepancy might be attributed to variations in software algorithms employed for the analysis of preventable ED visits in different studies and study periods. It is important to note that our analysis excluded the PQI related to "ED visits for back pain", which might have contributed to the observed lower numbers. Additionally, RI HDD does not capture information on a patient's access to primary and routine healthcare or historical utilization of outpatient services. Therefore, we were unable to further examine if treatments at EDs were directly or indirectly associated with a patient's primary care visits for ACSC. Moreover, the potentially preventable ED visits flagged as PQIs do not mean these are definitively best treatable in ambulatory care settings. Some genuinely necessitate emergency care. Medical practices may refer patients to the ED for comprehensive evaluation beyond office capacity or after an initial assessment.

References

1. Yang Y, Yu J, Liu S, et al. Predicting Avoidable Emergency Department Visits Using the NHAMCS Dataset. AMIA Jt Summits Transl Sci Proc. 2022 May 23;514-523. PMID: 35854758.
2. Carlson LC, Zachrison KS, Yun BJ, et al. The Association of Demographic, Socioeconomic, and Geographic Factors with Potentially Preventable Emergency Department Utilization. West J Emerg Med. 2021 Oct 27;22(6):1283-1290. PMID: 34787552.
3. Weinick RM, Burns RM, Mehrotra A. Many Emergency Department Visits Could Be Managed at Urgent Care Centers and Retail Clinics. Health Aff. 2010 Sep;29(9):1630-1636. PMID: 20820018.
4. Davies S, Schultz E, Raven M, et al. Development and Validation of the Agency for Healthcare Research and Quality Measures of Potentially Preventable Emergency Department (ED) Visits: The ED Prevention Quality Indicators for General Health Conditions. Health Serv Res. 2017 Oct;52(5):1667-1684. PMID: 28369814.
5. Department of Health. Hospitalization Discharge Data, 2023. [https://health.ri.gov/data/hospitalization/discharge/]
6. Van den Heede K, Van de Voorde C. Interventions to Reduce Emergency Department Utilisation: A Review of Reviews. Health Policy. 2016 Dec;120(12):1337-1349. PMID: 27855964.
7. Akinlotan MA, Ferdinand AO. Emergency Department Visits for Nontraumatic Dental Conditions: A Systematic Literature Review. J Public Health Dent. 2020 Sep;80(4):313-326. PMID: 33006151.
8. Johnson LH, Chambers P, Dexheimer JW. Asthma-related Emergency Department Use: Current Perspectives. Open Access Emerg Med. 2016 Jul;13(8):47-55. PMID: 27471415.
9. Kim K, Choi JS, Choi E, et al. Effects of Community-Based Health Worker Interventions to Improve Chronic Disease Management and Care Among Vulnerable Populations: A Systematic Review. Am J Public Health. 2016 Apr;106(4):23-28. PMID: 26890177.
10. Williams CA, Haffizulla F. Factors Associated with Avoidable Emergency Department Visits in Broward County, Florida. Cureus. 2021 Jun 11;13(6). PMID: 34277214.
11. Appropriate ED Utilization Leading to Better Care Coordination, 2022. [https://www.ajmc.com/view/appropriate-ed-utilization-leading-to-better-care-coordination]

Authors

Gayatri Kunchay, MPH, Hospital Discharge Data Program Epidemiologist, Center for Health Data and Analysis (CHDA), Rhode Island Department of Health.

Junhie Oh, MPH, Hospital Discharge Data Program Manager, Senior Epidemiologist, Center for Health Data and Analysis (CHDA), Rhode Island Department of Health.

Correspondence

Gayatri Kunchay, MPH
Gayatri.Kunchay@health.ri.gov

Rhode Island Monthly Vital Statistics Report
Provisional Occurrence Data from the Division of Vital Records

VITAL EVENTS	REPORTING PERIOD		
	MAY 2023	12 MONTHS ENDING WITH MAY 2023	
	Number	Number	Rates
Live Births	917	10,998	10.4*
Deaths	869	10,938	10.3*
Infant Deaths	4	50	4.5#
Neonatal Deaths	2	35	3.2#
Marriages	509	6,858	6.5*
Divorces	241	2,735	2.6*

* Rates per 1,000 estimated population
# Rates per 1,000 live births

Underlying Cause of Death Category	REPORTING PERIOD			
	NOVEMBER 2022	12 MONTHS ENDING WITH NOVEMBER 2022		
	Number (a)	Number (a)	Rates (b)	YPLL (c)
Diseases of the Heart	195	2,412	219.8	3,269.5
Malignant Neoplasms	200	2,197	200.2	4,312.0
Cerebrovascular Disease	37	501	45.7	642.0
Injuries (Accident/Suicide/Homicide)	88	1,065	97.0	14,288.0
COPD	37	431	39.3	340.0

(a) Cause of death statistics were derived from the underlying cause of death reported by physicians on death certificates.
(b) Rates per 100,000 estimated population of 1,097,379 for 2020 (www.census.gov)
(c) Years of Potential Life Lost (YPLL).

NOTE: Totals represent vital events, which occurred in Rhode Island for the reporting periods listed above.
Monthly provisional totals should be analyzed with caution because the numbers may be small and subject to seasonal variation.

RIMS gratefully acknowledges the practices who participate in our discounted Group Membership Program

ANCHOR MEDICAL ASSOCIATES

BROWN EMERGENCY MEDICINE
BROWN PHYSICIANS, INC.

BROWN MEDICINE
BROWN PHYSICIANS, INC.

BROWN SURGICAL ASSOCIATES
BROWN PHYSICIANS, INC.

COASTAL MEDICAL

Diabetes & Endocrinology Associates, Inc.

east bay community action program
THE BRIDGE to SELF-RELIANCE

Orthopaedic Associates, Inc.

Ortho Rhode Island

SKIN PROS

The Providence CENTER

Thundermist HEALTH CENTER

Tri-County Community Action Agency
Helping people. Changing lives.

UNIVOTO
University Otolaryngology

Wood River Health Services
The Heart of South County since 1976

For more information about group rates, please contact Ali Walz, RIMS Director of Member Services

Project ECHO in Rhode Island

DARIA SZKWARKO, DO, MPH; LINDA CABRAL, MM; GAIL PATRY, RN

Regional LTBI ECHO Coordinator **Julia Teck, MD**, Global Health Faculty Development Fellow is shown with **Daria Szkwarko, DO, MPH**, Director of the Global Health Fellowship program in Family Medicine at Brown University at the 2023 MetaECHO conference held in New Mexico. [COURTESY OF DR. SZKWARKO]

BACKGROUND

Project ECHO (Extension for Community Healthcare Outcomes) is an innovative, evidence-based telementoring model designed to build healthcare workers' capacity to address complex health conditions. The ECHO model uses a virtual "hub-and-spoke" framework to link experts with participants in order to enhance knowledge and skills, and ultimately improve patient outcomes. Developed in 2003 in New Mexico to help clinicians manage hepatitis C, the model has rapidly expanded globally to address other diseases and patient needs such as chronic pain, HIV, cervical cancer, substance use disorders, and palliative care.

As part of the ECHO model, ECHO courses are free and participants can receive continuing medical education credits. ECHO courses can be longitudinal or consist of a set number of sessions. Each session is 1–1.5 hours in duration consisting of a short (15–20 minute) lecture and a case presentation by a participant with a facilitated discussion (40–45 minutes).

In recent years, three ECHO hubs have launched in Rhode Island with various ECHO courses focused on addressing different patient populations. The purpose of this article is to provide an overview of the ECHO programs across the state, and ensure that readers know how to find out about current and future courses.

THE WARREN ALPERT MEDICAL SCHOOL OF BROWN UNIVERSITY ECHO HUB

Created in 2019, this ECHO hub has hosted several courses led by faculty from the Department of Family Medicine geared towards primary care clinicians across the state. Completed courses have included a Latent Tuberculosis Infection ECHO (2020–2021), a Telemedicine for Educators ECHO (2021), a Hepatitis C ECHO (2022–2023) and a Perinatal Opioid Use Disorder ECHO (2023). Pre- and post-quantitative assessments of the Latent Tuberculosis Infection (LTBI) ECHO demonstrated a significant increase in self-reported confidence in various LTBI practice areas before and after the ECHO course. Information about future courses can be found on the hub's website: https://sites.brown.edu/project-echo

HEALTHCENTRIC ADVISORS ECHO HUB

Created in 2019, this ECHO hub has hosted several courses such as the HOMESS ECHO series which focused on operating meaningful engagement for staff stability, a COVID-19 in Nursing Homes ECHO, a Behavioral Health education series, and PROJECT ROPE, which focused on reducing opioid use for pain management. In partnership with the Rhode Island Geriatric Education Center, six Project ECHO series took place in 2020 and 2021 focusing on COVID-19 safety protocols, vaccines, and the impact of COVID-19 among elderly patients, as well as behavioral health support. In Fall 2021 and Spring 2022, "Assessing and Caring for Persons with Cognitive Impairment" took place. Hundreds of health professionals from a variety of disciplines and settings, including primary care, long-term care, skilled nursing, and home care have attended. New ECHO Series will be announced via the website at www.healthcentricadvisors.org and will be distributed to the intended audience via constant contact.

CARE TRANSFORMATION COLLABORATIVE OF RHODE ISLAND (CTC-RI) ECHO HUB

Created in 2022, this ECHO hub is the newest in the state and focuses on supporting primary care transformation efforts. The first ECHO session was developed to support pediatric practices in the management of weight disorders among their pediatric

patients. The second ECHO was an Asthma Essential learning series for primary care, school nurses, and other interested community partners. Both ECHOs included a quality improvement component and offer stipends for achieving milestones. Evaluation results showed improved provider confidence, knowledge and comfort with managing these conditions. Future courses to be offered in 2023–2024 include a program improving care for children and adolescents with restrictive eating disorders by optimizing integrated behavioral health, and improving care for people with Alzheimer's Disease and their caregivers. Information about future courses can be found on the hub's website: https://www.ctc-ri.org/06/13/2022/ctc-ri-completes-echo-training-and-lays-groundwork-asthma-and-pediatric-weight-management

CONCLUSION

In Rhode Island, primary care team members have the opportunity to engage in ECHO courses focused on a breadth of topics and patient populations. These unique continuing medical education opportunities create innovative learning communities that can ultimately improve care across the state.

Authors

Daria Szkwarko, DO, MPH, Warren Alpert Medical School of Brown University, Family Medicine, Providence, RI.

Linda Cabral, MM, Care Transformation Collaborative of Rhode Island, Providence, RI.

Gail Patry, RN, Healthcentric Advisors, Providence, RI.

Acknowledgment

Aspects of the projects discussed were supported by the Health Resources and Services Administration (HRSA) of the U.S. Department of Health and Human Services (HHS) as part of an award totaling $5,742,871 with 0% financed with non-governmental sources. The contents are those of the author(s) and do not necessarily represent the official views of, nor an endorsement, by HRSA, HHS, or the U.S. Government. For more information, please visit HRSA.gov.

Correspondence

Daria Szkwarko, DO
111 Brewster St.
Pawtucket, RI 02860
401-921-7981
szkwarkd@gmail.com

Founders share thoughts on 20 years of 'The ECHO Ripple Effect'

ALBUQUERQUE, NM – Over 20 years, Project ECHO's health programs, based at The University of New Mexico Health and Health Sciences ECHO Institute, have expanded from a single weekly session focused on hepatitis C in New Mexico, to a global network of hundreds of specialized programs with learners in 195 countries.

In addition, it has recently partnered with the World Health Organization (WHO) to establish the WHO Collaborating Center for Digital Learning in Health Emergencies.

Sanjeev Arora, MD

"Building on the success of our partnership with the WHO in addressing the significant global health challenges posed by COVID-19 and preparing for future pandemics, we are proud to launch the first Collaborating Center for Digital Learning in Health Emergencies," said **SANJEEV ARORA, MD**, Project ECHO Founder and Director. "The ECHO Model is uniquely suited to help global organizations, governments and non-governmental organizations (NGOs) respond to emergencies, from pandemics, natural disasters to healthcare crises during violent conflicts, as we've seen in Ukraine and Sudan."

The three medical providers who started it all, Dr. Arora, **KARLA THORNTON, MD, MPH**, and **PAULINA DEMING, PharmD, RPH, PHC**, recently shared their thoughts on Project ECHO's past, present, and future.

From left at table, **Drs. Paulina Deming**, **Karla Thornton**, and **Sanjeev Arora**, at the most recent 2023 Project ECHO conference in New Mexico. They have worked together for two decades to establish a global network of healthcare programs. [UNM HEALTH]

Dr. Arora: "We always wanted to serve rural populations, prisons, and people who couldn't afford to see a specialist. Equity is the underlying principle of why we do ECHO. The ECHO Model has established a historic precedent for the possibilities of sharing knowledge. This served as an example for so many other complex issues, such as very complex diseases like HIV and TB, and for education and even in mitigating climate change – issues the world has been struggling with for decades. One of the least considered populations for hepatitis C treatment was incarcerated people. When we started, not a single patient in the prison had ever been treated for hepatitis C."

Dr. Deming: "We can see that a common thread for professionals involved in any ECHO program – all of the thousands that now exist – is they want to step up and fulfill a need in their community. The ECHO Model really enables that. It created more of an impact on the population as a whole in New Mexico than I would have been able to do just seeing one patient at a time in my own clinic. Pharmacists, especially, aren't usually treating hepatitis C but now we have a robust network, often in rural and underserved areas like Indian Country, who have learned how to do this. The ECHO team always knew what we wanted to do – but the success was still unprecedented."

Dr. Thornton took the lead with working with incarcerated populations, leading to Peer Education Program ECHO. "We started screening and realized hepatitis C infection and re-infection rates in the prisons were around 50 percent, which was a revolving door to infecting the general population, too. Now we treat 500–600 patients a year in all 11 prisons in New Mexico. The Peer Education Program ECHO and related programs for Community Health Workers and Peer Social Workers are flagship New Mexico ECHO programs.

"I'm most proud of the community we helped to build and the longitudinal impact of that on equity: proving this can – and should – be done. We are all in this together." ❖

Project ECHO with Director **Sanjeev Arora, MD**, center, launched the First World Health Organization (WHO) Collaborating Center for Digital Learning in Health Emergencies at the September MetaECHO conference. [UNM Health]

Wireless, handheld, non-invasive device detects Alzheimer's and Parkinson's biomarkers

SAN DIEGO – An international team of researchers has developed a handheld, non-invasive device that can detect biomarkers for Alzheimer's and Parkinson's disease. The device relies on electrical rather than chemical detection, which researchers say is more accurate and easier to implement. It can transmit the results wirelessly to a laptop or smartphone.

The team tested the device on in vitro samples from patients and showed that its accuracy is state-of-the-art.

The researchers used facilities that are part of the U.S. National Science Foundation Materials Research Science and Engineering Center at the University of California San Diego. The findings are published in Proceedings of the National Academy of Sciences.

The biosensor and reader, designed for home or point-of-care use, can transmit results wirelessly. [DAVID BAILLOT/UNIVERSITY OF CALIFORNIA SAN DIEGO]

By the year 2060, it is predicted that about 14 million Americans will suffer from Alzheimer's disease. Other neurodegenerative diseases, such as Parkinson's, are also on the rise. Current testing methods for Alzheimer's and Parkinson's require a spinal tap and imaging tests, including an MRI. As a result, early detection of the disease is difficult. Testing is especially difficult for patients who are already exhibiting symptoms and have difficulty moving, as well as for those who have no access to local hospitals or medical facilities.

The new finding is the result of three decades of work. In the current research, the team adapted a device during the COVID-19 pandemic to detect the spike and nucleoproteins in the live virus.

The scientists tested the device with brain-derived amyloid proteins from deceased Alzheimer's and Parkinson's patients. The biosensors were able to detect specific biomarkers for both conditions with great accuracy, on par with existing state-of-the-art methods. The device also works with extremely small sample sizes.

The next steps include testing blood plasma and cerebrospinal fluid, then finally saliva and urine. The tests would take place in hospital settings and nursing homes. The goal is to have the device on the market in a year. ❖

RIDOH and RIAG deem The Centurion Foundation HCA Application complete

PROVIDENCE – The Rhode Island Department of Health (RIDOH) Interim Director **UTPALA BANDY, MD, MPH**, and Rhode Island Attorney General **PETER F. NERONHA**, the two State regulators empowered to oversee hospital conversions in Rhode Island, notified the parties involved in the proposed hospital conversions of Roger Williams Medical Center and Our Lady of Fatima Hospital in a letter that their application has been deemed complete to initiate formal review.

The two hospitals are operated by CharterCARE, which is currently owned by Prospect Medical Holdings. The proposed transaction would sell the CharterCARE hospital system to The Centurion Foundation, a Georgia-based non-profit company.

The Attorney General and RIDOH will now have 180 days to review the application under the Hospital Conversions Act (HCA), before issuing their respective decisions. Consistent with the standard process set forth by statute, the Attorney General's Office will make the application public in mid-January after completing a full review to protect confidential information of the transacting parties, in accordance with the provisions of the HCA. The review process will also include public comment meetings and hearings.

Under the HCA, transacting parties seeking the transfer of ownership of a hospital must first complete an Initial Application which is filed with the Office of the Attorney General and the RIDOH. Following review of the submission from Prospect Medical Holdings and The Centurion Foundation, the Attorney General and RIDOH determined that the submitted materials contain sufficient information necessary for the State to initiate its review under the HCA. ❖

Governor McKee, EOHHS announce procurement for Medicaid Managed Care Organizations

PROVIDENCE – Governor **DAN MCKEE** and the Rhode Island Executive Office of Health & Human Services (EOHHS) announced the release of a Request for Proposals (RFP) for Managed Care Organizations, or MCOs. Rhode Island's Medicaid Managed Care Organizations provide healthcare delivery to over 320,000 – or 90% – of the state's Medicaid members each year. The RFP is available via the State's purchasing website at https://www.ridop.ri.gov. [r20.rs6.net]The RFP requires new quality, oversight, and financial management requirements which will lead to improved outcomes for Medicaid members.

The new RFP and contract requirements enhance quality, oversight and financial management through steps including:

- Reducing unnecessary prior authorizations (PAs), particularly for behavioral health services through the elimination or unnecessary administrative burden of PAs on providers and requiring an independent entity to review compliance with behavioral health parity requirements;
- Requiring executive level compensation transparency, including job qualifications, organizational structure and ensuring ethical conduct of a MCO's Board of Directors to ensure the appropriate use of Medicaid funds;
- Increased market competition among MCOs to ensure fair and competitive market practices, ensure fair competition to reduce program costs and increase access to care for beneficiaries;
- Requiring EOHHS to approve contracts for MCO major subcontractors. MCOs will be required to inform EOHHS when they place a subcontractor on a corrective action plan due to poor performance. Corrective action plans will be posted to the MCO's website for further transparency and ability to request a MCO to remove a subcontractor due to poor performance;
- Increased oversight and accountability for the use of Pharmacy Benefit Managers (PBM), including the prohibition of spread pricing and flexibility for EOHHS to move towards a single-state PBM under the review and direction of EOHHS;
- Increased information systems and testing review of protected health data to ensure privacy and protection for member health data and data system performance;
- Improving budget predictability and creating incentives for person-centered, efficient care with payments linked to member outcomes and flexibility to move towards full risk in SFY26;
- Increasing financial sanctions, performance metrics and publication of corrective actions against noncompliant MCOs;
- Revised amendment process to ensure federal and state law changes are implemented timely to support provider rate stability;
- The designation of a children's health coordinator to ensure all children enrolled in an MCO receive appropriate care, required vaccinations and lead testing through performance withholds;
- The flexibility to increase value-based payments through case management delegation to certified accountable entities and flexibility to implement primary care capitation models;
- Expanding Managed Care to Rhode Islanders who are dually enrolled in Medicare and Medicaid, so these members can choose to receive all care from the same health plan;
- Robust program integrity safeguards and oversight requirements to mitigate and reduce fraud, waste and abuse;
- Incorporating Long-Term Services and Supports (LTSS) as an in-plan benefit for all populations, creating a more comprehensive benefit approach under Managed Care and support members to remain in community settings;
- Improving care coordination across the continuum, reducing duplication and fragmentation, with fewer transitions; and,
- Increasing investments in population health and health equity, focusing on the identification of health disparities, engagement of communities, and investment in addressing health-related social needs under new authorities granted by the federal government to address social determinants of health.

To ensure a smooth transition, all current Managed Care Organizations – Neighborhood Health Plan of Rhode Island, Tufts Public Health Plans and UnitedHealthcare – have signed contract extensions through June 30, 2025. This ensures that all current MCOs are committed to providing care through the end of the contract and that no vendor will exit the marketplace early, in the event they decide not to bid or if they do not win the bid. The new contract, which will begin on July 1, 2025, will run through June 30, 2030, with an option to extend for up to five additional years. ❖

Appointments

Elizabeth Lowenhaupt, MD, CCHP, named Chair of NCCHC Board

PROVIDENCE – **ELIZABETH LOWENHAUPT, MD, CCHP**, associate director of training for the Brown Triple Board Combined Residency Training Program in Pediatrics, Psychiatry, and Child and Adolescent Psychiatry and the Child and Adolescent Psychiatry Fellowship at Rhode Island Hospital, has been appointed the 2023–2024 chair of the National Commission on Correctional Health Care (NCCHC) Governance Board.

Dr. Lowenhaupt, recognized for her expertise in child and adolescent behavioral health, is the consulting medical and psychiatric director at the Rhode Island Training School, the state's only juvenile correctional facility, where she provides direct psychiatric assessments and treatment to incarcerated adolescents and oversees all medical, dental, and psychiatric care for detained and adjudicated youth.

She is active in community health, having developed the HOPE for Justice clinic. An acronym for Hasbro (Children's Hospital) Outpatient Psychiatric Evaluations for Justice-involved and At-Risk Youth, HOPE for Justice expands psychiatric treatment for youth involved in the juvenile legal and child welfare systems across a continuum of community-based and residential treatment settings.

She represents the American Academy of Child and Adolescent Psychiatry on the Board of the National Commission for Correctional Health Care, where she also serves as the Chair of the Juvenile Health Committee.

An associate professor in the departments of psychiatry and human behavior and pediatrics at the Alpert Medical School, Dr. Lowenhaupt is focused on developing creative approaches to meet the capacity demand for more behavioral health professionals resulting from the current mental health crisis among children and adolescents. ❖

Audrey Tyrka, MD, PhD, appointed Chair of the Department of Psychiatry and Human Behavior

PROVIDENCE – **AUDREY TYRKA, MD, PhD**, has been appointed chair of the Department of Psychiatry and Human Behavior at the Alpert Medical School, making her the first woman to chair the department of Psychiatry and Human Behavior at Care New England, effective January 1, 2024. In addition, she will be appointed to the Mary E. Zucker Professorship in Psychiatry and Human Behavior.

Dr. Tyrka completed the Medical Scientist Training Program at the University of Pennsylvania and received her MD and PhD in psychology in 1999. She completed residency training at Brown and further research training in clinical neuroscience at the Mood Disorders Research Program at Butler Hospital. She joined the Brown faculty in 2003, as a psychiatrist and NIMH K23 research career development awardee at Butler Hospital. She was the Director of the Laboratory for Clinical and Translational Neuroscience at Butler Hospital and served as the Director of Research at Butler Hospital from 2014-2021. Professor in the Department of Psychiatry and Human Behavior since 2015, Dr. Tyrka was most recently Vice Chair of Psychiatry and Human Behavior at Brown and Chief Scientific Officer at Care New England. She is also affiliated faculty of the Carney Institute for Brain Science at Brown.

Dr. Tyrka is known for her groundbreaking work on early adversity and trauma in children and adults, including discoveries of key social, behavioral, and molecular mechanisms of health risk and resilience. This work involves collaborations with dozens of faculty across several departments at Brown in addition to national and international collaborations. She is the founding Co-Director of the Initiative on Stress, Trauma, and Resilience (STAR) at Brown, which includes a Center of Biomedical Research Excellence (COBRE) grant and a T32 post-doctoral research fellowship program at The Miriam Hospital.

Dr. Tyrka has also contributed to pharmacologic, behavioral, and neuromodulation treatment trials for depression and is an attending psychiatrist in the Butler Hospital Transcranial Magnetic Stimulation Clinic. A dedicated and accomplished mentor and leader in research training, she is Director of the NIMH-funded R25 Research Training Program for physician scientists in psychiatry training and the Summer Research Fellowship for medical students from backgrounds underrepresented in medicine.

An elected fellow of the American College of Neuropsychopharmacology (ACNP), Dr. Tyrka has held several national leadership roles, including as Chair of the ACNP Women's Taskforce. ❖

Appointments

Joanne Barrett, RN, BSN, named Women Veterans Program Manager at VA Providence

PROVIDENCE — The VA Providence Healthcare System announced that **JOANNE BARRETT, RN, BSN**, has been named the Women Veterans Program Manager. Barrett is a Veteran with 24-years of service in the Rhode Island Air National Guard as a combat medic and a nurse. She has also been working at VA Providence since 2009, in various roles such as medical technician, Intensive Care Unit nurse, and Operating Room/Patient Acute Care Unit nurse.

"Joanne Barrett brings a wealth of experience, knowledge, and passion to her new position," said **LAWRENCE CONNELL**, VA Providence Healthcare System Director, "we're extremely pleased she is in this role."

Barrett aims to inform women Veterans about the many programs and benefits that VA Providence offers, such as:

- Women's primary care in Providence, Middletown, New Bedford, and Hyannis, with designated women providers who offer comprehensive and gender-specific care;
- Family planning and preconception counseling, menopause care, mental health treatment, osteoporosis screening and management, and more;
- Preventive care including cancer screenings and immunizations;
- Telehealth, gender affirming care, weight management, nutrition, and wellness programs. ❖

Patrick Vivier, MD, PhD, named Dean of URI College of Health Sciences

KINGSTON – The University of Rhode Island has appointed **PATRICK VIVIER, MD, PhD**, as the next dean of the College of Health Sciences. Dr. Vivier is a member of the Tufts University School of Medicine senior leadership team and currently serves as interim chair of the Tufts Public Health and Community Medicine Department; director of the Public Health Program; and professor of public health and community medicine, and pediatrics.

Prior to his tenure at Tufts, which began in 2022, he served on the faculty at Brown University for more than 25 years and was a pediatrician at Rhode Island's Hasbro Children's Hospital.

At Brown, Dr. Vivier was the founding director of the Hassenfeld Child Health Innovation Institute. He helped establish an interdisciplinary team of faculty and staff spanning the Schools of Medicine and Public Health, Hasbro Children's Hospital, and Women & Infants Hospital that engaged in interdisciplinary research. He led the development and implementation of a strategic plan that included a focus on key childhood health issues and developed partnerships with state government agencies in support of public health initiatives.

Dr. Vivier also served as director of several Brown programs, including the interdisciplinary education programs in public health, the clinical and translational research training programs, the Master of Public Health program, and the community health clerkship. At Hasbro Children's Hospital, he served as director of the Division of General Pediatrics and Community Health.

Dr. Vivier was a professor of pediatrics at Brown and Tufts. He is the recipient of several awards, including the Royce Family Associate Professorship in Teaching Excellence from Brown, the Healthy Housing Award from the Rhode Island Department of Health, and the Robert Wood Johnson Generalist Physician Faculty Scholar Award.

He earned a bachelor's degree with honors in medical anthropology and a Doctor of Medicine degree from Brown, and a PhD from Johns Hopkins University. He performed his residency in pediatrics at Brown, Rhode Island Hospital, and Women & Infants Hospital; and a fellowship in health services research with a focus on primary care at Johns Hopkins.

Dr. Vivier has served on several national committees, including a current role as chair of site visit teams for the Council on Education for Public Health. He is a member of the American Pediatric Society, the Society for Pediatric Research, the Academic Pediatric Association, and the American Academy of Pediatrics.

His appointment follows a comprehensive and competitive national search. His tenure at URI will commence on January 16, 2024. ❖

Appointments

Mahesh V. Jayaraman, MD, named Chief of Diagnostic Imaging at Lifespan

PROVIDENCE – **MAHESH V. JAYARAMAN, MD**, director of the Neurovascular Center at Rhode Island Hospital, has been named Chief of Diagnostic Imaging at Lifespan. He will also be Chair of the Department of Diagnostic Imaging at the Alpert Medical School and the Elfriede Collis-Frances Weeden Gibson Professor of Diagnostic Imaging.

Dr. Jayaraman is the president of the Society of Neurointerventional Surgery, a senior member of the American Society of Neuroradiology, and a fellow of the American College of Radiology. He completed the residency program in Diagnostic Radiology at Rhode Island Hospital/Brown University, where he was chief resident, and fellowships in both Diagnostic and Interventional Neuroradiology at Stanford University.

As Lifespan's Chief of Diagnostic Imaging, he will spearhead the implementation of novel technologies aimed at improving patient care and expanding research in the areas of human factors research and population imaging, further solidifying Lifespan's commitment to advancing medical knowledge and improving healthcare outcomes.

"Dr. Jayaraman's advancements in clinical innovation have helped elevate the quality of Lifespan's diagnostic imaging services, which is essential to our mission of delivering exceptional care to patients," said Lifespan President and CEO **JOHN FERNANDEZ**. ❖

Recognition

Blue Cross & Blue Shield of Rhode Island earns top score in 2023–2024 Corporate Equality Index

PROVIDENCE – Blue Cross & Blue Shield of Rhode Island (BCBSRI) received a top score of 100 on the Human Rights Campaign Foundation's 2023–2024 Corporate Equality Index (CEI), the nation's foremost benchmarking survey and report measuring corporate policies and practices related to LGBTQ+ workplace equality.

BCBSRI joins the ranks of 545 major U.S. businesses that earned the Equality 100 Award: Leader in LGBTQ+ Workplace Inclusion. BCBSRI is the only insurer in Rhode Island to receive the award and is the only company to attain a score of 100 for nine consecutive years.

The results of the 2023–2024 CEI showcase how U.S.-based companies are promoting LGBTQ+ friendly workplace policies in the U.S. and abroad. The first year of the CEI included 319 participants, and the 2023–2024 CEI now includes 1,384 participants; further demonstrating the tremendous trajectory of the CEI, a record-breaking 1,340 businesses have non-discrimination protections specific to gender identity, up from just 17 in 2002. These critical non-discrimination protections cover 21 million employees in the United States and around the globe.

The CEI rates companies on detailed criteria falling under four central pillars:

- Non-discrimination policies across business entities
- Equitable benefits for LGBTQ+ workers and their families
- Supporting an inclusive culture
- Corporate social responsibility

The CEI rates employers providing these crucial protections to over 20 million U.S. workers and an additional 18 million outside of the U.S. Companies rated in the CEI include Fortune magazine's 500 largest publicly traded businesses, American Lawyer magazine's top 200 revenue-grossing law firms (AmLaw 200), and hundreds of publicly and privately held mid- to large-sized businesses.

The full report is available online at www.hrc.org/cei. ❖

Places

URI College of Pharmacy wins national grant to improve access to opioid use disorder medications

KINGSTON [UNIVERSITY OF RHODE ISLAND] – The University of Rhode Island College of Pharmacy will further the fight against the ongoing opioid epidemic thanks to a new $455,000 grant from the Foundation for Opioid Response Efforts (FORE) to train pharmacists to prescribe and dispense medications for opioid use disorder.

Led by Clinical Professor **JEFFREY BRATBERG, PharmD**, the College of Pharmacy will initiate two novel approaches to providing medications for opioid use disorder via community pharmacies, particularly in areas where physician prescribers are limited. First, a collaborative practice agreement developed in Rhode Island, in which a pharmacist is allowed to prescribe and treat a specific condition under the supervision and authority of a licensed physician, will be adapted and implemented in Connecticut. It will enable pharmacists in that state to be trained to initiate buprenorphine and provide maintenance care to people with opioid use disorder.

Second, a protocol for informing patients, starting treatment, and providing ongoing care will be implemented in community pharmacies in Ohio, where Drug Enforcement Administration-licensed pharmacists can prescribe controlled substances. The Legislative Analysis and Public Policy Association, through this funding to URI, will also conduct a state-by-state review of pharmacy regulations and develop toolkits for pharmacies in other states with the goal of expanding these new approaches to community pharmacies across the United States.

"I look forward to exploring and documenting the most effective ways to build sustainable addiction treatment models in community pharmacies," Dr. Bratberg said. "As key access points for harm reduction services like naloxone, sterile syringes, and medication for opioid use disorder, pharmacists play an essential role in addressing the overdose crisis."

The award is part of $1.3 million in new grants FORE awarded as part of a mission to improve access to lifesaving opioid use disorder medications, which are key to reversing overdoses. Only about 18 percent of people with opioid use disorder report the use of lifesaving medications like buprenorphine in their recovery, despite efforts to increase the number of providers who can prescribe it.

Dr. Bratberg has a history of working to improve access to medications to treat opioid use disorder. During his time at URI, he has established an overdose education and naloxone training program for pharmacists in the first-in-nation statewide Collaborative Pharmacy Practice Agreement for naloxone, and led a study published in the New England Journal of Medicine showing patients with opioid use disorder can safely receive treatment in a community pharmacy, and that they are more likely to follow up with treatment. He played a key role in the American Pharmacists Association's policy statements expressing support for decriminalizing the personal possession or use of illicit drugs and drug paraphernalia; serves on the Rhode Island Governor's Overdose Prevention and Intervention Task Force, and has led several research efforts on the subject, funded by multiple national organizations. ❖