Improvise, Adapt & Overcome: Successful Surgery-Sparing Prosthetic Hip Infection Antibiotic Suppression During COVID-19 Crisis

DEREK R. JENKINS, MD; JAD ARIDI, MD; PETER T. EVANGELISTA, MD; TERRIE FOX WETLE, PhD; RICHARD W. BESDINE, MD; JOHN R. LONKS, MD

ABSTRACT

CASE: A 79-year-old active male presented during the first COVID-19 pandemic surgery moratorium with late *Staphylococcus lugdunensis* periprosthetic total hip arthroplasty infection. Due to the unprecedented circumstances, novel treatment of IV and oral antibiotic suppression was trialed without preceding surgical intervention. At latest follow-up, the patient has two-year revision-free survival with normalization of inflammatory markers and MRI findings, and resolution of clinical symptoms.

CONCLUSION: We report a novel surgery-sparing treatment for periprosthetic hip infection. Judicious caution should be used in the application of similar therapies, as host and organism characteristics likely contributed substantially to the success of this case.

KEYWORDS: *Staphylococcus lugdunensis*, hip arthroplasty, periprosthetic infection

INTRODUCTION

It has been said that necessity is the mother of invention. At times, from late 2019–2022, due to resource consumption, scarcity, and allocation toward battling the COVID-19 pandemic, and risk of nosocomial SARS-2-CoV-2, our ability to bring patients to the operating room for orthopedic surgeries was limited. In early 2020, before a vaccine was available and when many factors were still yet unknown about the COVID-19 disease, major medical and ethical considerations arose concerning exposing patients to potential life-threatening COVID-19 infection in the surgical episode of care. Mortality risk was exceptionally high at this time, especially in older patients, with rates reported over 10%.[1] It is under these unprecedented circumstances that we present a case of a periprosthetic joint infection (PJI).

CASE REPORT

The patient first presented as a 77-year-old male with radiographically-confirmed severe left hip osteoarthritis, which had become refractory to conservative care. Past medical history was significant for Parsonage-Turner syndrome in his right arm, status post C5-6 laminectomy, and medically treated benign prostatic hyperplasia and hypertension. He was a physically fit individual, BMI 22, a high-level competitive squash player, though was recently unable to compete at his previous level due to severe left hip pain and loss of motion.

He underwent left total hip replacement through the direct anterior approach October 2017 (**Figure 1**). His hospital course and early recovery were unremarkable, and he returned to sport 12 weeks postoperatively. Over the subsequent two postoperative years, the patient returned to high level sport, but with persistent hip flexor symptoms that improved only slightly with physical therapy and stretching.

The spread of COVID-19 began in 2019 but the scope of the pandemic was noted by very few, with only significant governmental concern in late January 2020. In March 2020 spread in the United States was significant, resulting in many unprecedented societal limitations including social distancing, mask mandates, and closing of infrastructure in attempts to prevent spread of the virus.

Figure 1. Postoperative AP (**A**) and cross table lateral (**B**) left hip radiographs showing uncemented left total hip arthroplasty with a fully hydroxyapatite-coated tapered wedge stem and porous coated titanium modular acetabular component and delta ceramic on highly-crosslinked polyethylene articulation.

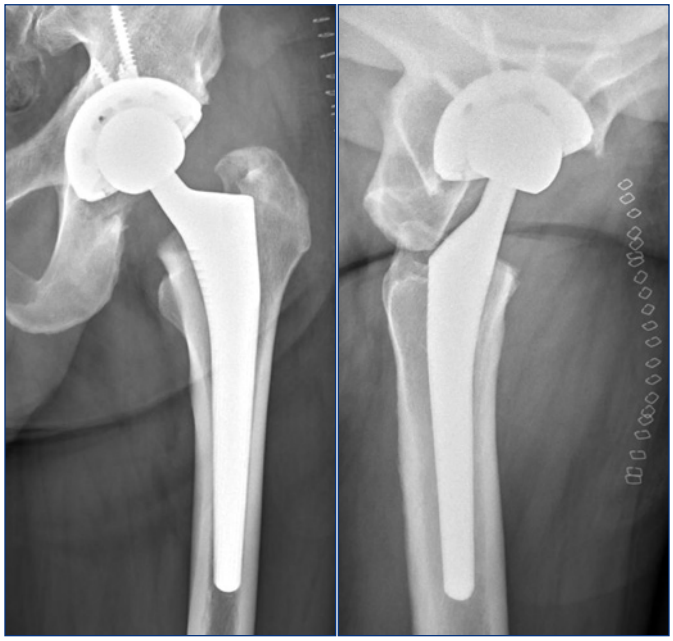

Figure 2: Postoperative AP (**A**) and cross table lateral (**B**) left hip radiographs showing uncemented left total hip arthroplasty with new periostitis (white arrow) and new osteolysis surrounding femoral component (black arrow).

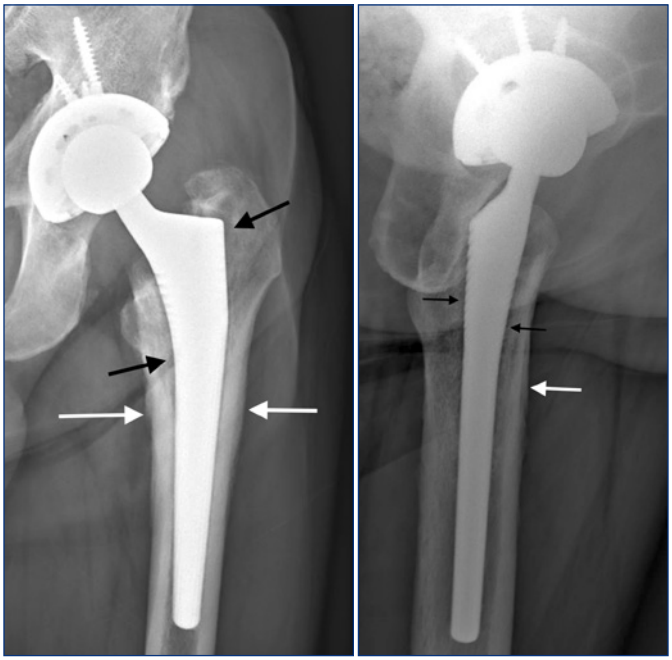

Figure 3. MARS protocol 1.5T MRI (Siemens Magnetom Aera) 3/25/20, **A** (coronal T1 WARP (Siemens) TR 487, TE 8.1) and **B, C** (axial STIR WARP TR 5000, TE 33) before initiation of novel treatment demonstrating femoral component osteolysis (black arrow in **A**), periostitis (black arrow in B), peri-implant marrow edema (white arrow in **B**), joint effusion (white arrow in **C**) and iliopsoas bursitis (black arrow in **C**) with debris/synovitis. No pericapsular edema is present, which is unusual in infection.

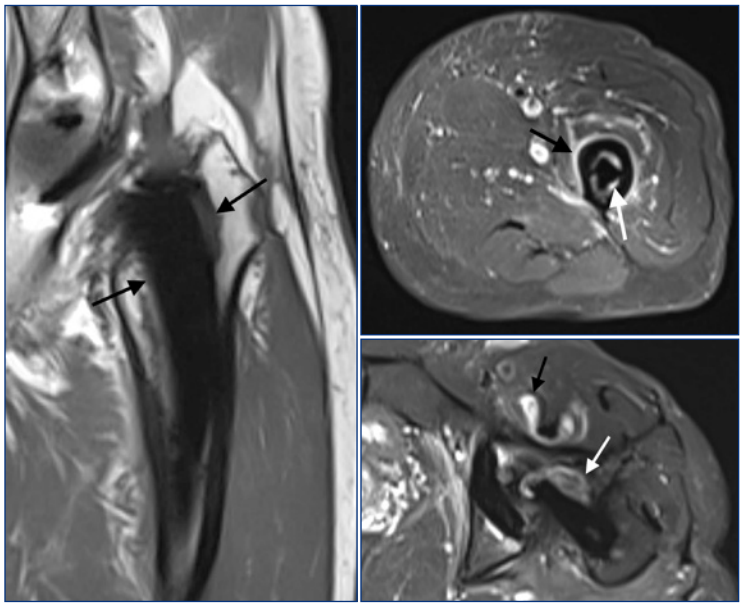

In March 2020, the patient presented to the office with increasing groin pain. Inflammatory labs were drawn: ESR 29 mm/h (normal 0-20); CRP 18 mg/L (normal 0–10). Left hip radiographs 3/17/20 revealed new femoral periostitis and osteolysis surrounding femoral component (**Figure 2**). Left hip MRI 3/25/20 confirmed radiographic findings and further revealed joint effusion with debris/synovitis, iliopsoas bursitis, and reactive left inguinal/external iliac adenopathy **Figure 3**). Principal diagnosis at this time was atypical organism PJI, with differential diagnosis including stress reaction with iliopsoas tendinitis/bursitis about the stem considering his high impact repetitive loading activities.

Due to the evolving COVID-19 pandemic, elective surgeries were halted at Lifespan, our academic medical center (Rhode Island Hospital and The Miriam Hospital) from March 23, 2020, to May 29, 2020. A hip aspiration was done March 27, 2020 and sent for manual differential, and culture to be held for 14 days. Nucleated cell count was reported to be 22,400/mm^3, 92% neutrophils, 5% monocytes/macrophages, 3% lymphocytes. Gram stain showed moderate PMN but no organisms seen. Cultures grew 1+ colonies of *Staphylococcus lugdunensis* after 3 days of incubation, susceptible to oxacillin, ciprofloxacin, erythromycin, clindamycin, tetracycline, rifampin, and vancomycin.

A multidisciplinary team, including specialists from orthopaedic surgery, radiology, infectious disease, geriatrics, and public health collaborated on the difficult task of medical decision-making. Although the infecting organism was determined to be *Staphylococcus lugdunensis*, it was fortunately susceptible to most antibiotics. Bioburden was also low; no organisms were seen on the gram stain, the cultures took several days to grow, and few colonies were seen on the culture plates. Serendipitously, the patient host was also an especially healthy and vigorous individual, whose presenting symptom was pain and not sepsis or systemic illness.

Three treatment options were considered: 1. two-stage-exchange-arthroplasty, 2. debridement, antibiotics, and implant retention, "DAIR," or 3. attempting a novel treatment with intravenous then oral antibiotics. The patient, in consultation with his care team and family elected treatment option 3.

Under different circumstances, a decision would have likely been made for source control to decrease bioburden with at least an irrigation and debridement surgery. After multiple discussions involving the clinical team, the patient and his family, a considered decision was made for a novel attempt at treatment with surgery-sparing antibiotic therapy. The patient was treated with a course of home-delivered IV followed by oral antibiotics, based on previously reported treatments.[2-6] A long-term suppressive antibiotic therapy was selected with a favorable side effect profile. (**See Table 1 for Antibiotic treatment**.)

On April 2, 2020 a 4-week course of in-home treatment with IV Ceftriaxone was initiated, PO Rifampin was added

Table 1. Antibiotic treatment

Week	Antibiotics Used	Start Date	Stop Date	Other Antibiotics Considered	Treatment Considerations, Modifications or Complications
1 to 4	Ceftriaxone 2g IV q 24h	4/2/20	4/30/20	Nafcillin IV	PICC line not possible due to patient's vasculature, so midline placed; nafcillin is contraindicated for administration through a midline due to reports of tissue necrosis in cases of extravasation
	Rifampin 900mg PO qd (600mg qam, 300mg qpm)	4/10/20			Rifampin was added to improve biofilm penetration. The staggered start of Rifampin after a week of ceftriaxone treatment was purposefully done in order to allow for a decrease of the initial bioburden in an attempt to avoid rapid development of bacterial resistance to rifampin especially in the absence of initial surgical source control.
5 to 16	Moxifloxicin 400mg PO qd	4/30/20	7/25/20	Ciprofloxicin PO	Midline removed after 4 weeks; clinical and inflammatory markers improved. Moxifloxacin chosen given its increased activity against Staphylococci compared to ciprofloxacin.
	Rifampin 900mg PO qd		7/25/20		
17+	Cefadroxil 500mg PO BID	7/25/20			After discussion with the treatment team, the patient elected to initiate long term antibiotic suppression therapy considering the lack of initial surgical source control and the aggressive nature of *S. lugdunensis*. The patient reported mild lower extremity neuropathy, which may have been associated with moxifloxacin. Additionally, due to the increased risk for tendinitis and tendon rupture with fluoroquinolones, moxifloxacin was discontinued and he was started on cefadroxil, an anti-staphylococcal first-generation cephalosporin, 500mg orally twice daily for suppression.

Figure 4. ESR and CRP graphed over time. Normal range ESR 0–20 mm/h. Normal Range CRP 0–10 mg/L. Included are timepoints of infection diagnosis and initiation of treatment.

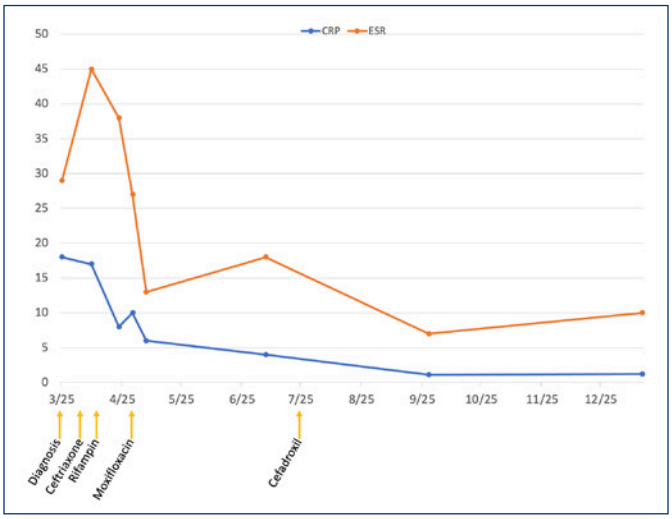

on April 10, and this course was followed by 3 months of oral Moxifloxacin and Rifampin. Close surveillance ensued over the next months through periodic telehealth visits and serial labs weekly for 10 weeks, then 2–3 weeks, and then monthly, followed by the clinical team to evaluate response to therapy. (**See Figure 4 for serial ESR and CRP values.**)

By July 9, 2020, inflammatory labs had fallen below the upper limit of normal, and continued trending down to a nadir (ESR 3 mm/h, CRP 0.83 mg/L) by the fall of 2021; physical exam was normal at in-person office visit. MRI July 21, 2020 showed resolution of previous periostitis and marrow edema. Improvement in joint effusion and iliopsoas bursitis was also noted. The femoral osteolysis persisted. The patient reported much less pain and was back to playing squash by September 29, 2020. MRI October 8, 2020 demonstrated similar findings of July 2020 with improvement in residual osteolysis and continued improvement of joint effusion and bursitis (**Figure 5**).

At his office visit April 13, 2021, more than a year after initiation of antibiotic treatment, the patient reported no pain, no systemic symptoms, and was playing squash. He continued to have some rare anterior groin pain consistent with his history of hip flexor tendinitis. Radiographs and physical exam are unchanged. He continues antibiotic suppressive therapy.

Currently, at over two years after initiation of this treatment, the patient is alive, revision-free, tolerating antibiotic suppression, without significant symptoms, and has returned to his previous high level of activity before PJI diagnosis. Post-treatment MRI shows normalization of findings. ESR and CRP have normalized and are stable in the normal range at most recent follow-up. Of interest, the patient contracted COVID-19 in 2022, after he had been vaccinated and boosted, and recovered uneventfully.

Figure 5. MARS protocol 1.5T MRI (Siemens Magnetom Aera) October 8, 2020, axial STIR WARP TR 6500, TE 34 demonstrate complete resolution of periostitis (black arrow) and peri-implant marrow edema (white arrow) 6 months after initiation of novel treatment.

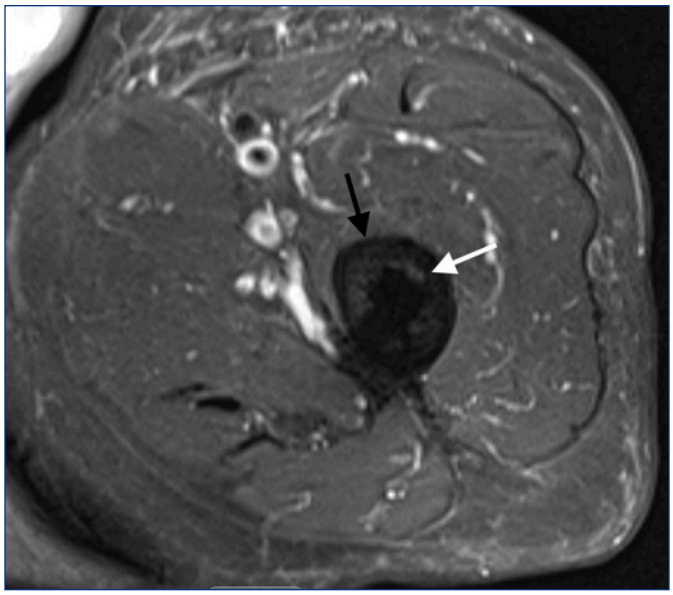

DISCUSSION

Prosthetic joint infections (PJI) are associated with considerable morbidity and mortality; treatment can be complicated, lengthy, costly, and unfortunately of limited success.[3,4] Capable of forming biofilms, Staphylococci species are responsible for a large proportion of PJI. The more virulent organism, *Staphylococcus aureus*, can cause higher-grade infections and can be particularly difficult to treat due to its ability to develop resistance. Coagulase Negative Staphylococci (CoNS)[5] PJI are generally considered atypical infections and are usually less aggressive. *Staphylococcus lugdunensis*, however, can behave similarly to *Staphylococcus aureus*.[6]

The gold standard treatment of PJI is surgical source control followed by targeted antimicrobial therapy driven by culture results.[7,8] Publications on PJI emphasize surgical debridement as an integral part of the therapeutic approach,[9,10] with some controversy over duration and type of subsequent antimicrobial therapy.[11] We assume our patient had a low bioburden since bacteria were not seen on gram stain, it took 3 days for cultures to grow, and there was only 1+ growth on culture plates. We have not found any reports in the literature of successful management of PJI without initial surgical debridement.[12] The importance of the treatment result presented in this case report is potentially of value to the orthopaedic and infectious disease communities; this could be the first report of successful treatment of PJI without an additional surgery. Definitive proof of cure cannot be determined in this case, however, due to the patient's subsequent treatment with suppressive antibiotic therapy.

It is our opinion that in most instances of prosthetic joint infection, source control with at least one additional surgical procedure would be necessary to decrease the concentration of bacteria to optimize the effect of antibiotic treatment. This approach would be especially important in the treatment of *Staphylococcus aureus* or other aggressive pyogenic PJI organism. Clinical caution should temper the extrapolation of the favorable results of this case to treatment of additional patients. However, especially during times of limited access to surgery, this approach may be a potential alternative.

References

1. O'Driscoll M, Ribeiro Dos Santos G, Wang L, Cummings DAT, Azman AS, Paireau J, Fontanet A, Cauchemez S, Salje H. Age-specific mortality and immunity patterns of SARS-CoV-2. Nature. 2021 Feb;590(7844):140-145. doi: 10.1038/s41586-020-2918-0. Epub 2020 Nov 2. PMID: 33137809.
2. Zimmerli W, Widmer AF, Blatter M, Frei R, Ochsner PE. Role of rifampin for treatment of orthopedic implant-related staphylococcal infections: a randomized controlled trial. Foreign-Body Infection (FBI) Study Group. JAMA. 1998 May 20;279(19):1537-41. doi: 10.1001/jama.279.19.1537. PMID: 9605897.
3. Premkumar A, Kolin DA, Farley KX, Wilson JM, McLawhorn AS, Cross MB, Sculco PK. Projected Economic Burden of Periprosthetic Joint Infection of the Hip and Knee in the United States. J Arthroplasty. 2021 May;36(5):1484-1489.e3. doi: 10.1016/j.arth.2020.12.005. Epub 2020 Dec 9. PMID: 33422392.
4. Corona PS, Vicente M, Carrera L, Rodríguez-Pardo D, Corró S. Current actual success rate of the two-stage exchange arthroplasty strategy in chronic hip and knee periprosthetic joint infection. Bone Joint J. 2020 Dec;102-B(12):1682-1688. doi: 10.1302/0301-620X.102B12.BJJ-2020-0792.R1. PMID: 33249903.
5. Aggarwal VK, Bakhshi H, Ecker NU, Parvizi J, Gehrke T, Kendoff D. Organism profile in periprosthetic joint infection: pathogens differ at two arthroplasty infection referral centers in Europe and in the United States. J Knee Surg. 2014 Oct;27(5):399-406. doi: 10.1055/s-0033-1364102. Epub 2014 Jan 10. PMID: 24414388.
6. Shah NB, Osmon DR, Fadel H, Patel R, Kohner PC, Steckelberg JM, Mabry T, Berbari EF. Laboratory and clinical characteristics of Staphylococcus lugdunensis prosthetic joint infections. J Clin Microbiol. 2010 May;48(5):1600-3. doi: 10.1128/JCM.01769-09. Epub 2010 Feb 24. PMID: 20181900; PMCID: PMC2863876.
7. Zimmerli W, Trampuz A, Ochsner PE. Prosthetic-joint infections. N Engl J Med. 2004 Oct 14;351(16):1645-54. doi: 10.1056/NEJMra040181. PMID: 15483283
8. Bernard L, Arvieux C, Brunschweiler B, Touchais S, Ansart S, Bru JP, Oziol E, Boeri C, Gras G, Druon J, Rosset P, Senneville E, Bentayeb H, Bouhour D, Le Moal G, Michon J, Aumaître H, Forestier E, Laffosse JM, Begué T, Chirouze C, Dauchy FA, Devaud E, Martha B, Burgot D, Boutoille D, Stindel E, Dinh A, Bemer P, Giraudeau B, Issartel B, Caille A. Antibiotic Therapy for 6 or 12 Weeks for Prosthetic Joint Infection. N Engl J Med. 2021 May 27;384(21):1991-2001. doi: 10.1056/NEJMoa2020198. PMID: 34042388.
9. Osmon DR, Berbari EF, Berendt AR, et al. Infectious Diseases Society of America. Diagnosis and management of prosthetic joint infection: clinical practice guidelines by the Infectious Diseases Society of America. Clin Infect Dis 2013; 56:e1–e25.
10. Tande AJ, Patel R. Prosthetic joint infection. Clin Microbiol Rev. 2014 Apr;27(2):302-45. doi: 10.1128/CMR.00111-13. PMID: 24696437; PMCID: PMC3993098.
11. San Juan R, Garcia-Reyne A, Caba P, Chaves F, Resines C, Llanos F, López-Medrano F, Lizasoain M, Aguado JM. Safety and efficacy of moxifloxacin monotherapy for treatment of orthopedic implant-related staphylococcal infections. Antimicrob Agents Chemother. 2010 Dec;54(12):5161-6. doi: 10.1128/AAC.00027-10. Epub 2010 Sep 20. PMID: 20855727; PMCID: PMC2981285.
12. Fink B, Schlumberger M. Antibiotic therapy alone does not have a high success rate in cases of unexpected positive cultures in intraoperative samples from hip and knee prosthesis revision. BMC Musculoskelet Disord. 2020 Nov 28;21(1):786. doi: 10.1186/s12891-020-03799-w. PMID: 33248455; PMCID: PMC7700714.

Authors

Derek R. Jenkins, MD, Brown University Department of Orthopaedic Surgery, Providence, RI.

Jad Aridi, MD, Brown University Department of Infectious Disease, Providence, RI.

Peter T. Evangelista, MD, Brown University Department of Diagnostic Imaging, Providence, RI.

Terrie Fox Wetle, PhD, Brown University School of Public Health, Providence, RI.

Richard W. Besdine, MD, Brown University Department of Geriatric Medicine, Providence RI.

John R. Lonks, MD, Brown University Department of Infectious Disease, Providence, RI.

Disclosures

Statement of Informed Consent: The study patient was informed that data concerning the case would be submitted for publication and agreed.

Correspondence

Derek R. Jenkins, MD
University Orthopedics, 1 Kettle Point Avenue
East Providence, RI 02914
401-453-9032
Fax 401-270-3256
derek_jenkins@brown.edu