Mobile Mitral Valve Vegetations: Not Your Usual Endocarditis

ROBERT S. FAIN, MSc; SOHUM PATWA, MD; HUSSAIN R. KHAWAJA, MD, FACP

ABSTRACT

Mitral annular calcification (MAC) is a chronic degenerative condition that is associated with age, chronic kidney disease, diabetes, dyslipidemia, hypertension, and tobacco use. Mobile calcified lesions can be mistaken for endocarditis on trans-thoracic echocardiogram (TTE), creating a unique diagnostic challenge. In this case, we describe a young dialysis patient who presented with dyspnea on exertion with no obvious etiology on initial work-up. TTE was obtained, which showed mobile lesions on the mitral and aortic valves, initially thought to be endocarditis, but later diagnosed as MAC. Trans-esophageal echocardiography (TEE) is a useful modality to differentiate mobile masses on the mitral valve.

KEYWORDS: mitral annular calcification, end stage renal disease, endocarditis, echocardiography

CASE PRESENTATION

A 42-year-old female with a past medical history of end-stage renal disease from focal segmental glomerulosclerosis on hemodialysis for the past four years presented to her cardiologist with worsening dyspnea on exertion and a feeling of "increased fluid in her lungs." When basic work-up did not reveal any obvious etiologies, an outpatient transthoracic echocardiogram (TTE) was obtained, which showed a normal ejection fraction and lesions on the mitral and aortic valves highly suggestive of vegetations. The patient was hospitalized with concern for endocarditis. On admission, the patient was afebrile. Physical examination was notable for hypertension and bilateral inspiratory pulmonary crackles. A holosystolic murmur was heard by the overnight admitting provider in the Emergency Department, but the inpatient medicine team did not hear any murmurs. Her leukocyte count was normal. Her sedimentation rate was elevated (64 mm/h), as was her C-reactive protein (40.30 mg/dL). An admission chest radiograph was notable for findings suggestive of pulmonary edema. As part of the workup, a repeat TTE revealed severe mitral annular calcification causing moderate-severe mitral inflow tract obstruction, and several mobile lesions on the mitral and aortic valves concerning for vegetation. Mitral regurgitation was not observed on TTE. The patient had no known history of rheumatic fever. Given dialysis patients' increased risk for infective endocarditis, with some studies showing 50–60 times the incidence compared to the general population, an extensive work-up was undertaken for infectious etiologies.[1] Blood cultures did not grow any organisms. Bartonella and Coxiella serologies were negative, and a β-D-Glucan assay was indeterminate. Despite negative blood cultures, the inpatient care team successfully advocated for a transesophageal echocardiogram (TEE) for further characterization of the valvular lesions. TEE revealed severe mitral valve calcifications with associated moderate mitral inflow tract obstruction and focal calcifications of the aortic valve, but no evidence of endocarditis. (**Figures 1,2**)

Figure 1. TEE in midesophageal long axis view. Notable for hyperechoic, mobile masses on the mitral valve (arrow).

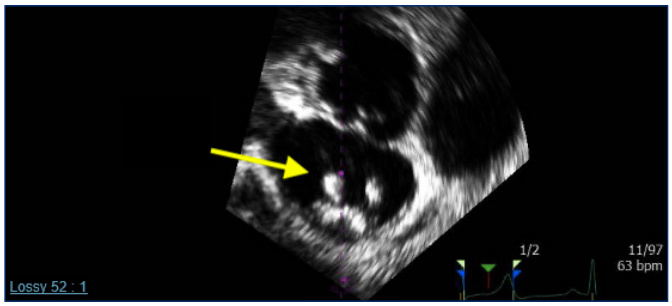

Figure 2. 3D reconstruction of mitral valve from TEE images. Notable for significant calcification resulting in moderate mitral inflow tract obstruction and thickened mitral valve annulus (arrows).

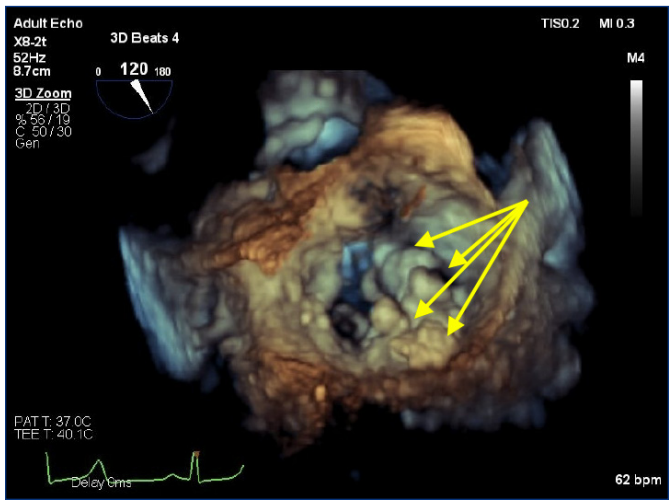

The diagnosis of mitral annular calcification resulting in moderate mitral inflow tract obstruction was made. Given the non-severe degree of her mitral valve disease, valve replacement or repair were not recommended by the cardiothoracic surgical service. The patient received routine care and was discharged from the hospital. Her outpatient cardiologist recommended echocardiograms every six months to monitor for progression of her mitral valve disease. Four months after discharge, the patient returned to the hospital with further dyspnea on exertion. A repeat TTE did not show any changes; however, left heart catheterization revealed severe mitral inflow tract obstruction. The patient is currently being evaluated for mitral valve replacement.

DISCUSSION

The pathophysiology of MAC is thought to be a product of endothelial disruption, chronic inflammatory cell infiltration, and elevated calcium-phosphorus product.[2] Although mitral annular calcification is associated with older age, young patients on hemodialysis are at greatly increased risk for developing this condition. Observational studies have found MAC to be prevalent in over one third of patients who have been on hemodialysis for more than three years.[3] Advanced cases of MAC can result in left ventricular inflow obstruction and increased risk of arrhythmias. MAC is a marker of atherosclerotic disease and is associated with 60% increased incidence of cardiovascular disease related death and 30% increased incidence of all-cause mortality.[4,5] This case highlights the potential for mitral annular calcification to mimic vegetations on TTE, and therefore the possibility for MAC to be misdiagnosed as endocarditis. This case additionally highlights the importance of transesophageal echocardiography for the characterization of vegetations detected on transthoracic echocardiography when the pretest probability of endocarditis is not high. The clinical suspicion for MAC should be high in ESRD patients presenting with valvular abnormalities, regardless of their age, especially if stigmata of infective endocarditis are absent.

References

1. Nucifora G, Badano LP, Viale P, Gianfagna P, Alloca G, Montanaro D. Infective endocarditis in chronic haemodialysis patients: an increasing clinical challenge. European Heart Journal. 2007;28:2307-2312.
2. Freeman RV, Otto CM, Yeon SB. Clinical manifestations and diagnosis of mitral annular calcification. UpToDate. Online Article. Last Updated July 07, 2020. Accessed November 29, 2021.
3. Kraus MA, Kalra PA, Hunter J, Menoyo J, Stankus N. The prevalence of vascular calcification in patients with end-stage renal disease on hemodialysis: a cross-sectional observational study. Ther Adv Chronic Dis. 2015;6(3):84-96.
4. Fox CS, Vasan RS, Parise H, Levy D, O'Donnell CJ, D'Agostino RB, et al. Mitral Annular Calcification Predicts Cardiovascular Morbidity and Mortality: The Framingham Heart Study. Circulation. 2002;107:1492-1496.
5. Allison MA, Cheung P, Criqui MH, Langer RD, Wright CM. Mitral and Aortic Annular Calcification Are Highly Associated With Systemic Calcified Atherosclerosis. Circulation. 2006;113:861–866.

Authors

Robert S. Fain, MSc, Medical Student, Warren Alpert Medical School of Brown University, Providence, RI.

Sohum Patwa, MD, Internal Medicine Resident, Warren Alpert Medical School of Brown University, Providence, RI.

Hussain R. Khawaja, MD, FACP, Assistant Professor of Medicine, Clinician Educator, Brown Medicine, Brown Center for Primary Care, Rhode Island Hospital, The Miriam Hospital, Warren Alpert Medical School of Brown University, Providence, RI.

Acknowledgment

The authors did not receive any institutional funding for this research project.

Disclaimer

The views expressed herein are those of the authors and do not necessarily reflect the views of the Warren Alpert Medical School of Brown University, Brown University Internal Medicine Program, or Lifespan.

Correspondence

Robert S. Fain, MSc
robert_fain@brown.edu