Successful Fracture Healing for Femoral Neck Nonunion with Bone Marrow Aspirate Concentrate

JACOB M. MODEST, MD; NICHOLAS J. LEMME, MD; EDWARD J. TESTA, MD; ANDREW R. EVANS, MD; DANIEL B. C. REID, MD, MPH

ABSTRACT

INTRODUCTION: Femoral neck fractures in the young patient require prompt anatomic reduction and stabilization to preserve the vascular supply to the femoral head and minimize future need for arthroplasty. Secondary to unique biomechanical and vascular considerations, these injuries are prone to nonunion.

CASE REPORT: A 29-year-old male with a chronic femoral neck fracture nonunion who experienced successful fracture healing and symptom resolution following Bone Marrow Aspirate Concentrate (BMAC) administration.

DISCUSSION: Femoral neck nonunion in young patients is a challenging problem with treatment strategies aimed at improving the biological and biomechanical fracture environment. While the use of both vascularized and nonvascularized bone grafting has shown promising results, they have high complication rates and substantial donor site morbidity. BMAC has demonstrated multiple uses throughout orthopedic surgery and may result in an improved fracture healing environment with minimal patient morbidity.

CONCLUSION: The success of the BMAC procedure for this patient is promising and may be considered in similar patients, with or without revision internal fixation methods.

KEYWORDS: Bone Marrow Aspirate Concentrate, BMAC, femoral neck nonunion, femoral neck fracture, fracture nonunion, fracture healing

INTRODUCTION

Femoral neck (FN) fractures in young patients are typically the result of high energy trauma, and pose a complex problem for the treating orthopedic surgeon.[1] Given the tenuous blood supply to the FN, successful treatment of these fractures relies on anatomic reduction and primary bone healing.[2] FN fractures in young patients often have high Pauwel's angles and may be inherently unstable which predisposes these injuries to a high risk of complications.[1,2] A recent meta-analysis including 1558 fractures from 41 studies demonstrated a 14.3% rate of nonunion, 9.3% rate of avascular necrosis (AVN), and 18% reoperation rate.[3] Other studies have noted nonunion rates as high as 33%.[4] FN nonunion in this population is associated with persistent pain, disability, and poor patient satisfaction. Adjunct methods to enhance fracture biology when addressing FN non-unions have been advanced. In this case report, we present the novel use of bone-marrow aspirate concentrate (BMAC) for successful treatment of a persistent FN nonunion in a 29-year-old male patient.

Statement of Consent

The following described patient gave consent for his de-identified clinical course and radiographic and clinical images to be used in the creation of this case report.

CASE REPORT

We report the case of a 29-year-old nonsmoking healthy male who sustained a femoral shaft fracture with ipsilateral nondisplaced transcervical FN fracture and a tibial shaft fracture after a motorcycle collision. His FN fracture was fixed with three 6.5mm partially threaded cannulated screws, followed by retrograde and antegrade intramedullary nailing for his femoral and tibial shaft fractures, respectively.

One year postoperatively, the patient presented with symptomatic hardware in cold weather. His fractures appeared healed both clinically and radiographically, and thus indicated for elective removal of hardware (**Figure 1**).

Two years later, he reported several weeks of hip and groin discomfort, and subsequently sustained a pathologic displaced FN fracture without associated trauma (**Figure 2**). The patient underwent urgent open reduction and internal fixation with a sliding hip screw and two 6.5mm partially threaded anti-rotation screws through a Smith-Petersen approach. Intraoperatively, minimal bridging callus and necrotic-appearing bone edges were noted, consistent with atrophic nonunion. Preoperative inflammatory markers were normal and cultures and pathology obtained intraoperatively were negative for infection.

Follow-up imaging over the next 12 months showed minimal bridging bone or callous formation (**Figure 3**) and the patient complained of ongoing pain. Given prior intraoperative findings demonstrating limited biological healing potential and radiographic evidence of atrophic nonunion,

Figure 1. Transcervical femoral neck fracture and transverse femoral shaft fracture 6 months status post fixation with three 6.5mm cannulated screw and a retrograde femoral nail.

Figure 2. Displaced transcervical femoral neck fracture of unclear chronicity, discovered one year after elective removal of hardware.

Figure 3. Femoral neck nonunion, 12 months after revision fixation.

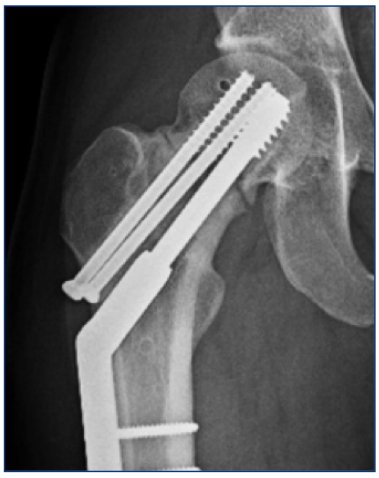

operative techniques aimed at optimizing biological environment were considered include vascularized and non-vascularized bone graft. Bone marrow aspirate concentrate (BMAC) has not been an extensively described technique for femoral neck nonunion but has shown some promise in the treatment of nonunions and as an adjunct therapy. Given the desire of the patient to avoid invasive surgery, and the very low complication rate of this technique, the patient elected to attempt use of BMAC for augmentation of fracture healing.

In the OR, ipsilateral iliac crest BMAC was harvested, and subsequently injected into the non-union site. A 1-cm incision was made posterior to the anterior superior iliac spine. 100cc of bone marrow aspirate was obtained and injected into two sterile centrifuge containers with a Jamshadi needle. The containers were placed in a centrifuge for 15 minutes and the bone marrow concentrate layer was then drawn into 10cc sterile syringes (**Figure 4**).[5] The antero-superior 6.5mm cannulated screw was removed percutaneously, and the screw pathway was cleared of any fibrous debris with a 5mm drill. A metal cannula was gently inserted into the screw pathway with the end placed at the site of the known nonunion and 5 cc of BMAC was injected into the FN fracture nonunion. Next, 4.5 cc of BMAC was then injected

Figure 4. Bone marrow aspirate from ipsilateral iliac crest after centrifuge concentration.

Figure 5. Intraoperative fluoroscopy images demonstrating injection of BMAC at fracture site through temporarily removed screw tract (star) and through intraarticular injection (arrow).

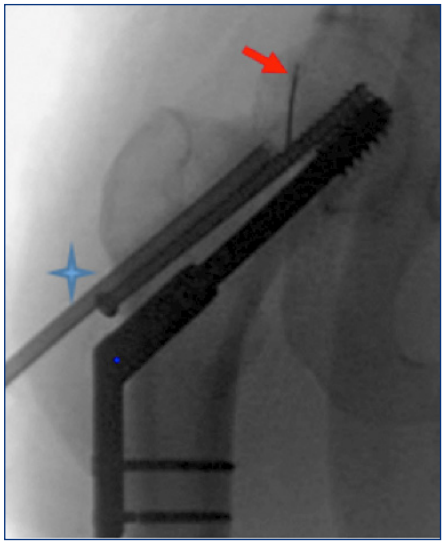

Figure 6. 12 months postop from BMAC injection, showing bridging and healing at superior aspect of the femoral neck nonunion and increased callous formation at inferior neck.

intraarticular into the hip joint using an 18-gauge spinal needle (**Figure 5**). A 7.3 mm partially threaded screw was used to replace the previous 6.5mm cannulated screw. The patient was made weightbearing as tolerated and discharged postoperatively without incident.

Postoperatively, radiographs and CT scan 12 months following surgery showed successful radiographic union of the fracture anteriorly and superiorly, which is exactly where the BMAC injections were placed (**Figure 6).** There was also interval callous formation and healing at the inferior neck. He reported complete resolution of his pain at this time.

DISCUSSION

In this case report, we present the case of a young male with a FN nonunion that demonstrated bony bridging and resolution of pain after BMAC injection at the fracture site. FN nonunion following fractures in young patients is challenging to manage.[4,6] There are two main treatment options – hip preservation or prosthetic replacement.[7] In most cases, joint preservation is preferable to arthroplasty in young patients, given high functional demands and substantial future life expectancy. Furthermore, arthroplasty can be performed if the effort for preservation fails.[8,9] The decision between the two strategies often depends on the presence of avascular necrosis with collapse of the femoral head, after which there are few treatment options besides a total hip arthroplasty. At the patient's age of 29, total hip arthroplasty has demonstrated poor results with high need for revision surgery and associated complications.[9]

Joint preserving treatment options for persistent nonunion have historically been aimed at improving the fracture's biomechanical environment, biologic environment, or both.[6] The most commonly utilized strategy for optimizing the biomechanical healing environment is an intertrochanteric valgus-producing osteotomy, also called a Pauwel's osteotomy, which converts shears force into compression forces at the fracture site. The Pauwel's intertrochanteric valgus osteotomy has promising outcomes with union reported in 44 of 48 patients in one study and in 58 of 66 patients in another study.[10,11] There are a multitude of similar cohort studies showing comparably high union rates.[12] Potential disadvantages of a valgus osteotomy include a decreased abductor lever arm, which may result in a Trendelenburg gait, iatrogenic leg length discrepancy, increasing contact pressures on the femoral head which may progress osteonecrosis and osteoarthritis, and potential nonunion at the new osteotomy site.[6] Reported strategies aimed at improving biology at the fracture site include muscle-pedicle bone grafting and vascularized bone grafting. Sen and colleagues reported that use of non-vascularized autogenous fibular grafting in combination with a fixed angle blade plate resulted in union in 21 of 22 patients (91%) over a period of 4.4 months.[7] Leung and Shen likewise reported a 100% union rate in 15 patients with vascularized iliac bone grafting and cannulated screw fixation of the FN fracture at 5–7 year follow up.[13] Adverse outcomes from autologous grafting are primarily related to donor site morbidity.[14]

Guidelines for treatment of this challenging problem of FN nonunion involve assessing for the presence of avascular necrosis to determine the feasibility of joint salvage versus arthroplasty, as well as assessing the cause of nonunion and potential need for altering the biomechanical and/or biological environment. However, there is no clearly agreed upon superior technique for accomplishing these goals. In this case we present successful treatment of a patient with an atrophic FN nonunion and normal neck-shaft angle using BMAC. BMAC is a form of osteogenic autograft that harvests mesenchymal stem cells (MSCs) from various anatomic regions including the iliac crest. The bone marrow harvested is centrifuged to allow for concentration of the MSCs for injection. The multipotent MSCs have osteogenic properties that facilitate bony healing by differentiation into osteoblast and osteoclast cell lines.

BMAC has several potential advantages over other techniques aimed at improving the biological environment. The described technique is a minimally invasive outpatient procedure and allows immediate postoperative weightbearing as well as an accelerated postoperative recovery. The risk of intraoperative and peri-operative complications with BMAC is likely far lower than with the two most common procedures used currently for treatment of FN nonunion in young patients, namely valgus intertrochanteric osteotomy and vascularized fibular autograft. Furthermore, the risk of donor site morbidity secondary to iliac crest bone marrow aspiration is low in comparison to autologous fibular and structural iliac crest grafting.[15] Clinical and radiographic results in the current case were consistent with successful union of the anterosuperior FN. The patient reported excellent clinical progression and return to all activities.

CONCLUSION

Femoral neck nonunion is a challenging problem, occurring in estimated 10–30% of FN fractures undergoing surgical reduction and fixation. It is particularly challenging in the young patient as arthroplasty has poor long-term outcomes and both biomechanical and biologic factors need to be considered. The use of BMAC to augment the biological healing environment in patients with delayed union or nonunion of the FN represents a novel technique with multiple benefits and potential uses. Nevertheless, this single case study serves as an early proof-of-concept and should not be interpreted to represent treatment recommendations. More rigorous research is needed to examine the utility and union rates following use of BMAC for the treatment of FN nonunion. With this case report we aim to distribute these results and inform orthopedic surgeons and other physicians of the potential of a valuable tool in management of FN nonunion in the young patient.

References

1. Robinson CM, Court-Brown CM, McQueen MM, Christie J. Hip fractures in adults younger than 50 years of age: Epidemiology and results. *Clin Orthop Relat Res*. 1995.
2. Panteli M, Rodham P, Giannoudis PV. Biomechanical rationale for implant choices in femoral neck fracture fixation in the non-elderly. *Injury*. 2015. doi:10.1016/j.injury.2014.12.031
3. Slobogean GP, Sprague SA, Scott T, Bhandari M. Complications following young femoral neck fractures. *Injury*. 2015;46(3):484-491. doi:10.1016/j.injury.2014.10.010
4. Lu-Yao GL, Keller RB, Littenberg B, Wennberg JE. Outcomes after displaced fractures of the femoral neck. A meta-analysis of one hundred and six published reports. *J Bone Jt Surg - Ser A*. 1994;76(1):15-25. doi:10.2106/00004623-199401000-00003
5. Chahla J, Mannava S, Cinque ME, Geeslin AG, Codina D, Laprade RF. Bone Marrow Aspirate Concentrate Harvesting and Processing Technique. 2017. doi:10.1016/j.eats.2016.10.024
6. Mathews V, Cabanela ME. Femoral Neck Nonunion Treatment. In: *Clinical Orthopaedics and Related Research*. Lippincott Williams and Wilkins; 2004:57-64. doi:10.1097/00003086-200402000-00010
7. Sen RK, Tripathy SK, Goyal T, et al. Osteosynthesis of femoral-neck nonunion with angle blade plate and autogenous fibular graft. *Int Orthop*. 2012;36(4):827-832. doi:10.1007/s00264-011-1344-1
8. Franzen H, Nilsson LT, Stromqvist B, Johnsson R, Herrlin K. Secondary total hip replacement after fractures of the femoral neck. *J Bone Jt Surg - Ser B*. 1990;72(5):784-787. doi:10.1302/0301-620x.72b5.2211756
9. Nilsson LT, Jalovaara P, Franzén H, Niinimäki T, Strömqvist B. Function after primary hemiarthroplasty and secondary total hip arthroplasty in femoral neck fracture. *J Arthroplasty*. 1994;9(4):369-374. doi:10.1016/0883-5403(94)90046-9
10. Marti RK, Schuller HM, Raaymakers ELFB. Intertrochanteric osteotomy for non-union of the femoral neck. *J Bone Jt Surg - Ser B*. 1989;71(5):782-787. doi:10.1302/0301-620x.71b5.2584247
11. Raaymakers ELFB, Marti R. Nonunion of the femoral neck: Possibilities and limitations of the various treatment modalities. *Indian J Orthop*. 2008;42(1):13-21. doi:10.4103/0019-5413.38575
12. Magu NK, Rohilla R, Singh R, Tater R. Modified Pauwels' intertrochanteric osteotomy in neglected femoral neck fracture. *Clin Orthop Relat Res*. 2009;467(4):1064-1073. doi:10.1007/s11999-008-0695-4
13. Leung PC. SWF of the femoral neck in younger adults. A new method of treatment for delayed and nonunions. CORR 1993 O-60. P 8403641. No Title.
14. Gaskill TR, Urbaniak JR, Aldridge JM. Free vascularized fibular transfer for femoral head osteonecrosis: Donor and graft site morbidity. *J Bone Jt Surg - Ser A*. 2009. doi:10.2106/JBJS.H.01105
15. Christophersen CM, Elattar O, Farber D. Pain and Complications following Bone Marrow Aspirate Concentrate (BMAC) Harvested from the Iliac Crest in Foot and Ankle Surgery. *Foot Ankle Orthop*. 2019;4(4):2473011419S0014. doi:10.1177/2473011419S00146

Authors

Jacob M. Modest, MD, Brown University, Department of Orthopedics.

Nicholas J. Lemme, MD, Brown University, Department of Orthopedics.

Edward J. Testa, MD, Brown University, Department of Orthopedics.

Andrew R. Evans, MD, Brown University, Department of Orthopedics.

Daniel B. C. Reid, MD, MPH, Brown University, Department of Orthopedics.

Disclosures

None

Correspondence

Jacob M. Modest, MD
2 Dudley St., Suite 200
Providence, RI 02905
jacob_modest@brown.edu