The Weekend Warrior: Common Foot and Ankle Injuries in Recreational Athletes

DAVIS A. HARTNETT, BS, MD'22; DEVIN F. WALSH, MD; DAVID R. RICHARDSON, MD; RAYMOND Y. HSU, MD

ABSTRACT

Weekend warriors are recreational athletes who compress their physical activity into 1–2 weekly exercise sessions. The characteristic combination of general deconditioning and excessive activity can predispose these individuals to a multitude of foot and ankle injuries. The purpose of this review is to highlight the etiology and management of common foot and ankle injuries in recreational athletes.

KEYWORDS: weekend warriors, recreational athletes, foot and ankle injuries

INTRODUCTION

The "Weekend Warrior" refers to an athlete who makes the ambitious effort to condense the weekly aerobic exercise recommendations of the Centers for Disease Control and Prevention into 1 to 2 short sessions per week. This practice is a common phenomenon in the sporting world.[1] Busy sedentary lifestyles combined with motivation to remain active have contributed to a rise in weekend warriors, and while in many ways not ideal, this style of physical activity has shown mortality benefits over the inactive alternative.[2] Still, the occasional heavy demand placed on the musculoskeletal system of an individual who typically lacks substantial conditioning puts them at risk for injury.[3] The foot and ankle undergo significant stress in nearly all recreational physical activities and are at risk of both acute and overuse injuries following physical activity.[3,4] The purpose of this review is to highlight some of the common foot and ankle injuries in recreational athletes (**Table 1**).

Table 1. Common Injuries in the Recreational Athletes

Featured in review	Beyond scope of review
Ankle	
Ankle sprain (common/low)	Ankle fracture
Syndesmotic injury (high ankle sprain)	Gastrocnemius (calf) strain
Achilles tendon rupture	Retrocalcaneal bursitis
Achilles tendinopathy (tendinitis)	Ankle arthritis
Foot	
Jones fracture	Other stress fractures
Metatarsal stress fracture	Lisfranc injury
Plantar fasciitis	Turf toe

ANKLE

Ankle sprain

The quintessential injury of the weekend warrior, ankle sprains are the traumatic stretching or tearing of ankle ligaments and are one of the most common athletic injuries, with an incidence of 7.2 per 10,000 exposures in adults. The ankle is the most commonly injured body part in 24 different sports, with ankle sprain representing the predominant ankle injury in 33 major sports.[5] Ankle sprains are classified either as high ankle sprains (syndesmosis injury) or low ankle sprains, the latter of which is conventionally implied when describing an otherwise unspecified "ankle sprain."

Low ankle sprains constitute a vast majority of ankle sprains, representing approximately 90% of all ankle ligament injuries.[6] Anatomically, the ankle joint is supported laterally by three ligaments: the anterior talo-fibular ligament (ATFL), the calcaneo-fibular ligament (CFL) and the posterior talo-fibular ligament (PTFL). The deltoid ligament supports the ankle joint medially, and is stronger and less frequently injured than its lateral counterparts. The ATFL in particular serves to prevent extreme plantarflexion and anterior talar translation, pulling taunt during plantarflexion. Injury to the ligaments of the ankle occurs most typically with a "roll" of the ankle, that is the inversion of a plantarflexed foot, which places increased stress on the already tight ATFL and can result in injury ranging from microscopic to total tearing. The CFL is the second most commonly injured ankle ligament, occurring either in conjunction with an ATFL injury or specifically due to dorsiflexion and inversion of the foot.[7] The pain of a lateral ankle sprain is generally not subtle, but is highly variable; only an estimated 50% of lateral ankle sprains prompt individuals to seek medical care in the acute or subacute setting.[8]

Presentation of ankle sprains can vary greatly based on severity. In the acute setting, pain and swelling can limit exam findings, and a delayed physical exam performed 4–5 days after injury has been demonstrated to have the high sensitivity (96%) and specificity (84%).[9] ATFL laxity can be assessed by the anterior drawer test of the ankle, while the

talar tilt test is useful for identifying CFL instability. The anterolateral drawer test, which allows for internal rotation of the ankle while testing, has seen growing interest due to evidence suggesting superiority over the conventional anterior drawer test, particularly in patients lacking medial-sided injury. Grading of a lateral ankle sprain is performed clinically, with the injury determined to be grade I (minimal bruising/swelling, normal weight bearing), II (moderate bruising/swelling), or III (severe bruising/swelling, substantial pain with weight bearing). Grade I sprains result from stretches or a slight tear in the ankle ligament, with the ankle still stable on examination. Grade II injuries suggest an incomplete tear in the ankle ligaments, producing mild ankle instability, while a grade III sprain occurs with complete tear of ankle ligaments with the ankle markedly unstable.[7] Treatment of ankle sprains is predominantly conservative, with the RICE-principle (rest, ice, compression, elevation) a mainstay of initial management, though the efficacy of RICE is not well established in the literature. Given the volume of these injuries and the potential for chronic sequelae, there exists a plethora of literature examining different treatment modalities and therapeutic options: no benefits have been seen with the use of manual mobilization, electrotherapy, laser therapy, or ultrasound therapy.[7,10] Research suggests that immobilization for a short period via a cast or boot can be advantageous in the management of grade III injuries, but immobilization was less beneficial than functional movement in lower grade strains. Evidence strongly supports a rehabilitation program that implements progressive weight bearing following an acute ankle sprain, with a focus on early active range of motion movement, neuromuscular exercises, and proprioceptive training.[11,12] The ultimate goal of therapy following acute injury is prevention of chronic ankle instability, which describes any persistent symptoms and injury recurrence that may occur.[11] High quality, supervised exercise programs and ankle bracing, particularly during sports, have been repeatedly shown in large reviews to be effective in reducing the risk of chronic instability. While acute ankle sprains can be well managed in the primary care setting, specialist referral and potential operative management is generally reserved for chronic, recurrent, refractory symptoms. Acute repair of single instance high grade tears is rarely performed, even in elite athletes.[12]

High ankle sprains, or syndesmotic injuries, account for up to 20% of ankle sprains, and can occur independently or in association with ankle fractures.[13] The distal tibiofibular syndesmosis is responsible for maintaining the connection between the distal tibia and fibula, allowing for fibular rotation and translation during movement, and is comprised of multiple ligaments including the anterior-inferior tibiofibular ligament (AITFL) and posterior-inferior tibiofibular ligament (PITFL), amongst others.[7] In the event of a forceful external rotation of the foot with the ankle in dorsiflexion, the distal fibula can separate from the tibia and tear the ligaments connecting them, starting with the AITFL. Patients may present with more severe pain than a typical lateral ankle sprain that can be localized more proximally to the syndesmosis or anterolateral ankle. A positive squeeze test, in which squeezing the tibia and fibula together at the mid-calf level elicits syndesmosis pain distally, is a highly specific finding (85% specificity).[14] Suspected syndesmotic injuries often warrant advanced imaging for potential associated fractures (CT) or associated ligamentous injury or osteochondral lesions (MRI), and high ankle sprains can be similarly graded based on the degree of ligamentous injury. Syndesmotic injuries can be managed in the primary care setting, with severe injury or associated fractures warranting specialist consult. Following an acute syndesmotic injury, conservative management is recommended for stable injuries and is overall similar to low ankle sprains after a period of immobilization, frequently including 3 weeks of non-weight bearing, a below-the-knee cast or brace, RICE, and physical therapy with an emphasis on proprioceptive exercises. Patients managed conservatively demonstrate excellent rates of return to activity, albeit with a longer recovery period than after low ankle sprains. Grade III injuries predominantly warrant surgical fixation to correct instability. Syndesmotic screws and suture-button devices have each have demonstrated comparable efficacy, with the latter shown to be associated with faster return to work and lower rates of hardware removal.[15] Partial weight bearing and physical therapy progression is allowed 6 weeks after surgery, and even elite athletes demonstrate a high rate of return to play.[7]

Achilles Tendon Rupture

Rupture of the Achilles tendon, which connects both the gastrocnemius and soleus muscles to the calcaneus of the foot, is one of the most common sporting injuries with a rate of injury up to 12 per 100,000 individuals reported in the literature, predominantly in males in the fourth to fifth decade of life.[16] Physical activity involving explosive eccentric contractions of the lower extremity with a push off of a weight-bearing foot with an extended knee implicated in over half of rupture injuries.[17] Patients often report a popping sensation or a feeling of a blow to the calf. On physical exam, a palpable defect may be noted 2 to 6 centimeters from the calcaneal insertion site (**Figures 1 A,B**). Additionally, a positive Thompson test, in which squeezing of the calf musculature of a prone patient fails to generate passive plantar flexion, suggests a total rupture of the tendon.[3] Achilles tendon rupture warrants a specialist referral, though management of an acute rupture is controversial and can vary by physician and patient. A 2017 meta-analysis by Deng et al. found a significantly lower re-rupture rate in surgically managed patients, but no difference in return to sport, range of motion, or subsequent physical activity.[18] Conservative management, which frequently involves immobilization with gradual decreased heel lifting and progressive physical

Figure 1. Common sites of respective pain during examination of the (**A**) anterior and (**B**) posterior ankle

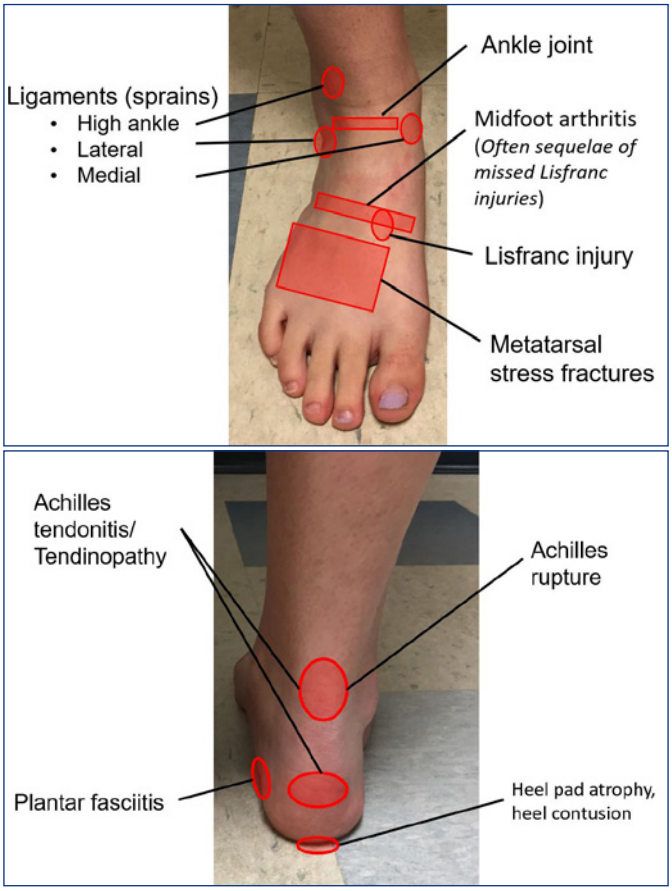

Figure 2. Oblique foot radiograph demonstrating 5th metatarsal fracture involving Zone 2 (Jones Fracture, red arrow).

therapy, has lower rates of complications, particularly infections and venous thromboembolism.[19] With each treatment modality possessing its own respective risk profiles, operative versus non-operative management is often based on physician and patient preference.

FOOT

Fractures

Jones fractures are common injuries amongst high-level athletes, with increased attention being paid towards diagnosis and management of the condition across all active individuals. A majority of fractures to the 5th metatarsal bone of the foot occur in the tuberosity of the metatarsal base, or zone 1. Jones fractures occur at the metaphyseal-diaphyseal junction of the 5th metatarsal where the 4th and 5th metatarsal bones articulate. This vascular watershed area, zone 2, is predisposed to disruption of local blood flow following a fracture, as well as being an area of mechanical stress, contributing to high rates of nonunion (20%–30% nonunion rate) after injury.[20] Zone 1 fractures, in contrast, have almost a 99% union rate and very rarely require operative intervention. Patients often report an acute episode of lateral foot pain that persists, most notable when attempting to pivot or cut on the affected foot, that can be localized to the fifth metatarsal. Standard radiographic imaging is crucial for diagnosis, and often provides sufficient information for classification (**Figure 2**). Management of Jones fractures continues to evolve: in recreational athletes, non-operative treatment using a short leg cast or boot for 6–8 weeks may be sufficient, though refracture rates may be as high as 30% and 70%.[21] Operative treatment with intramedullary screw fixation reduces rates of nonunion and can improve return to activity time, and is therefore considered for higher demand athletes.

Metatarsal stress fractures encompass 10% of all stress fractures in active patients, and have been associated with footwear type, playing turf, and repetitive physical activity.[3,22,23] Colloquially known as "march fractures", they were first recognized as the source of foot pain in soldiers on lengthy marches. Metatarsal stress fractures occur in recreational and elite athletes alike, frequently following an increase in activity intensity.[22] Stress injuries, while fractures, are overuse injuries that occur when microtrauma accumulation at the bone exceeds the rate of bone remodeling, with the second, third, and fifth metatarsal shafts the most common sites of stress fractures in the foot. Presentation often involved gradual, persistent foot pain that can intensify with activity. As early phase stress fractures can be difficult to visualize on X-ray unless they progress to displacement, MRI is the gold standard for early diagnosis with bone scan an alternative option, although clinical suspicion

and absence of other radiographic findings can be sufficient for diagnosis. Radiographs several weeks after symptoms have started often reveal callus formation, which is also diagnostic. Stress fractures are generally managed conservatively via activity modification with the possible addition of a walking boot, with healing expected in 6–8 weeks.[24]

OVERUSE

While certainly less severe than a rupture, both insertional and noninsertional **tendinopathy of the Achilles tendon** can be a common cause of disability given the tendon's crucial role in most activities. The rate of Achilles tendinopathy has risen 10-fold over the past three decades with a suspected connection to a rise of recreational sporting activities.[25] The pathology of tendinopathy is complex and our understanding has evolved significantly; Longo et al. defines tendinopathy as "a failed healing response" in which collagen fibers are disrupted and are replaced haphazardly or by noncollagenous fibrous tissue.[26] Excessive loading of tendons during intense physical activity is considered the predominant stimulus for tendinopathy, but there exists a complex, multifactorial relationship with variables including age, vascular supply, metalloprotease presence, gait, ankle stability, training patterns, and exercise environment.[26] Tendinopathy pain was previously conflated with inflammation ("tendonitis"), but histological examination demonstrates minimal evidence of inflammation. Physical exam is the gold standard for diagnosis with pain along the Achilles tendon observed (particularly in dorsiflexion), sometimes with palpable thickening or nodules, but evidence of tendinopathy can also be visualized on MRI (**Figure 3**). Common Achilles tendinopathy can be managed in the primary care setting though it can prove particularly recalcitrant, with many treatment modalities more conventional than well validated in the literature. NSAIDs and cryotherapy can provide symptomatic relief, with limited evidence of long-term effectiveness. Eccentric calf muscle training has shown the most promising results in treating chronic tendinopathy as part of physical therapy, while steroid injections are avoided due to risks of rupture.[27] Regardless of treatment, up to 45% of patients will remain symptomatic after 6 months of conservative therapy, at which time surgical treatment can be considered. Operative treatments include debridement of the tendon with or without calcaneal bony prominence resection, suture anchor repair of the tendon, or tendon transfer (typically the flexor hallucis longus).[27] Surgical management is successful in producing good to excellent results in 85% of cases, but patients must be counseled on the possibility of reoccurrence or unsatisfactory surgical outcomes.[26,27]

Figure 3. Sagittal magnetic resonance imaging (MRI) of Achilles insertional tendinopathy, displaying increased interstitial fluid/signal in the distal Achilles with bone edema at the insertion (red arrow).

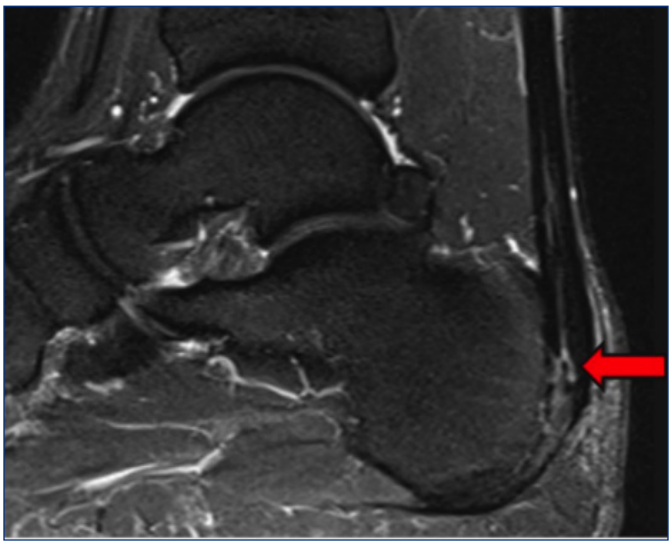

Plantar fasciitis represents an estimated 11–15% of foot-related complaints in adults and is a common cause of frustration and activity limitations.[28] The plantar fascia, the layer of connective tissue across the sole of the foot, originates at the plantar surface of the calcaneus and plays an important role in arch support. In plantar fasciitis, the accumulation of microtears following chronic overuse creates a cycle of inflammation predominantly at the aponeurosis of the fascial origin, resulting in insidious, persistent pain that worsens with activity initiation or upon standing in the morning.[29] Weekend warrior athletes are at particular risk, as sudden repetitive stress to an unconditioned fascia is the quintessential situation for precipitating plantar fasciitis.[3] Though the condition can prove frustratingly persistent, long-term prognosis is very favorable with over 80% of patients experiencing resolution in less than 12 months, and specialist referral often only warranted for chronic or debilitating symptoms.[30] Diagnosis of plantar fasciitis can often be made by the pattern of pain reported in the patient's history with a physical exam helping to exclude other causes of heel pain. Imaging can be helpful to exclude other causes of heel pain such as calcaneal stress fracture, subtalar arthritis, or Achilles insertional tendinopathy. First-line treatment modalities are often undertaken simultaneously, and as such there exists conflicting or absent evidence in the literature regarding their individual efficacy. Stretching, NSAID use, and supportive shoe inserts have all demonstrated some degree of symptomatic improvement, with fascial stretching favored over Achilles stretching.[31,32] Night splints to assist in gentle stretching of the plantar fascia have anecdotal support and can serve as an additional treatment modality, though evidence in support of their efficacy is lacking. Plantar injections, especially repetitive, are primarily avoided due to the risk of fat pad atrophy, and surgical plantar release is reserved for severely refractory cases and is rarely necessary.

CONCLUSION

Weekend warriors are recreational athletes who compress their physical activity into 1–2 weekly intervals, combining general deconditioning with a rapid increase in excessive activity to create a classic environment for numerous foot and ankle injuries. Recognizing these common injuries in this subset of patients can help with efficient and accurate diagnosis and management.

References

1. O'Donovan G, Sarmiento OL, Hamer M. The Rise of the "Weekend Warrior." *J Orthop Sports Phys Ther*. 2018;48(8):604-606. doi:10.2519/jospt.2018.0611
2. Wise J. Exercising as "weekend warrior" still yields mortality benefit, study finds. *BMJ*. 2017;356:j126. doi:10.1136/bmj.j126
3. Simons SM. Foot injuries of the recreational athlete. *Phys Sportsmed*. 1999;27(1):57-70. doi:10.3810/psm.1999.01.649
4. van Oeveren BT, de Ruiter CJ, Beek PJ, van Dieën JH. The biomechanics of running and running styles: a synthesis. *Sports Biomech*. Published online March 4, 2021:1-39. doi:10.1080/14763141.2021.1873411
5. Fong DT-P, Hong Y, Chan L-K, Yung PS-H, Chan K-M. A systematic review on ankle injury and ankle sprain in sports. *Sports Med Auckl NZ*. 2007;37(1):73-94. doi:10.2165/00007256-200737010-00006
6. Tassignon B, Verschueren J, Delahunt E, et al. Criteria-Based Return to Sport Decision-Making Following Lateral Ankle Sprain Injury: a Systematic Review and Narrative Synthesis. *Sports Med Auckl NZ*. 2019;49(4):601-619. doi:10.1007/s40279-019-01071-3
7. D'Hooghe P, Alkhelaifi K, Abdelatif N, Kaux JF. From "Low" to "High" Athletic Ankle Sprains: A Comprehensive Review. *Oper Tech Orthop*. 2018;28(2):54-60. doi:10.1053/j.oto.2018.01.002
8. Verhagen EA, van Mechelen W, de Vente W. The effect of preventive measures on the incidence of ankle sprains. *Clin J Sport Med Off J Can Acad Sport Med*. 2000;10(4):291-296. doi:10.1097/00042752-200010000-00012
9. van Dijk CN, Lim LS, Bossuyt PM, Marti RK. Physical examination is sufficient for the diagnosis of sprained ankles. *J Bone Joint Surg Br*. 1996;78(6):958-962. doi:10.1302/0301-620x78b6.1283
10. Kerkhoffs GM, van den Bekerom M, Elders LAM, et al. Diagnosis, treatment and prevention of ankle sprains: an evidence-based clinical guideline. *Br J Sports Med*. 2012;46(12):854-860. doi:10.1136/bjsports-2011-090490
11. Doherty C, Delahunt E, Caulfield B, Hertel J, Ryan J, Bleakley C. The incidence and prevalence of ankle sprain injury: a systematic review and meta-analysis of prospective epidemiological studies. *Sports Med Auckl NZ*. 2014;44(1):123-140. doi:10.1007/s40279-013-0102-5
12. Doherty C, Bleakley C, Delahunt E, Holden S. Treatment and prevention of acute and recurrent ankle sprain: an overview of systematic reviews with meta-analysis. *Br J Sports Med*. 2017;51(2):113-125. doi:10.1136/bjsports-2016-096178
13. Roemer FW, Jomaah N, Niu J, et al. Ligamentous Injuries and the Risk of Associated Tissue Damage in Acute Ankle Sprains in Athletes: A Cross-sectional MRI Study. *Am J Sports Med*. 2014;42(7):1549-1557. doi:10.1177/0363546514529643
14. Netterström-Wedin F, Bleakley C. Diagnostic accuracy of clinical tests assessing ligamentous injury of the ankle syndesmosis: A systematic review with meta-analysis. *Phys Ther Sport Off J Assoc Chart Physiother Sports Med*. 2021;49:214-226. doi:10.1016/j.ptsp.2021.03.005
15. Schepers T. Acute distal tibiofibular syndesmosis injury: a systematic review of suture-button versus syndesmotic screw repair. *Int Orthop*. 2012;36(6):1199-1206. doi:10.1007/s00264-012-1500-2
16. Hess GW. Achilles tendon rupture: a review of etiology, population, anatomy, risk factors, and injury prevention. *Foot Ankle Spec*. 2010;3(1):29-32. doi:10.1177/1938640009355191
17. Chiodo CP, Wilson MG. Current concepts review: acute ruptures of the achilles tendon. *Foot Ankle Int*. 2006;27(4):305-313. doi:10.1177/107110070602700415
18. Deng S, Sun Z, Zhang C, Chen G, Li J. Surgical Treatment Versus Conservative Management for Acute Achilles Tendon Rupture: A Systematic Review and Meta-Analysis of Randomized Controlled Trials. *J Foot Ankle Surg Off Publ Am Coll Foot Ankle Surg*. 2017;56(6):1236-1243. doi:10.1053/j.jfas.2017.05.036
19. Seow D, Yasui Y, Calder JDF, Kennedy JG, Pearce CJ. Treatment of Acute Achilles Tendon Ruptures: A Systematic Review and Meta-analysis of Complication Rates With Best- and Worst-Case Analyses for Rerupture Rates. *Am J Sports Med*. Published online March 30, 2021:363546521998284. doi:10.1177/0363546521998284
20. Smith JW, Arnoczky SP, Hersh A. The intraosseous blood supply of the fifth metatarsal: implications for proximal fracture healing. *Foot Ankle*. 1992;13(3):143-152. doi:10.1177/107110079201300306
21. Porter DA. Fifth Metatarsal Jones Fractures in the Athlete. *Foot Ankle Int*. 2018;39(2):250-258. doi:10.1177/1071100717741856
22. Iwamoto J, Takeda T. Stress fractures in athletes: review of 196 cases. *J Orthop Sci Off J Jpn Orthop Assoc*. 2003;8(3):273-278. doi:10.1007/s10776-002-0632-5
23. Koo AY, Tolson DR. March Fracture. In: *StatPearls*. StatPearls Publishing; 2021. Accessed May 12, 2021. http://www.ncbi.nlm.nih.gov/books/NBK532289/
24. Troy KL, Davis IS, Tenforde AS. A Narrative Review of Metatarsal Bone Stress Injury in Athletic Populations: Etiology, Biomechanics, and Management. *PM R*. Published online November 6, 2020. doi:10.1002/pmrj.12518
25. Ames PRJ, Longo UG, Denaro V, Maffulli N. Achilles tendon problems: not just an orthopaedic issue. *Disabil Rehabil*. 2008;30(20-22):1646-1650. doi:10.1080/09638280701785882
26. Longo UG, Ronga M, Maffulli N. Achilles Tendinopathy. *Sports Med Arthrosc Rev*. 2018;26(1):16-30. doi:10.1097/JSA.0000000000000185
27. Maffulli N, Longo UG, Kadakia A, Spiezia F. Achilles tendinopathy. *Foot Ankle Surg Off J Eur Soc Foot Ankle Surg*. 2020;26(3):240-249. doi:10.1016/j.fas.2019.03.009
28. Pfeffer G, Bacchetti P, Deland J, et al. Comparison of custom and prefabricated orthoses in the initial treatment of proximal plantar fasciitis. *Foot Ankle Int*. 1999;20(4):214-221. doi:10.1177/107110079902000402
29. Buchbinder R. Clinical practice. Plantar fasciitis. *N Engl J Med*. 2004;350(21):2159-2166. doi:10.1056/NEJMcp032745
30. Lapidus PW, Guidotti FP. PAINFUL HEEL: REPORT OF 323 PATIENTS WITH 364 PAINFUL HEELS. *Clin Orthop*. 1965;39:178-186.
31. DiGiovanni BF, Nawoczenski DA, Lintal ME, et al. Tissue-specific plantar fascia-stretching exercise enhances outcomes in patients with chronic heel pain. A prospective, randomized study. *J Bone Joint Surg Am*. 2003;85(7):1270-1277. doi:10.2106/00004623-200307000-00013
32. Wolgin M, Cook C, Graham C, Mauldin D. Conservative treatment of plantar heel pain: long-term follow-up. *Foot Ankle Int*. 1994;15(3):97-102. doi:10.1177/107110079401500303

Authors

Davis A. Hartnett, BS, MD'22; Warren Alpert Medical School of Brown University, Providence, RI.

Devin F. Walsh, MD, Department of Orthopaedic Surgery, Warren Alpert Medical School of Brown University, Providence, RI.

David R. Richardson, MD, Department of Orthopaedic Surgery & Biomedical Engineering, University of Tennessee-Campbell Clinic, Memphis, TN.

Raymond Y. Hsu, MD, Department of Orthopaedic Surgery, Warren Alpert Medical School of Brown University, Providence, RI.

Disclosures: None

Correspondence

Davis A. Hartnett, BS, MD'22

Brown University, Box G-9014, Providence, RI 02912

davis_hartnett@brown.edu