Spontaneous Pneumomediastinum in a Healthy 25-Year-Old Male

JULIE WOODSIDE, PA-C; RICHARD V. MORGERA, MD

CASE PRESENTATION

A 25-year-old man with no significant past medical history presented to an urgent care clinic with four days of an abnormal sensation of throat and neck swelling ("as if I had been punched in the throat"), chest pain, pain with deep inspiraton, fatigue, and a feeling of generalized anxiety. The symptoms appeared worsened at night when recumbent. The patient denied fever, chills, cough, headache or heart palpitations. He denied exposure to COVID-19, but had a PCR test the day prior with results pending at time of presentation. The patient denied any recent trauma. He reported occasional alcohol and marijuana use but denied tobacco use.

Physical examination showed a well appearing, well-groomed, anxious young male in no acute respiratory distress. Oxygen saturation was 98% on room air and the patient was afebrile. Pulse was 110 bpm, and blood pressure was 128/84 mm Hg. HEENT exam revealed the posterior pharynx to be clear with no oral swelling. The neck was without lymphadenopathy. Palpation of the thyroid did not show enlargement, but crepitations around the anterior neck and supraclavicular region were present, consistent with subcutaneous emphysema. Lung sounds were clear. The remainder of the patient's exam was within normal limits.

Radiographic imaging was obtained including chest and neck soft tissue views. Chest X-ray (**Figures 1A, 1B**) showed free air tracking up towards the cervical region, concerning for pneumomediastinum. Neck views (**Figures 2A, 2B),** showed extensive gas throughout the soft tissues of the anterior neck. Additional history revealed that the patient smoked marijuana four days prior and often "rips from the bong" with deep inspirations. EKG was obtained with normal findings. The underlying etiology of his pneumomediastinum was speculated to be his recent marijuana smoking as described previously. The patient was transferred to the emergency department and was offered admission to the hospital, but he declined. He was given strict instructions to not smoke, avoid flying, diving, hiking and Valsalva maneuvers. Return precautions were discussed. He was instructed to follow up in one week with a chest X-ray and to establish care with a PCP.

Patient did return for a chest X-ray one week later showing resolution of the pneumomediastinum. (**Figures 3A, 3B**).

Figures 1A, 1B. Chest X-rays showing subcutaneous emphysema, pneumomediastinum

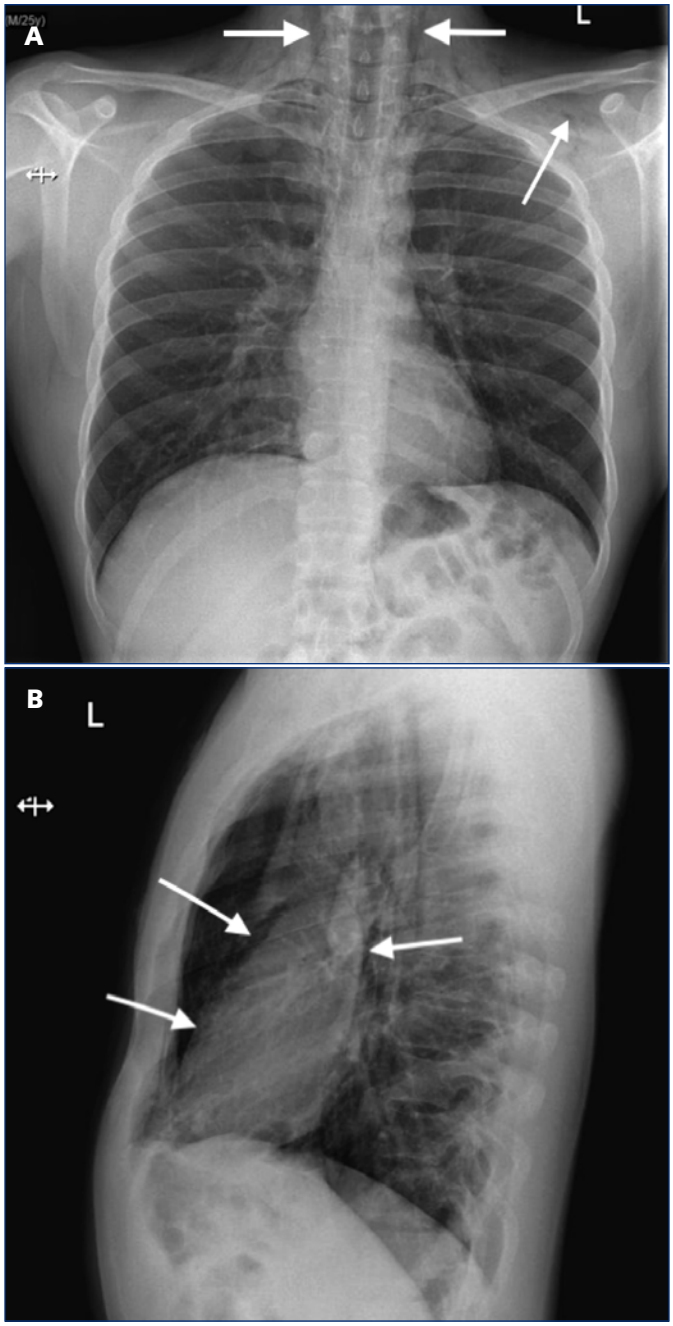

Figures 2A, 2B. Neck X-rays (AP, Lateral) showing subcutaneous emphysema

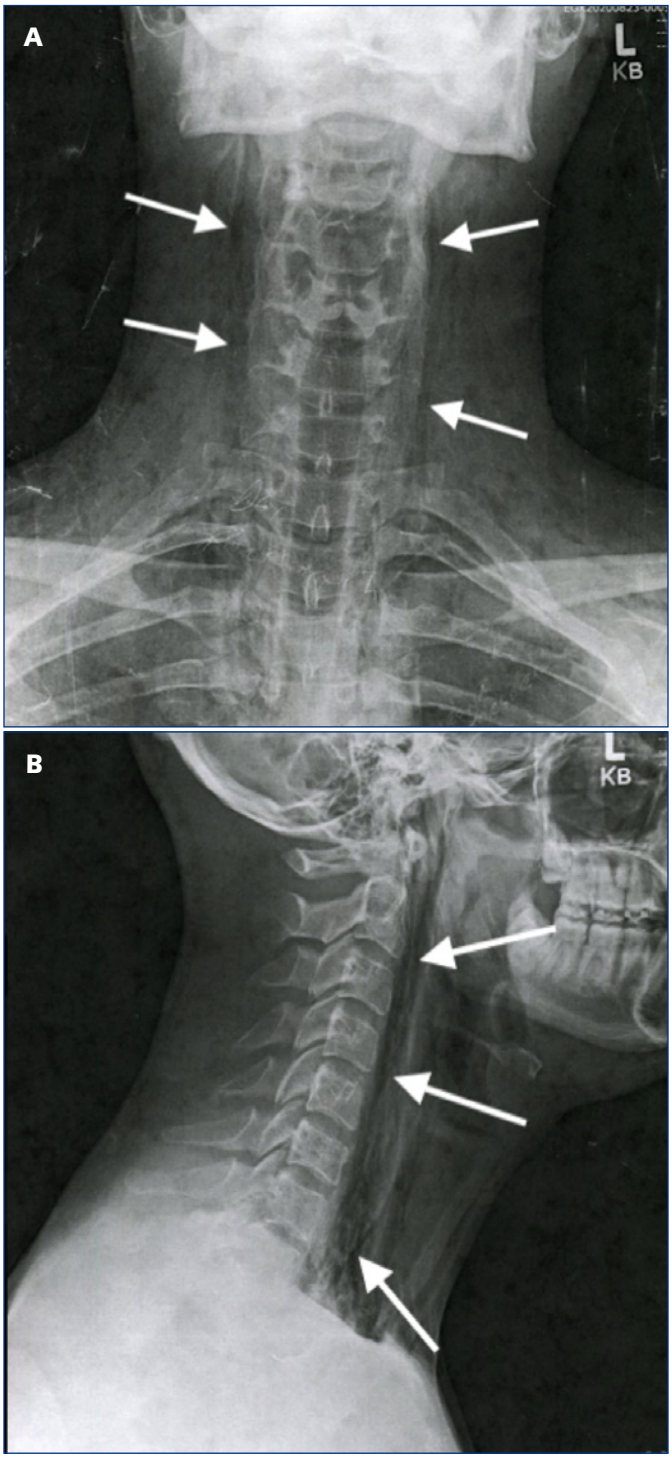

Figures 3A, 3B. Chest X-rays one week after ED visit showing resolution of pneumomediastinum

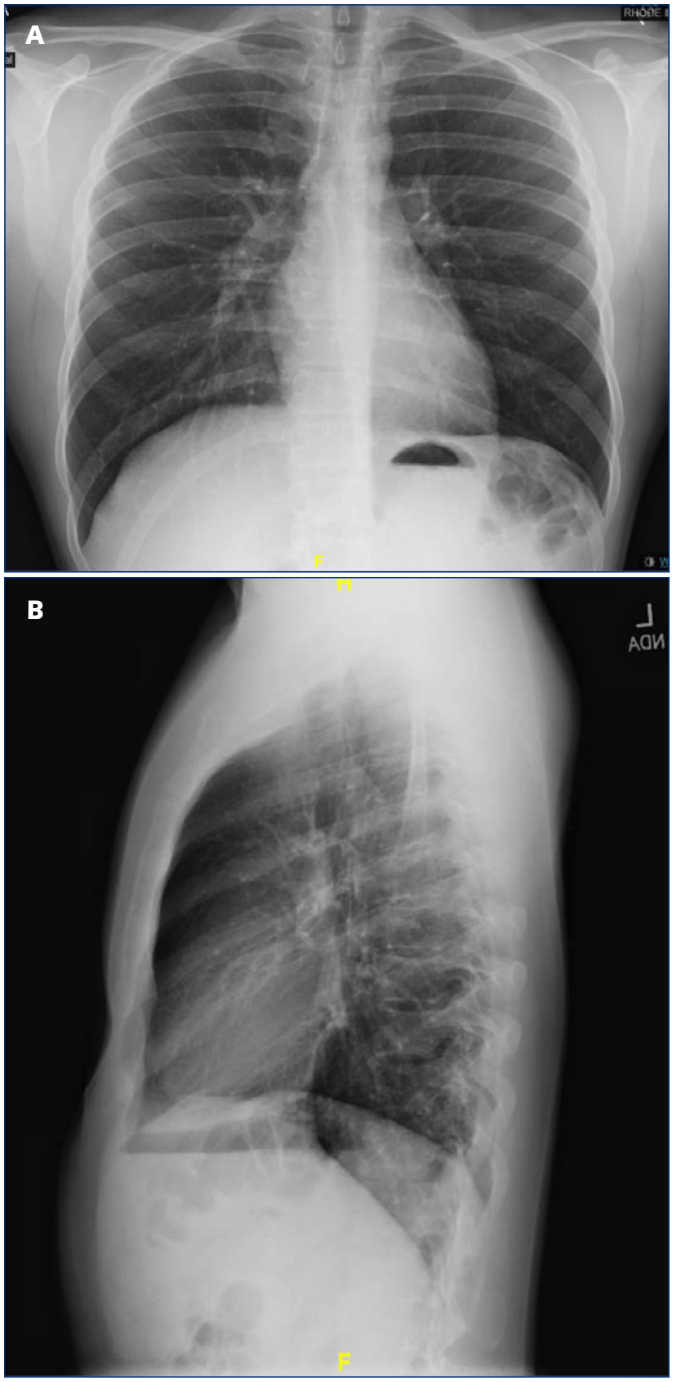

DISCUSSION

Spontaneous pneumomediastinum (SPM) is an uncommon problem, primarily seen in young men, and defined as the presence of free air in the mediastinum in the absence of trauma, recent surgical procedure, mechanical ventilation or obvious inciting factor. SPM can be caused by asthma exacerbation, sporting events, Valsalva maneuvers, emesis, smoking, vaping, excessive coughing, and drug use. It can also occur in pregnant women as a result of/or during labor.[1] The triad of symptoms that young males generally present with include dyspnea, chest pain and subcutaneous emphysema. Pneumomediastinum was first described by Laennec in 1819, describing the condition as a result of trauma, and Hamman reported atraumatic spontaneous pneumomediastinum over a century later. SPM in the setting of marijuana use was first described in 1972.[2]

In this case, it was suspected the patient's spontaneous pneumomediastinum occurred due to barotrauma while smoking marijuana; in particular, taking deep inspirations from a bong followed by breath holding. The act of deep inspiration followed by a forced apnea resulting in a closed glottis after each inhalation and/or inhalation through a high-resistance smoking apparatus are both thought to produce a decrease in intrathoracic pressure, an increase in the intra-alveolar air volume causing rupture of the alveoli and dissection of the air from the pulmonary interstitium to the mediastinum, neck, and, at times, the pericardium(the Macklin effect).[1,3,4] Pneumothorax can occur at times if the intrathoracic pressure fails to fully decompress from the air dissecting into the subcutaneous tissue. Secondary pneumomediastinum, on the other hand, occurs as a result of trauma (blunt/penetrating), head and neck surgical procedures or mechanical ventilation.

A thorough physical exam, a high index of suspicion and radiologic imaging are crucial in diagnosing SPM. X-ray often confirms the presence of subcutaneous emphysema, but a CT Scan may be needed in equivocal plain x-ray findings, to identify underlying pulmonary pathology and to exclude pneumopericardium. Acute myocardial infarction, pulmonary embolism, cardiac tamponade, aortic dissection, Boerhaave syndrome, and other critical diagnoses with similar presenting symptoms must be ruled out.

Treatment of SPM is conservative including pain control, avoiding excessive physical and aggravating activities, and the administration of oxygen (in some cases) to increase gas absorption and hasten resolution.[5] In most cases resolution of symptoms is noted within a few days, but follow up including repeat radiographs are indicated. Risk of recurrence is very low.

References

1. Weiss ZF, Gore S, Foderaro A. Pneumomediastinum in marijuana users: a retrospective review of 14 cases. *BMJ Open Resp Res*. 2019;6:e000391. doi:10.1136/bmjresp-2018-000391.
2. Koullias GJ, Korkolis DP, Wang XJ, Hammond GL. Current assessment and management of spontaneous pneumomediastinum: experience in 24 adult patients. *Eur J Cardiothorac Surg*. 2004 May. 25:852-855. https://doi.org/10.1016/j.ejcts.2004.01.042.
3. Hazouard E, Koninck JC, Attucci S, Fauchier-Rolland F, Brunereau L, Diot P. Pneumorachis and pneumomediastinum caused by repeated Müller's maneuvers: complications of marijuana smoking. *Ann Emerg Med*. December 2001;38:694- 697. https://doi.org/10.1067/mem.2001.118016.
4. Rajendran T, Shaikh O, Kumbhar U, Balasubramanian G, Bhattarai S. Spontaneous pneumomediastinum in a young adult: a rare presentation. *Cureus*. 2020 May;12(5):e8306. doi:10.7759/cureus.8306.
5. Takada K, Matsumoto S, Hiramatsu T, Kojima E, Shizu M, Okachi S, Ninomiya K, Morioka H. Spontaneous pneumomediastinum: an algorithm for diagnosis and management. *Ther Adv Respir Dis*. 2009 Dec;3(6):301-307. doi:10.1177/1753465809350888.

Authors

Julie Woodside, PA-C, South County Hospital Express Care, Department of Emergency Medicine, Lifespan Physician Group, Newport Orthopedics.

Richard V. Morgera, MD, South County Hospital Express Care, Department of Emergency Medicine, Clinical Assistant Professor. Alpert Medical School of Brown University, Providence, RI.

Disclosures

The authors have none to declare.

Correspondence

Julie Woodside, PA-C
Newport Orthopedics
19 Friendship Street, Suite 130
Newport, RI 02840
401-845-1474
woodside.julie@gmail.com