

# Diagnosis and Management of Meniscal Injury

JACOB BABU, MD, MHA; ROBERT M. SHALVOY, MD; STEVE B. BEHRENS, MD

## ABSTRACT

Meniscal injury is a common cause for presentation to the emergency department or primary care physician's office. Meniscal injuries can be the result of a forceful, twisting event in a young athlete's knee or it can insidiously present in the older patient. Many patients with meniscal pathology appropriately undergo conservative management with a primary care physician while some may need referral to an orthopedist for operative intervention. Arthroscopic surgery to address the menisci is the most frequently performed procedure on the knee and one of the most regularly performed surgeries in orthopedic surgery.<sup>1</sup> The purpose of this paper is to help elucidate the diagnosis and management of meniscal pathology resulting in knee pain.

**KEYWORDS:** meniscal injury, knee pain, osteoarthritis, arthroscopy, orthopedic referral

## INTRODUCTION

The frequency in which meniscal tears occur makes it an important injury to identify by the medical practitioner. Acute, traumatic tears in the young patient and atraumatic, degenerative tears in the older patient represent a continuum of pathology, often presenting with their own difficulties in diagnosis and management. The prevalence of meniscal tears in the general population has been challenging to identify due to the high frequency of asymptomatic or undiagnosed lesions. In some Northern European countries, the estimated incidence of meniscal tears is 2 per 1000 person-years.<sup>2</sup> A study by Englund et al., focusing on degenerative tears, found that 35% of enrolled patients older than 50 years old had imaging evidence of a meniscal tear, with 2/3 of these being asymptomatic.<sup>3</sup> Risk factors associated with the development of a symptomatic meniscal tear have been identified to be a BMI > 25 kg/m<sup>2</sup>, male sex, and occupations requiring kneeling, squatting or stair-climbing.<sup>2-4</sup> A military study looking at more acute, traumatic meniscal tears estimated the incidence in active duty personnel to be 8.27 per 1000 person-years.<sup>5</sup> In this study, age was found to be a variable associated with elevated rates of injury, with tears occurring 4 times as often in those over 40 compared to those less than 20 years of age.<sup>5</sup> Arthroscopic meniscectomy is estimated to occur 400,000-700,000 times annually.<sup>1,6</sup>

## PRESENTATION

Knee pain can be the result of numerous possible intra- and extra-articular diagnoses, all of which must be kept in the differential when evaluating a patient. Meniscal tears can be identified by asking a few focused questions during the patient evaluation. The mechanism of injury is important as are the presence of specific symptoms after injury.

Acute meniscal tears are most often associated with a twisting mechanism to the knee while the foot is planted, providing an axial load. The joint swelling with a meniscus tear is more likely to present in a delayed fashion (> 24 hours).

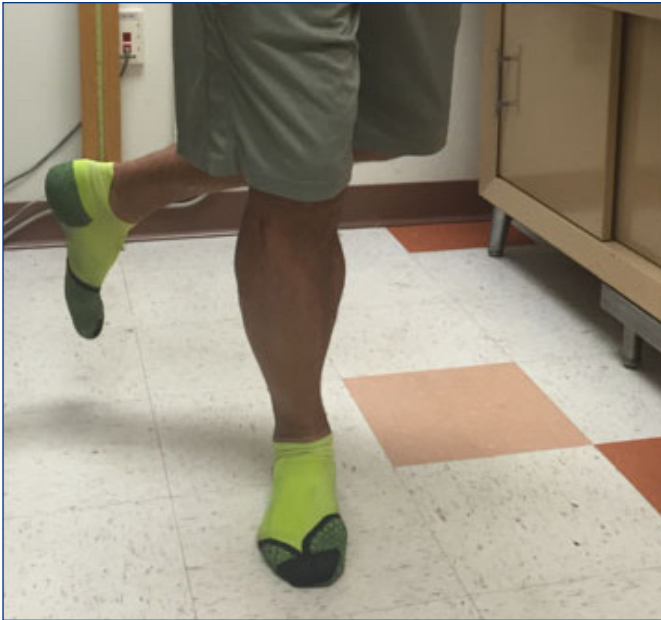Atraumatic, degenerative meniscal pathology more frequently presents with an insidious onset of pain. This diagnosis can be difficult to distinguish from osteoarthritis in the older patient. Mechanical symptoms are relatively common, with patients often describing the sensation of 'locking,' 'clicking,' 'popping,' and sometimes even a feeling of 'giving way' of the knee. Symptoms tend to wax and wane with activity levels.

On physical examination, joint line tenderness is often described as the most sensitive finding for diagnosing a meniscal tear; however, it is not very specific.<sup>7</sup> Blocks to active and passive range of motion, especially to deep flexion, are associated with more complex meniscal tears. A few provocative examination maneuvers for meniscal pain include the Apley Compression, McMurray, Steinman and Thessaly tests, demonstrated in **Figures 1** and **2**.<sup>7,8</sup> The basic premise of these tests involves applying an axial force through the knee joint to simulate weight-bearing while providing a rotational moment about the leg to try to elicit clicking, popping or pain. Kocabey et al. evaluated the effectiveness of various physical examination maneuvers in diagnosing meniscal pathology and found the combination of joint line tenderness, positive McMurray, Steinmann and Apley tests to have an 80% sensitivity for medial meniscal pathology and a 92% sensitivity for lateral meniscal pathology.<sup>8</sup>

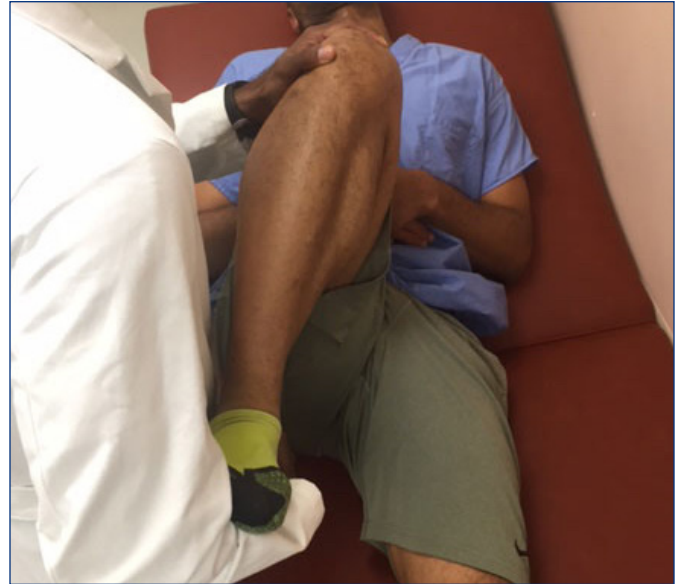## ANATOMY

The menisci are fibrocartilaginous structures which importantly serve as load-sharing components of the knee joint. By increasing the surface area of contact between the femur and tibia, they can significantly decrease contact stresses experienced by articular cartilage. Menisci also function as secondary restraints to anterior/posterior translation of

**Figure 1.** The Thessaly test consists of internal and external rotation of the body with the knee flexed at 5 and 20 degrees. The examiner can offer assistance by holding the patient's hands for stabilization. Reproduction of symptoms/pain is a positive finding.



**Figure 2.** The McMurray Test is performed with the patient in the supine position. The examiner places one hand on the heel, which will provide internal and external rotation moments on the tibia. The other hand is free to palpate the medial/lateral knee joint line and serve as a lever for valgus/varus forces. Reproduction of pain or 'clicking' is considered positive.



the tibia with the primary restraint being provided by the cruciate ligaments. The menisci are triangular in cross-section, and predominantly comprised of water, proteoglycans and Type 1 collagen.<sup>6</sup> The medial meniscus is c-shaped with multiple capsular attachments including the medial collateral ligament, making it much less mobile than the lateral meniscus which is more circular and devoid of ligamentous constraint. This disparity in motion contributes to the frequency in which each meniscus is injured. The medial meniscus is injured much more often than the lateral meniscus, with the posterior horn being the most afflicted component. The lateral meniscus is more commonly injured in association with ACL tears. In ACL-deficient knees, the menisci become increasingly important restraints to anterior translation of the tibia, predisposing it to injury. The medial and lateral inferior genicular arteries provide blood supply to the peripheral  $\frac{1}{4}$  to  $\frac{1}{3}$  of the menisci, with the remaining central portion of the meniscus receiving its nutrition via diffusion from the synovial fluid.<sup>6</sup> The poor vascularity of the central meniscus accounts for its very limited inherent capacity to heal. The menisci have been found to have nociceptor/mechanoreceptor innervation at the peripheral  $\frac{2}{3}$  and at the anterior and posterior horns from histologic study.<sup>9</sup>

## IMAGING

Plain radiographs of the knee provide little information about meniscal pathology. However, they are still valuable initial tests and provide information about bony anatomy and alignment. MRI is the most sensitive diagnostic imaging

test available, albeit with a high false positive rate. MRI is often not necessary when osteoarthritis is recognized on plain films or there is a high clinical suspicion for meniscal pathology. On MRI, a linear hyperintensity that extends to the superior or inferior joint surface is diagnostic of a meniscal tear, most sensitively identified on T1 sagittal and coronal slices.<sup>10</sup> Parameniscal cysts visualized on MRI are most often seen in the presence of meniscal tears, so images must be carefully scrutinized when cysts are present. A study performed by Zanetti et al. utilized MRI to evaluate 100 patients that had unilateral symptoms consistent with a meniscal tear.<sup>11</sup> MRIs were performed on the symptomatic and asymptomatic contralateral knee. Meniscal tears were found in 57 of the symptomatic knees and 36 of the asymptomatic knees.<sup>11</sup> Symptoms correlated most with radial, vertical and complex, displaced types of meniscal tears.<sup>11</sup> Another study showed that MRI had a sensitivity of 91.4 percent and specificity of 81.1 percent for identifying medial meniscus tears and a sensitivity and specificity of 76 and 93.3 percent, respectively, for identifying lateral-sided tears.<sup>12</sup> The management of meniscal tears is centered on the presence of symptoms; this study recognizes that a large percentage of meniscal tears are asymptomatic.

## TEAR CONFIGURATION

Vertical or longitudinal tears in the sagittal plane, as seen in **Figure 3**, are the most common type of meniscal tear and can be repaired when present in the peripheral third of the meniscus.<sup>6</sup> Radial tears are tears that initiate in the

central portion of the meniscus and propagate to the periphery; they are usually not repairable due to the poor vascularity of this area of the meniscus. When these tears are symptomatic, a partial meniscectomy is indicated. Bucket-handle tears are vertical tears with displacement that can cause mechanical blocks to flexion/extension. Flap and parrot-beak tears are tears that initiate centrally and continue in a circumferential manner.<sup>6</sup>

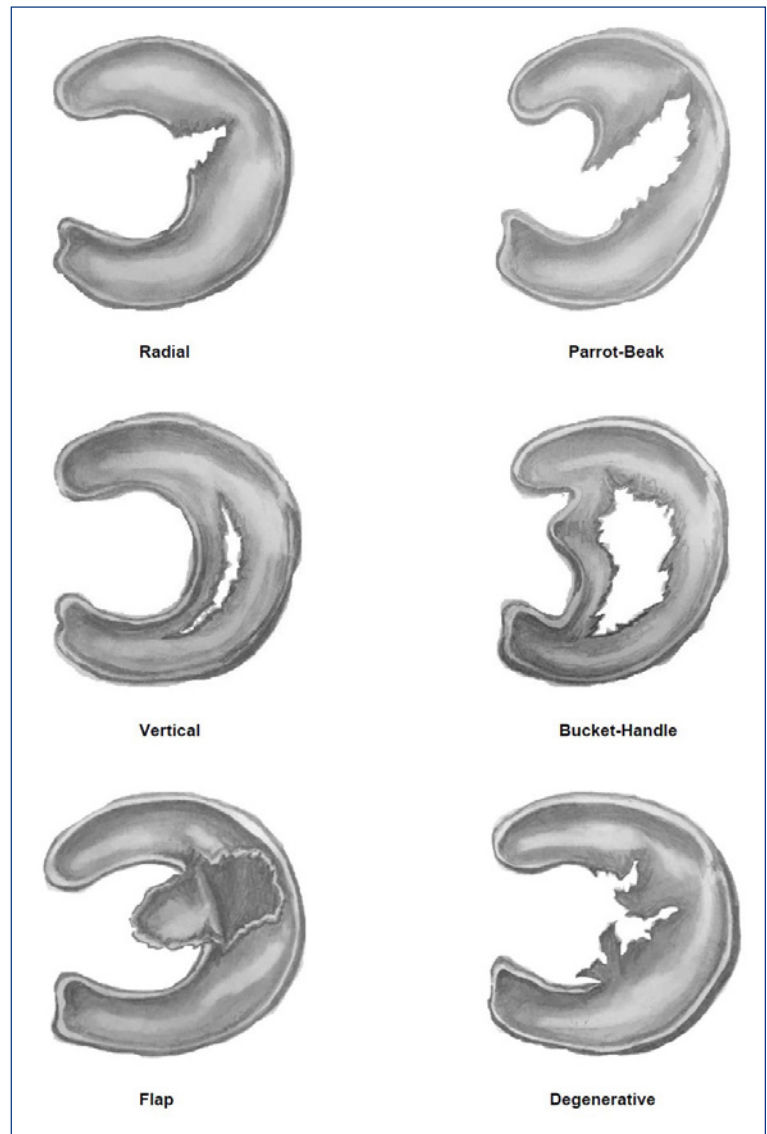
## MANAGEMENT

Meniscal tears require treatment when pain is unmanageable or function is impaired. Some meniscal tears are managed successfully without operative intervention. This is typically consistent with small radial tears and stable, nondisplaced longitudinal tears. ACL-deficient knees with no plan for ACL reconstruction and degenerative tears in patients with osteoarthritis are usually not candidates for arthroscopic treatment.<sup>6</sup> Several studies have shown good results from managing certain meniscal tears conservatively with a protocol of ice, NSAIDs, and physical therapy.<sup>13-16</sup> Physical therapy for these injuries focuses on strengthening the muscles of the injured extremity, especially surrounding the knee, as well as maintaining range of motion of the knee and hip.<sup>17-18</sup> Supervised therapy sessions emphasizing exercises such as quadriceps sets, hamstring curls, straight-leg raises, and heel raises have been shown to produce statistically significant improvements in knee pain and functional outcome scores.<sup>17-18</sup> Patients should be encouraged to avoid deep-knee flexion activities that exacerbate their pain such as squatting and kneeling.<sup>17-18</sup> Intra-articular steroid injections can be useful adjuncts to minimize inflammation and suppress symptoms in patients with osteoarthritis. Several studies have shown statistically significant, short-term improvement in pain following an intra-articular steroid injection lasting 2–4 weeks or longer.<sup>13</sup>

Katz et al. performed a randomized controlled trial comparing arthroscopic meniscectomy to a standardized physical therapy regimen in 351 patients 45 years and older with MRI-confirmed meniscal tear and osteoarthritis.<sup>14</sup> This study showed no significant differences in magnitude of improvement in functional status evaluated by Western Ontario and McMaster Arthritis Index (WOMAC) as well as pain at 6 and 12 months after intervention.<sup>14</sup> Moseley et al. compared outcomes after randomization of 180 patients with osteoarthritis and meniscal tears to an arthroscopic debridement, arthroscopic lavage, or placebo surgery group and reported no significant differences in the Knee-Specific Pain Scale at one- and two-year follow-up.<sup>15</sup> Sihvonen et al. evaluated outcomes after random assignment to either arthroscopic partial-meniscectomy or a sham-controlled

**Figure 3.** Meniscal tear patterns

*Image Courtesy of Michaela Procaccini*



surgery for patients with symptoms consistent with a degenerative medial meniscus tear without osteoarthritis.<sup>16</sup> There were no significant differences in change from baseline to 12 months in any of the primary outcome scores, regardless of intervention.<sup>16</sup> The effect of various biases, crossover from treatment groups, and the external validity of these trials have recently brought some of these data into question.<sup>19</sup> These studies demonstrate the difficulty practitioners have deciphering whether knee pain is the result of osteoarthritis or a symptomatic meniscal injury, and subsequently determining the appropriate management. However, they do reinforce the importance of attempting conservative management, especially for the older patient with a degenerative tear. Some clues that can help identify the source of pain are the mechanism of injury, radiographic findings consistent with osteoarthritis, and patient demographics.

Patients with large or complex tears, a traumatic mechanism, or a large joint effusion are likely candidates for operative intervention. Severe pain with provocative maneuvers such as the McMurray, Apley, and Steinman tests or any patient with a locked knee are also likely surgical candidates.<sup>6, 20</sup> Patients with persistent symptoms after a period of conservative management should receive orthopedic consultation for either arthroscopy or arthroplasty as appropriate.<sup>6, 20</sup> Operative options include partial meniscectomy, total meniscectomy, meniscal repair, and meniscal transplantation. A partial meniscectomy is by far the most common procedure preferred for centrally located radial tears, complex tears away from the periphery, and degenerative tears.<sup>20</sup>

Peripheral tears that have good vascularity and subsequently a greater likelihood of healing are often better targeted by meniscal repair procedures.<sup>6, 20</sup> This includes longitudinal tears located peripherally, especially in young patients, and tears associated with ACL injury when repaired concomitantly.<sup>20</sup>

Total meniscectomies are rarely performed considering the implication of increased stresses experienced by articular cartilage as well as early degenerative changes.<sup>6</sup> Meniscal transplantation is usually considered after partial or total meniscectomy with persistent symptoms in younger patients that have reached skeletal maturity without arthritic changes of the knee.

## CONCLUSION

Meniscal injury is one of the more common musculoskeletal conditions and a frequent cause of knee pain. It is important for physicians to recognize meniscal pathology as a source of knee pain and not solely an MRI finding. Painful tears can be managed conservatively in certain circumstances as well as surgically with success.

## References

- Kim S, Bosque J, Meehan J, P, Jamali A, Marder R. (2011). Increase in outpatient knee arthroscopy in the United States: a comparison of National Surveys of Ambulatory Surgery, 1996 and 2006. *The JBJS. American volume*, 93(11), 994-1000.
- Bhattacharyya T, Gale D, Dewire P, Totterman S, Gale M. E, McLaughlin S, Einhorn T, et al. (2003). The clinical importance of meniscal tears demonstrated by magnetic resonance imaging in osteoarthritis of the knee. *The JBJS. American volume*, 85-A, 4-9.
- Englund M, Guermazi A, Gale D, Hunter D.J, Aliabadi P, Clancy M, Felson D. (2008). Incidental meniscal findings on knee MRI in middle-aged and elderly persons. *N Engl J Med*, 359(11), 1108-1115.
- Snoeker B, Bakker E, Kegel C, Lucas C. (2013). Risk factors for meniscal tears: a systematic review including meta-analysis. *J Orthop Sports Phys Ther*, 43(6), 352-67.
- Jones J.C, Burks R, Owens B, Sturdivant R, Svoboda S, Cameron K. (2012). Incidence and risk factors associated with meniscal injuries among active-duty US Military service members. *J Athl Train*, 47(1), 67-73.
- Boyer M. (2014). *AAOS Comprehensive Orthopedic Review*. Rosemont, IL: American Academy of Orthopedic Surgeons, 2, 1397-1402.
- Fowler PJ, Lubliner JA. The predictive value of five clinical signs in the evaluation of meniscal pathology. *Arthroscopy*, 1989;5:184-6.
- Kocabay Y, Tetik O, Isbell W, Atay O, Johnson D. (2004). The value of clinical examination versus magnetic resonance imaging in the diagnosis of meniscal tears and anterior cruciate ligament rupture. *Arthroscopy*, 20(7), 696-700
- McMurray T. The semilunar cartilages. *Br J Surg*, 1942;29:407-14.
- Sanders T, Miller M. (2005). A Systematic Approach to Magnetic Resonance Imaging Interpretation of Sports Medicine Injuries of the Knee. *Am J Sports Med*, 33(1), 131-148.
- Zanetti M, Pfirrmann C, Schmid M, Romero J, Seifert B, Hodler J. (2003). Patients with suspected meniscal tears: Prevalence of abnormalities seen on MRI of 100 symptomatic and 100 contralateral asymptomatic knees. *AJR Am J Roentgenol*, 181(3), 635-641
- Crawford R, Walley G, Bridgman S, Maffulli N. (2007). Magnetic resonance imaging versus arthroscopy in the diagnosis of knee pathology, concentrating on meniscal lesions and ACL tears: A systematic review. *British Medical Bulletin*.
- Bellamy N, Campbell J, Robinson V, Gee T, Bourne R, Wells G. (2006). Intraarticular corticosteroid for treatment of osteoarthritis of the knee. *Cochrane Database Syst Rev*, (2), CD005328
- Katz J, Brophy R, Chaisson C, Chaves L, Cole B, Dahm D, Donnell-Fink L, et al. (2013). Surgery versus physical therapy for a meniscal tear and osteoarthritis. *N Engl J Med*, 368(18), 1675-84.
- Moseley J, O'Malley K, Petersen N, Menke T, Brody B, Kuykendall D, Hollingsworth J, et al. (2002). A Controlled Trial of Arthroscopic Surgery for Osteoarthritis of the Knee. *N Engl J Med*, 347(2):81-8
- Sihvonen R, Paavola M, Malmivaara A, Itälä A, Joukainen A, Nurmi H, Kalske J, et al. (2013). Arthroscopic partial meniscectomy versus sham surgery for a degenerative meniscal tear. *N Engl J Med*, 369(26), 2515-24.
- Stensrud S. (2012). A 12-Week Exercise Therapy Program in Middle-Aged Patients With Degenerative Meniscus Tears: A Case Series With 1 Year Follow Up. *J Orthop Sports Phys Ther*, 42(11), 919-931.
- Yim J, Seon J, Song E, Choi J, Kim M, Lee K, Seo H. (2013). A comparative study of meniscectomy and nonoperative treatment for degenerative horizontal tears of the medial meniscus. *Am J Sports Medicine*, 41:1565-1570.
- Ha A, Shalvoy R, Voisinnet A, Racine J, Aaron R. (2016). Controversial Role of Arthroscopic Meniscectomy of the Knee: A Review. *WJO*, 7(5):287-92.
- Mordecai S, Al-Hadithy N, Ware H, Gupte C. (2014). Treatment of meniscal tears: An evidence based approach. *WJO*, 5(3), 233-41.

## Authors

Jacob Babu, MD, MHA, Resident, Department of Orthopaedics, Alpert Medical School of Brown University, Providence, RI.

Robert M. Shalvoy, MD, Executive Chief of Orthopedic Surgery & Sports Medicine, Care New England Health System, Assistant Professor of Orthopedic Surgery, Alpert Medical School of Brown University, Providence, RI.

Steve B. Behrens, MD, Attending Orthopedic Surgeon, Care New England Health System, Providence, RI.

## Correspondence

Jacob Babu, MD  
Department of Orthopaedics  
Rhode Island Hospital  
593 Eddy Street  
Providence, RI 02903  
401-444-4030  
jacob\_babu@brown.edu