RHODE ISLAND MEDICAL JOURNAL



SPECIAL SECTION

SPORTS MEDICINE

GUEST EDITOR: RAZIB KHAUND, MD

OCTOBER 2016 VOLUME 99 • NUMBER 10 ISSN 2327-2228

RHODE ISLAND
MEDICAL JOURNAL

On the cover
Photos: CDC, Public Health Image Library/Amanda Mills
http://phil.cdc.gov/phil/home.asp

Collaboration and Collegiality: The Fuel For Growth in Sports Medicine

RAZIB KHAUND, MD
GUEST EDITOR

This month's *Rhode Island Medical Journal* has dedicated the issue to sports medicine. It is my honor to be the guest editor, as over the past 25 years, from my days as a medical resident at Brown to my return from fellowship to start practice in Rhode Island, I have seen tremendous growth in the field locally and nationally. The acceptance of sports medicine amongst physicians and the public is parallel to its acceptance by the American Board of Medical Specialties. Fellowship training and board certification have helped to set modern standards of practice.

Truth be told, sports medicine can be traced back to Herodicus 5th century BCE with regards to fundamental theories on the use of therapeutic exercise for the maintenance of health and treatment of disease. The dawn of the modern sports medicine era is ascribed by some to Harvard Medical School in 1890. It was there that significant injuries were recognized and thus a program was instituted to educate players of the need for personal fitness, use of proper gear, need for treatment of all injuries and the importance of rehabilitation. Most people consider the true genesis of modern sports medicine to have begun in the 1950s. Don O'Donoghue, MD, from the University of Oklahoma, wrote the textbook "Treatment of Injuries to Athletes" which became the bible for sports medicine physicians. At the same time in Columbus, Georgia, Jack Hughston, MD, was starting sideline coverage of football/athletic events. His foresight to merge clinical practice, research, and education is legendary.

Sports as a part of life, be it recreational, therapeutic, competitive, or professional, continues to take on more significance as time moves on. Be it the billion-dollar industry of professional sports or the patient recovering from heart surgery who is participating in cardiac rehabilitation, people from all walks of life can benefit from sports medicine. Physicians are commonly prescribing exercise to help with overall health, and with this rise in the number of athletes comes a concomitant rise in problems and injuries specific to a sport.

The field of sports medicine can best be defined as medicine meant to include all of the subspecialties of medicine as well as nutrition, physiology, and preventative health care. It involves the education, treatment, and care not just of injuries, but of athletes. It involves the understanding of sports, climate of competition, the athlete, and medicine; and how they all relate to one another.

Sports medicine as a specialty is relatively young; however, its roots are very deep. It represents the best in medicine; a collaboration of various specialties to provide education and care to the patient. It is also susceptible to outside demands. An important tenet to remember: when treating an athlete, they are a patient first and athlete second. Education of the athlete, parents, coaches, administrators, general public, and colleagues is the best tool we have to temper expectations.

This issue of the *Rhode Island Medical Journal* includes articles addressing current "hot" topics in the field. **PETER KRIZ, MD**, and colleagues write about the need for standardization of pre-participation physical exams. Pre-participation exams are part of the foundation of sports medicine. The ability to screen and counsel athletes is an important opportunity not to be wasted. **JEFFREY FEDEN, MD**, provides insight and perspective regarding concussions in sports. Over the past few years, there has been significant media coverage of concussions. Improving the awareness of the public has been a benefit. Unfortunately, some media coverage has perpetuated misperception. **ROBERT SHALVOY, MD**, and **STEVE BEHRENS, MD**, address meniscal injuries in the knee. The article helps to review a common diagnosis seen in athletes as well as the general public. It also highlights arthroscopy and its role in revolutionizing orthopedic sports medicine. Finally, **RAMIN TABADDOR, MD**, and colleagues take on a difficult topic in Athletic Pubalgia. In the past, athletic groin pain was considered a black-box diagnosis. In the past few years, however, there have been advances in the understanding of athletic groin pain. Dr. Tabaddor's article highlights these developments and outlines treatment options.

Sports medicine is a relatively young vibrant field that is in the midst of a growth spurt. As I head into the second half of my career, I am anxious to see the future unfold.

Author

Razib Khaund, MD, Clinical Assistant Professor of Medicine, Alpert Medical School of Brown University; Director of Sports Medicine, Care New England Health Systems

Preparticipation Physical Exams: The Rhode Island Perspective, A Call for Standardization

PETER K. KRIZ, MD, FAAP, FACSM; AILIS CLYNE, MD, MPH, FAAP; SARA R. FORD, MD, FAAP

ABSTRACT

As of 2015, 98% of U.S. states require preparticipation exams (PPE) before participating in scholastic sports. Despite widespread availability of a PPE monograph endorsed by six medical societies, a lack of uniformity exists regarding implementation of the PPE among Rhode Island health care providers (HCPs). Consequently, significant variability exists regarding how comprehensive a history and physical exam screening is conducted for adolescent athletes looking for sports participation clearance. The purpose of this document is to: 1) establish a uniform screening process in Rhode Island for the PPE utilizing a peer-reviewed history and physical exam; 2) familiarize HCPs with the 2010 PPE monograph, with emphasis on the cardiovascular and musculoskeletal (MSK) systems; 3) encourage HCPs to treat the PPE as a separate entity from the annual wellness visit; 4) engage HCPs and sports medicine providers in Rhode Island to improve the quality and process of evaluating adolescent athletes for sports participation.

KEYWORDS: preparticipation exam, adolescent, athlete, screening

BACKGROUND

In 2010, the fourth edition of the Preparticipation Physical Evaluation monograph was published by 6 medical societies, including the American Academy of Family Physicians, American Academy of Pediatrics (AAP), American College of Sports Medicine, American Medical Society for Sports Medicine, American Orthopedic Society for Sports Medicine, and American Osteopathic Academy of Sports Medicine. This comprehensive, peer-reviewed document was the culmination of an extensive review of the literature including position, policy, and consensus statements pertaining to provision of health care in the adolescent population. The objective of the authoring societies was to promote the PPE as an effective tool in identifying medical and orthopedic conditions that may affect an athlete's ability to participate safely in sports, particularly when performed thoroughly and consistently by qualified, licensed supervising physicians.[1] Critics of the PPE have questioned its utility, as 1) <2% of high school athletes are ultimately disqualified from sports participation[2]; 2) the PPE lacks capacity to effectively screen athletes for risk factors associated with sudden cardiac death (SCD)[3]; 3) the PPE has little effect on the overall morbidity and mortality of athletes.[4] Proponents of the PPE cite that 1) ≥75% of medical and orthopedic conditions which may require sports participation restriction are detected by history alone[5]; 2) it allows for establishment of a medical home, updating of immunizations, identification and management of chronic health conditions related to sports and other lifestyle risk factors.

In Rhode Island, wide variability exists regarding the implementation of the PPE. In many health care settings, the PPE is combined with the annual wellness visit, due to a variety of factors. Insurance companies restrict reimbursement for adolescent physical examinations to annual wellness visits only. As a result, HCPs cannot bill insurance for dedicated sports physical/PPE. Nationally, the PPE substitutes for the annual comprehensive health evaluation in 30-88% of adolescents.[6,7] Time restrictions (e.g., timely need for physical forms for sports, camps, school enrollment) and appointment availability often impact the feasibility of scheduling separate annual wellness visits and PPE visits in most clinical practices. As a result, most HCPs utilize a state-issued School Physical Form (http://www.health.ri.gov/forms/school/Physical.pdf) which can be used for multiple purposes, including school-sponsored physical activity/sports participation and non-scholastic sports participation.

With the development of the 2010 PPE monograph comes new momentum to develop a standardized, uniform approach to the PPE. Currently, each state determines the content, comprehensiveness, and length of its respective PPE form, as well as the type of HCP licensed to perform the PPE.[1,8,9] A 2015 study found that only 19 U.S. states (37%) required or recommended use of the 2010 PPE monograph.[9] By adopting the 2010 PPE monograph, Rhode Island could assist in the establishment of a national, standardized approach to the PPE that would allow for meaningful data collection, with future editions transitioning from predominantly expert opinion-based content to evidence and outcome-driven content. Aside from the authoring societies of the 2010 PPE monograph, other organizations have recently joined in efforts to standardize the approach to PPE performance, including the Campaign and Coalition for Youth Sports Health and Safety.[8] Ninety-five percent (95%) of Americans believe that PPE screenings must be conducted in a consistent manner across the country.[10]

MAKING THE TRANSITION

Physician-reported obstacles to the delivery of the PPE include time and scheduling limitations, lack of familiarity with the medical history and physical examination portions of the PPE, uncertainty regarding relative importance of each PPE component, length of the PPE form, time spent covering non-PPE topics, and lack of a standard approach.[11] When evaluating a patient for sports participation clearance, HCPs are responsible for conducting a detailed history and physical examination that screens an athlete for cardiovascular and MSK conditions that may ultimately predispose to a life-threatening event, disabling injury or illness during training or competition. A critical element for determining athletic participation is a targeted, albeit detailed PPE history and physical examination. PPEs were never intended to take the place of an annual wellness visit; conversely, the standard history and physical examination of an annual physical can effectively be integrated into the annual physical by utilizing the PPE monograph.

The authoring societies of the 2010 PPE monograph acknowledge that the athlete's personal physician's office is the ideal setting for the PPE given the established physician-patient relationship, accessibility to the complete medical record, and comfortable environment to discuss confidential issues. This endorsement assumes clinical comfort and competency in performing the PPE. Alternative arrangements for PPE administration, such as group-based assessments by a coordinated medical team, should be available to student-athletes if a comprehensive PPE cannot be accomplished in the medical home.

One of the overall purposes of the 2010 PPE monograph was to provide a resource for primary care physicians to improve the quality of the PPE performed in the medical home and to close the knowledge gap regarding the various components of the PPE.[1] Clinicians interested in familiarizing themselves with the various components of the screening examination (e.g., general MSK screening examination) should consider purchasing the 180-page 2010 PPE monograph in its entirety. For those clinicians who have access to the current or previous editions of the PPE monograph, detailed figures provide valuable information pertaining to screening examination assessments.

The authoring societies of the 2010 PPE monograph provide the history, physical exam, and clearance forms free of charge (available at AAP Council on Sports Medicine and Fitness website). Clinicians can download these forms for use in their practice settings (**Figures 1A–B**).

THE CARDIOVASCULAR AND MUSCULOSKELETAL EVALUATIONS: WHAT YOU SHOULD KNOW

While a comprehensive review of the history and physical exam sections of the PPE is beyond the scope of this article, specific attention to key elements of the cardiovascular and MSK evaluations is warranted.

Figures 1a and 1b. 2010 PPE monograph history and physical examination forms.

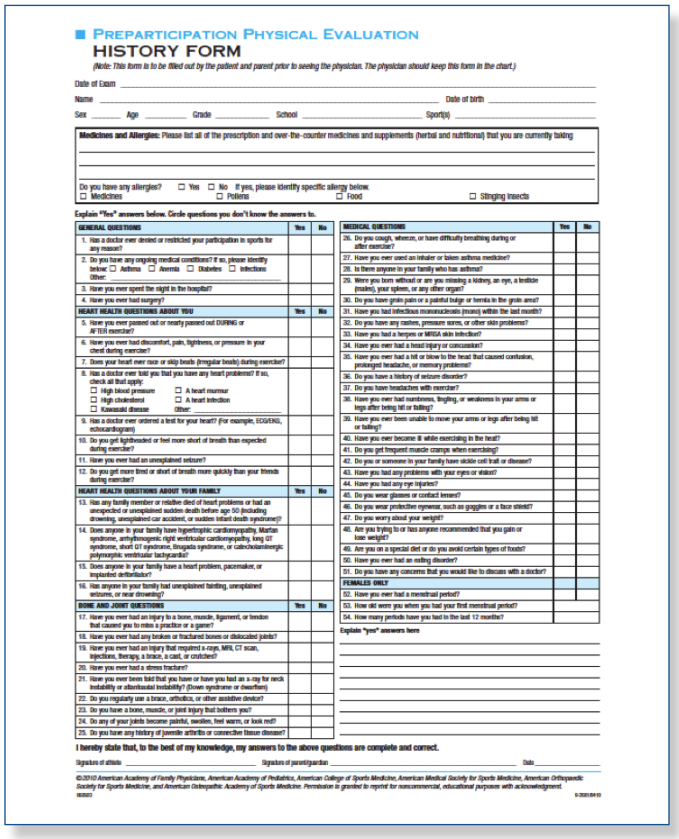

PREPARTICIPATION PHYSICAL EVALUATION
HISTORY FORM

(Note: This form is to be filled out by the patient and parent prior to seeing the physician. The physician should keep this form in the chart.)

Date of Exam _____

Name _____ Date of birth _____

Sex _____ Age _____ Grade _____ School _____ Sport(s) _____

Medicines and Allergies: Please list all of the prescription and over-the-counter medicines and supplements (herbal and nutritional) that you are currently taking

Do you have any allergies? ☐ Yes ☐ No If yes, please identify specific allergy below.
☐ Medicines ☐ Pollens ☐ Food ☐ Stinging Insects

Explain "Yes" answers below. Circle questions you don't know the answers to.

GENERAL QUESTIONS	Yes	No
1. Has a doctor ever denied or restricted your participation in sports for any reason?		
2. Do you have any ongoing medical conditions? If so, please identify below: ☐ Asthma ☐ Anemia ☐ Diabetes ☐ Infections Other:		
3. Have you ever spent the night in the hospital?		
4. Have you ever had surgery?		
HEART HEALTH QUESTIONS ABOUT YOU	**Yes**	**No**
5. Have you ever passed out or nearly passed out DURING or AFTER exercise?		
6. Have you ever had discomfort, pain, tightness, or pressure in your chest during exercise?		
7. Does your heart ever race or skip beats (irregular beats) during exercise?		
8. Has a doctor ever told you that you have any heart problems? If so, check all that apply: ☐ High blood pressure ☐ A heart murmur ☐ High cholesterol ☐ A heart infection ☐ Kawasaki disease Other:		
9. Has a doctor ever ordered a test for your heart? (For example, ECG/EKG, echocardiogram)		
10. Do you get lightheaded or feel more short of breath than expected during exercise?		
11. Have you ever had an unexplained seizure?		
12. Do you get more tired or short of breath more quickly than your friends during exercise?		
HEART HEALTH QUESTIONS ABOUT YOUR FAMILY	**Yes**	**No**
13. Has any family member or relative died of heart problems or had an unexpected or unexplained sudden death before age 50 (including drowning, unexplained car accident, or sudden infant death syndrome)?		
14. Does anyone in your family have hypertrophic cardiomyopathy, Marfan syndrome, arrhythmogenic right ventricular cardiomyopathy, long QT syndrome, short QT syndrome, Brugada syndrome, or catecholaminergic polymorphic ventricular tachycardia?		
15. Does anyone in your family have a heart problem, pacemaker, or implanted defibrillator?		
16. Has anyone in your family had unexplained fainting, unexplained seizures, or near drowning?		
BONE AND JOINT QUESTIONS	**Yes**	**No**
17. Have you ever had an injury to a bone, muscle, ligament, or tendon that caused you to miss a practice or a game?		
18. Have you ever had any broken or fractured bones or dislocated joints?		
19. Have you ever had an injury that required x-rays, MRI, CT scan, injections, therapy, a brace, a cast, or crutches?		
20. Have you ever had a stress fracture?		
21. Have you ever been told that you have or have you had an x-ray for neck instability or atlantoaxial instability? (Down syndrome or dwarfism)		
22. Do you regularly use a brace, orthotics, or other assistive device?		
23. Do you have a bone, muscle, or joint injury that bothers you?		
24. Do any of your joints become painful, swollen, feel warm, or look red?		
25. Do you have any history of juvenile arthritis or connective tissue disease?		

MEDICAL QUESTIONS	Yes	No
26. Do you cough, wheeze, or have difficulty breathing during or after exercise?		
27. Have you ever used an inhaler or taken asthma medicine?		
28. Is there anyone in your family who has asthma?		
29. Were you born without or are you missing a kidney, an eye, a testicle (males), your spleen, or any other organ?		
30. Do you have groin pain or a painful bulge or hernia in the groin area?		
31. Have you had infectious mononucleosis (mono) within the last month?		
32. Do you have any rashes, pressure sores, or other skin problems?		
33. Have you had a herpes or MRSA skin infection?		
34. Have you ever had a head injury or concussion?		
35. Have you ever had a hit or blow to the head that caused confusion, prolonged headache, or memory problems?		
36. Do you have a history of seizure disorder?		
37. Do you have headaches with exercise?		
38. Have you ever had numbness, tingling, or weakness in your arms or legs after being hit or falling?		
39. Have you ever been unable to move your arms or legs after being hit or falling?		
40. Have you ever become ill while exercising in the heat?		
41. Do you get frequent muscle cramps when exercising?		
42. Do you or someone in your family have sickle cell trait or disease?		
43. Have you had any problems with your eyes or vision?		
44. Have you had any eye injuries?		
45. Do you wear glasses or contact lenses?		
46. Do you wear protective eyewear, such as goggles or a face shield?		
47. Do you worry about your weight?		
48. Are you trying to or has anyone recommended that you gain or lose weight?		
49. Are you on a special diet or do you avoid certain types of foods?		
50. Have you ever had an eating disorder?		
51. Do you have any concerns that you would like to discuss with a doctor?		
FEMALES ONLY		
52. Have you ever had a menstrual period?		
53. How old were you when you had your first menstrual period?		
54. How many periods have you had in the last 12 months?		

Explain "yes" answers here

I hereby state that, to the best of my knowledge, my answers to the above questions are complete and correct.

Signature of athlete _____ Signature of parent/guardian _____ Date _____

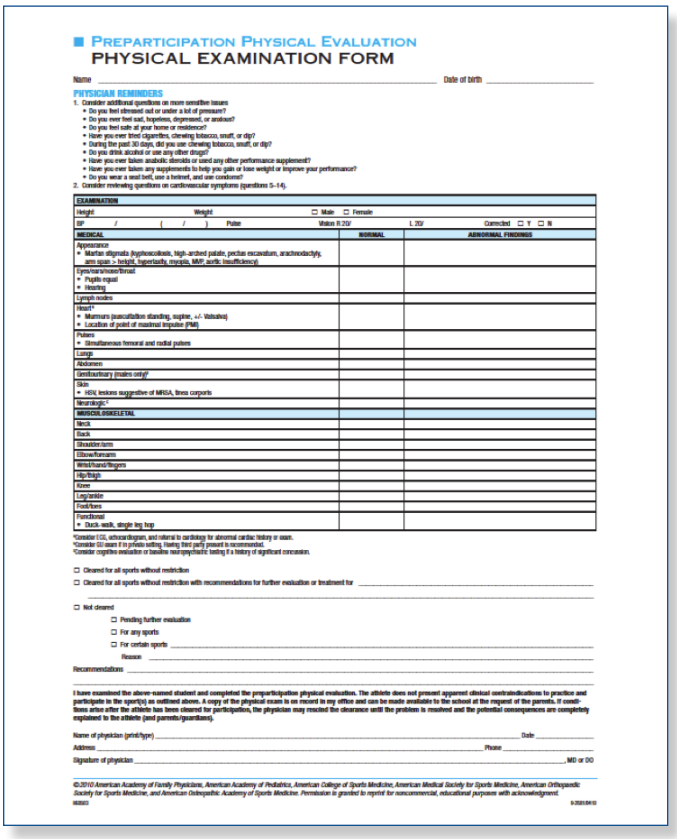

PREPARTICIPATION PHYSICAL EVALUATION
PHYSICAL EXAMINATION FORM

Name _____ Date of birth _____

PHYSICIAN REMINDERS

1. Consider additional questions on more sensitive issues
   - Do you feel stressed out or under a lot of pressure?
   - Do you ever feel sad, hopeless, depressed, or anxious?
   - Do you feel safe at your home or residence?
   - Have you ever tried cigarettes, chewing tobacco, snuff, or dip?
   - During the past 30 days, did you use chewing tobacco, snuff, or dip?
   - Do you drink alcohol or use any other drugs?
   - Have you ever taken anabolic steroids or used any other performance supplement?
   - Have you ever taken any supplements to help you gain or lose weight or improve your performance?
   - Do you wear a seat belt, use a helmet, and use condoms?
2. Consider reviewing questions on cardiovascular symptoms (questions 5–14).

EXAMINATION		
Height / Weight ☐ Male ☐ Female		
BP / (/) Pulse Vision R 20/ L 20/ Corrected ☐ Y ☐ N		
MEDICAL	**NORMAL**	**ABNORMAL FINDINGS**
Appearance • Marfan stigmata (kyphoscoliosis, high-arched palate, pectus excavatum, arachnodactyly, arm span > height, hypermobility, myopia, MVP, aortic insufficiency)		
Eyes/ears/nose/throat • Pupils equal • Hearing		
Lymph nodes		
Heart* • Murmurs (auscultation standing, supine, +/- Valsalva) • Location of point of maximal impulse (PMI)		
Pulses • Simultaneous femoral and radial pulses		
Lungs		
Abdomen		
Genitourinary (males only)†		
Skin • HSV, lesions suggestive of MRSA, tinea corporis		
Neurologic‡		
MUSCULOSKELETAL		
Neck		
Back		
Shoulder/arm		
Elbow/forearm		
Wrist/hand/fingers		
Hip/thigh		
Knee		
Leg/ankle		
Foot/toes		
Functional • Duck-walk, single leg hop		

*Consider ECG, echocardiogram, and referral to cardiology for abnormal cardiac history or exam.
†Consider GU exam if in private setting. Having third party present is recommended.
‡Consider cognitive evaluation or baseline neuropsychiatric testing if a history of significant concussion.

☐ Cleared for all sports without restriction

☐ Cleared for all sports without restriction with recommendations for further evaluation or treatment for _____

☐ Not cleared
- ☐ Pending further evaluation
- ☐ For any sports
- ☐ For certain sports _____
  - Reason _____

Recommendations _____

I have examined the above-named student and completed the preparticipation physical evaluation. The athlete does not present apparent clinical contraindications to practice and participate in the sport(s) as outlined above. A copy of the physical exam is on record in my office and can be made available to the school at the request of the parents. If conditions arise after the athlete has been cleared for participation, the physician may rescind the clearance until the problem is resolved and the potential consequences are completely explained to the athlete (and parents/guardians).

Name of physician (print/type) _____ Date _____

Address _____ Phone _____

Signature of physician _____ MD or DO

Preparticipation cardiovascular screening in athletes entails a detailed personal and family history and physical exam. Cardiovascular disorders are the leading cause of sudden death in young athletes, accounting for ~ 75% of all sudden death in athletes.[12] In the United States, hypertrophic cardiomyopathy (HCM) and congenital coronary artery anomalies are the most common etiologies of sudden cardiac death (SCD), with HCM accounting for one-third of SCD deaths in US athletes younger than 30 years.[13] The prevalence of HCM is 1:500 in the general population, and ~ 1:1000-1500 in competitive athletes.[14] Because HCM is the most common genetic cardiovascular disease,[15] a targeted family history may trigger a referral to cardiology for additional screening and increase the yield of detection of this high-risk condition. Most athletes with HCM are asymptomatic, with SCD often the sentinel event of their disease. Only 25% of patients with HCM have a murmur,[16] which characteristically is a harsh systolic ejection murmur, best heard at the left sternal border that increases in intensity with maneuvers decreasing venous return (e.g., Valsalva, moving from squat to stand) and diminishes with maneuvers increasing venous return (e.g., supine position, transitioning from stand to squat).[1] Coronary artery anomalies are the second-leading cause of SCD, accounting for ~ 17% of cases in athletes.[13] Abnormal origin of the left coronary artery is the most common anomaly. <50% of SCD cases from coronary anomalies have prodromal symptoms identifiable by preparticipation history. The American Heart Association (AHA)[13] recommends the PPE include:

1. **Auscultation for heart murmurs:** should be performed in both supine and standing positions (or with Valsalva) to identify dynamic LV outflow tract obstruction murmurs. Standing is preferred to sitting because the diagnostic HCM murmur becomes louder when the patient stands due to decreased venous return.
2. **Palpation of the femoral pulses:** delayed femoral artery pulses compared to radial artery pulses (radiofemoral delay) may indicate the presence of coarctation of the aorta and warrant further diagnostic assessment.
3. **Examination for physical stigmata of Marfan syndrome:** kyphoscoliosis, high-arched palate, pectus carinatum or excavatum, arachnodactyly (long, slender fingers), arm span greater than height (ratio > 1.05), mitral valve prolapse, aortic insufficiency murmur, myopia, and generalized hyperlaxity are clinical findings.
4. **Brachial artery blood pressure:** should be obtained on a bare upper arm supported at heart level, measured with an appropriate cuff size, with the patient in the sitting position with back supported.

Currently, noninvasive cardiovascular screening tests such as ECG or echocardiography are not recommended in the preparticipation screening of athletes. A discussion regarding this controversial topic is beyond the scope of this article, but numerous articles[17-19] illustrate the ongoing debate in sports medicine and cardiology communities.

Regarding the musculoskeletal evaluation, a focused history is the most important first step in the PPE[2]:

- Athletes with unresolved musculoskeletal pain require additional evaluation prior to sports clearance.
- Stress fractures may be associated with inadequate caloric, calcium, and vitamin D intake.
- Fractures or dislocated joints represent more serious orthopedic injuries, and often accompany each other. Neurologic deficits can be associated with such injuries. Referral to sports medicine specialists may be indicated prior to clearance.

While the overall yield of the MSK examination in detecting significant injuries in asymptomatic athletes with no history of injury is typically low (in contrast, history alone is 92% sensitive in detecting significant MSK injuries[20]), a general MSK screening examination is recommended[1]:

- Inspection: athlete faces examiner. Assess symmetry of trunk, upper and lower extremities, upper-to-lower segment ratio, arm span-to-height (should be < 1.05), general body habitus
- Assess cervical ROM (flexion, extension, lateral rotation, lateral flexion)
- Assess shoulder function (resisted shoulder shrug for trapezius strength, resisted abduction to 90° for deltoid strength, internal and external rotation for glenohumeral joint ROM)
- Assess upper extremity function (flexion/extension of elbows for ROM, pronation/supination of forearms for ROM, clench fist and spread fingers for ROM).
- Assess back/spine: athlete faces away from examiner. Assess forward flexion, extension, perform Adams forward bend testing to evaluate for scoliosis.
- Perform "duck walk" for 4 steps (hip, knee, and ankle ROM; strength and balance testing).
- Perform toe and heel walk (calf symmetry and strength, balance).

Clinicians should augment the general screening examination with a thorough joint-specific examination as indicated by historical or general screening findings (e.g., glenohumeral joint instability), and referral to an orthopedic specialist should be considered if diagnosis, clearance, or further treatment decisions are uncertain. Sport-specific examinations may be considered in addition to the general screening examination to assess strength, endurance, and flexibility testing in joints or segments under particular stress in a given sport (e.g., shoulders in swimmers and baseball pitchers).[1]

SUMMARY AND RECOMMENDATIONS

Despite controversy regarding the effectiveness of the PPE as a screening tool for potentially life-threatening or disabling medical/MSK conditions, PPEs continue to be widely performed and a necessary requirement for scholastic sport participation. Currently in Rhode Island, there is no uniform or standardized process for conducting a PPE. Additionally, annual wellness visits and PPEs are commonly combined by HCPs out of convenience and necessity. Potential to miss the opportunity to identify conditions that may be life-threatening or disabling may occur if pertinent historical information is not gathered and a systems-based physical examination is not performed.

The 2010 PPE monograph is a comprehensive tool that is gaining traction nationally as a standard for all 50 states to utilize for preparticipation physical evaluation of adolescent athletes. The current Rhode Island School Physical Form includes a section to indicate any physical activity restrictions, but the form does not specifically require documentation that life-threatening or disabling medical and musculoskeletal conditions in athletes were screened for. Rhode Island physicians and affiliated health care providers can ensure a more comprehensive and consistent approach to the PPE by adopting the screening recommendations in the 2010 PPE monograph for the performance of PPEs in their respective clinical settings. It is not the charge of the clinician to find the one "needle in a haystack" diagnosis that will prevent a sports-related adverse event, but rather to provide a more uniform, systematic screening process. Adopting and implementing the 2010 PPE monograph history, physical examination, and clearance forms could assist in development of a national, standardized approach to the PPE. By utilizing the 2010 PPE monograph, clinicians can improve the quality of their PPE data collection, physical examination skills, and ultimately contribute to an evidence-based approach and expanding scientific basis for the preparticipation physical evaluation.

References

1. American Academy of Family Physicians, American Academy of Pediatrics, American College of Sports Medicine. Preparticipation Physical Evaluation, 4th ed, Bernhardt D, Roberts W (Eds), American Academy of Pediatrics, Elk Grove Village, IL 2010.
2. Smith J, Laskowski ER. The preparticipation physical examination: Mayo Clinic experience with 2,739 examinations. *Mayo Clin Proc.* 1998;73:419–429.
3. Magalski A, McCoy M, Zabel M, et al. Cardiovascular screening with electrocardiography and echocardiography in collegiate athletes. *Am J Med.* 2011;124:511–518.
4. Best TM. The preparticipation evaluation: an opportunity for change and consensus. *Clin J Sport Med*. 2004;14:107-108.
5. Koester MC, Amundson CI. Preparticipation screening of high school athletes: are recommendations enough? *Phys Sportsmed.* 2003;31(8):35-38.
6. Goldberg B, Saraniti A, Witman P, et al. Pre-participation sports assessment--an objective evaluation. *Pediatrics*. 1980;66:736.
7. Risser WL, Hoffman HM, Bellah GG. Frequency of preparticipation sports examinations in secondary school athletes: are the University Interscholastic League guidelines appropriate? *Tex Med*.1985;81(7):35–39.
8. Seto CK. The preparticipation physical examination: an update. *Clin Sports Med.* 2011 Jul;30(3):491-501.
9. Caswell SV, Cortes N, Chabolla M, et al. State-specific differences in school sports preparticipation physical evaluation policies. *Pediatrics.* 2015 Jan;135(1):26-32.
10. PR Newswire. Athletes, physicians urge adoption of new medical screening tool. 2010. http://www.prnewswire.com/news-releases/athletes-physicians-urge-adoption-of-new-medical-screening-tool-93681639.html. Accessed July 24, 2016.
11. Madsen NL, Drezner JA, Salerno JC. The preparticipation physical evaluation: an analysis of clinical practice. *Clin J Sport Med.* 2014 Mar;24(2):142-9.
12. Maron BJ, Doerer JJ, Haas TS, et al. Profile and frequency of sudden death in 1463 young competitive athletes: from a 25 year US national registry: 1980-2005. *Circulation.* 2006;114:II(18):830.
13. Maron BJ, Thompson PD, Ackerman MJ, et al. Recommendations and considerations related to preparticipation screening for cardiovascular abnormalities in competitive athletes: 2007 update: a scientific statement form the American Heart Association Council on Nutrition, Physical Activity, and Metabolism: endorsed by the American College of Cardiology Foundation. *Circulation.* 2007;115(12):1643-1455.
14. Basavarajaiah S, Wilson M, Whyte G, et al. Prevalence of hypertrophic cardiomyopathy in highly trained athletes: relevance to pre-participation screening. J *Am Coll Cardiol.* 2008;51(10):1033-1039.
15. Marron BJ. Hypertrophic cardiomyopathy: a systematic review. *JAMA.* 2002;287:1308-1320.
16. Maron BJ. Hypertrophic cardiomyopathy. *Lancet.* 1997;350(9071):127-133.
17. Sharma S, Millar L. Yes: Screening ECG is cost-effective. *Am Fam Physician.* 2015 Sep 1;92(5):338-340.
18. Wexler R, Estes NA 3rd. Should preparticipation cardiovascular screening of athletes include ECG? No: there is not enough evidence to support including ECG in the preparticipation sports evaluation. *Am Fam Physician.* 2015 Sep 1;92(5):343-4.
19. Roberts WO, Asplund CA, O'Connor FG, et al. Cardiac preparticipation screening for the young athlete: why the routine use of ECG is not necessary. *J Electrocardiol.* 2015 May-Jun;48(3):311-5.
20. Gomez JE, Landry GL, Bernhardt DT. Critical evaluation of the 2-minute orthopedic screening examination. *Am J Dis Child.*1993;147(10):1109-1113.

Authors

Peter K. Kriz, MD, FAAP, FACSM, is the chief of primary care sports medicine at University Orthopedics. He is an Assistant Professor (Clinical) of Orthopedics and Pediatrics at the Warren Alpert Medical School of Brown University. Dr. Kriz is also a member of the Rhode Island Interscholastic League's Sports Medicine Advisory Committee.

Ailis Clyne, MD, MPH, FAAP, is a board-certified pediatrician and immediate past president of the Rhode Island chapter of the American Academy of Pediatrics. Dr. Clyne contributed to this article in her personal capacity. The opinions expressed in this article do not represent the views of the Rhode Island Department of Health.

Sara R. Ford, MD, FAAP, is a pediatric cardiologist at Hasbro Children's Hospital. She is an Associate Professor of Pediatrics (Clinical) at the Warren Alpert Medical School of Brown University. Dr. Ford is also secretary on the board of directors of the Rhode Island chapter of the American Academy of Pediatrics.

Disclosures

The authors and/or their spouses/significant others have no financial interests to disclose.

Correspondence

Peter Kriz, MD, FAAP, FACSM

2 Dudley St., Suite 200, Providence, RI 02905

401-457-2188; Fax 401-457-2187

Peter_Kriz@brown.edu

Current Concepts in Sports-related Concussion

JEFFREY P. FEDEN, MD

ABSTRACT

Increasing concern over the acute and long-term consequences of sports-related concussion has generated widespread interest and attention. This article provides an overview of concussion in athletes, including diagnostic and management considerations, and highlights the clinical challenges associated with repeated minor head trauma in sports.

KEYWORDS: Sports-related concussion, mild traumatic brain injury, athletes

Table 1. Symptoms of Concussion

Physical	Cognitive	Behavioral
Headache	Memory problems	Increased emotions
Nausea/Vomiting	Difficulty concentrating	Sadness
Visual disturbance	Fogginess	Depression
Dizziness/Vertigo	Feeling slowed down	Anxiety
Impaired balance	Confusion	Irritability
Sensitivity to light/noise		
Fatigue		
Sleep disturbance		

INTRODUCTION

Sports-related concussion has become a growing concern in recent years and has generated considerable discussion within the scientific and athletic communities. Perhaps no other issue in sports medicine has received as much attention in the media as the potential long-term consequences of concussion in athletes. An estimated 1.6 million to 3.8 million concussions occur annually in the United States (1), but many more may go unrecognized or unreported. Although significant advances have been made over the last decade, the assessment and management of concussion remains a challenging endeavor.

PATHOPHYSIOLOGY

Concussion is defined as a complex pathophysiologic process resulting in transient neurologic dysfunction following a biomechanical insult to the brain, with or without loss of consciousness (2). It falls on the mild end of the traumatic brain injury (TBI) spectrum. There is considerable evidence to implicate linear and rotational acceleration forces at the moment of impact, causing deformation of neuronal membranes and axonal stretching. The resulting neurometabolic cascade involves ionic imbalances and local metabolic dysfunction (3). These physiologic disturbances are transient but render the brain more vulnerable to repeat injury, possibly with longer lasting effects.

EVALUATION AND RETURNING TO PLAY

The acute clinical effects of concussion result from neuronal dysfunction. They include balance and cognitive impairment, and any of more than 20 symptoms ranging from headache and "fogginess" to irritability (**Table 1**). Diagnosis is made when an athlete presents with the typical constellation of findings following either direct or indirect trauma. The focus of initial care is on the evaluation for cervical spine injury or neurosurgical emergency. The next step in evaluating and managing concussion involves recognition of the injury and removal from play. A systematic neurologic exam and assessment of symptoms, cognition, and balance will often lead to the correct diagnosis. However, sports-related concussion is not always easy to identify. While novel technologies are being developed to measure biomechanical forces, the magnitude of head impact does not necessarily predict clinical injury. Furthermore, the various symptoms of concussion are nonspecific, sometimes resulting in a diagnostic dilemma. This is complicated by the fact that athletes may not recognize the significance of their symptoms or will conceal symptoms in an effort to continue playing. Symptom checklists, such as the Sideline Concussion Assessment Tool (version 3, aka SCAT3) (2), are useful in the sideline evaluation after injury and have been adapted to assist in the office-based evaluation of concussion. Unless there is concern for structural brain injury, CT or MRI is often unnecessary. Traditional neuroimaging is expected to be normal in concussion, reflecting the more functional nature of the injury.

Same-day return to play should not be allowed at any level of sport for an athlete with diagnosed or suspected concussion. Following the Zackery Lystedt Law in Washington State in 2009, all fifty states have now enacted some form of concussion legislation in an effort to increase awareness and improve athlete safety. Rhode Island's School and Youth Programs Concussion Act (Chapter 16–91) mandates education for all coaches and volunteers involved with interscholastic

athletics; it requires immediate removal from play for suspected concussion, and written clearance for return to sports must be provided by a licensed physician (4).

After eliminating life-threatening injury and diagnosing concussion, safely returning an athlete to sports is a critical piece of the management paradigm. Grading systems were popular in the diagnosis and management of sports-related concussion in the early 1990s (5). However, these systems were flawed and have been abandoned as the focus shifted from categorizing injury severity to making individual recommendations based on several factors. Although most concussions will resolve within 7–10 days (6), recovery can be unpredictable and some may take significantly longer to improve. The return-to-play decision is complex and requires a very individualized plan. It is well understood that returning an athlete to sports assumes complete resolution of symptoms at rest and with physical activity, in addition to full recovery of cognitive function. Physical rest eliminates the risk of another head injury and allows recovery, though the degree and duration of rest are debatable. The widely used protocol published by the Concussion in Sport group is a consensus approach that outlines a progression of activity from light aerobic exercise to full contact activity (2). Introduction of exercise occurs once the athlete is asymptomatic, and each step identifies a 24-hour period with suggested activity (**Table 2**). Successful completion of each step requires that symptoms are not exacerbated during or after exertion.

Table 2. Graded Return to Play Protocol

Stage	Activity	Functional Exercise	Objective
1	No activity	Complete physical and cognitive rest	Recovery
2	Light activity	Low-intensity aerobic exercise Walk, swim, stationary bike	Increase heart rate
3	Sport-specific	Simple sport-related exercise Skating, running	Add movement
4	Training	Noncontact sport-related training drills Resistance training	Coordination and cognitive load
5	Full contact practice	Resume normal activity/practice	Restore confidence & Assess function
6	Return to play	Resume competitive game play	

Adapted from Consensus Statement on Concussion in Sport (2).

In addition to physical rest, cognitive rest is recommended as a cornerstone of concussion management and is also consensus-based (2). Cognitive rest entails limiting activities of attention and concentration, including schoolwork and video games, which may exacerbate symptoms and delay recovery. It often involves varying levels of academic accommodations (and sometimes removal from school) in an effort to allow recovery and preserve school performance. Although guidelines for "returning to learn" lack a strong evidence base, there is increasing attention to the need for a student-athlete's gradual and structured return to the classroom. The American Academy of Pediatrics emphasizes the importance of this and provides strategies for a productive transition back into the academic setting following concussion (7).

NEUROPSYCHOLOGICAL TESTING

Neuropsychological assessment first entered the scene in the late 1980s when it was discovered that sports-related concussion results in an acute decline in neurocognitive function. Traditional paper and pencil testing was cumbersome and gave way to computerized neurocognitive testing in the 1990s as a tool to more objectively evaluate concussion. Neuropsychological testing adds diagnostic value over symptom reporting alone (8), and computerized neurocognitive testing is now an important piece in the evaluation and management of concussion. Formal testing examines memory, attention, reaction time and other executive functions commonly affected by mild TBI. It allows for detection of subtle cognitive deficits, which can persist beyond symptom resolution. It is most useful to have a baseline evaluation for comparison following injury, but testing can be beneficial in the athlete without pre-injury data as well. Computerized neurocognitive testing is inexpensive, widely available, and has demonstrated reliability and validity (9). Nevertheless, it must be understood that such testing is only a single tool in the comprehensive evaluation of concussion and should not stand alone or be considered mandatory.

FEARED CONSEQUENCES

Although the neurometabolic disturbances and symptoms of concussion are often short-lived, there are acute and long-term consequences related to unrecognized or recurrent injury. A very conservative approach to managing concussion has evolved based on our knowledge of three major (and often controversial) clinical concerns: second impact syndrome, post-concussion syndrome, and chronic traumatic encephalopathy.

Second Impact Syndrome

The phenomenon of second impact syndrome, first popularized in the mid-1980s, remains a frequently cited concern when returning athletes to play. It refers to a second impact that occurs prior to recovery from an initial concussive injury, leading to loss of cerebral autoregulation, diffuse cerebral edema, and permanent neurologic disability or death. However, there is little evidence to support its existence and it is, at most, an exceedingly rare entity (10). Participation in contact and collision sports will always present a risk for catastrophic head trauma, but the reference to second impact syndrome as a reason for caution is debatable.

Post-concussion Syndrome

Post-concussion syndrome (PCS) is another major concern and represents the most practical clinical challenge following sports-related concussion. The definition of PCS in the medical literature is inconsistent, but it is generally understood to be the persistence of cognitive, physical, or emotional symptoms well beyond the expected time frame for recovery (11). Post-concussion syndrome is considered when concussion symptoms last more than six to twelve weeks following injury, and some experts argue that PCS is the manifestation or unmasking of psychiatric illness rather than the neurological injury itself. Severity of injury does not always correlate with symptoms, but a large symptom burden might predict a prolonged course. Pre-existing migraine headaches and learning difficulties may also herald a lengthy recovery. There is evidence to suggest a period of vulnerability following concussion, and repeated injury during this period can exacerbate symptoms and complicate recovery (3). A protracted course following a second concussion before complete recovery is perhaps more concerning than the unlikely second impact syndrome.

Regardless of the underlying pathophysiology, a multidisciplinary and symptom-targeted approach is best for managing PCS. Education of the athlete, family, coaching staff and others in the recovery process is universally important as well. While there are various medical treatments available, evidence is limited, and many therapies remain anecdotal or opinion-based. Pharmacologic therapy is directed toward alleviating symptoms but should not be expected to speed recovery and may cause cognitive or behavioral side effects. Examples include melatonin for sleep disturbance, amitriptyline for headache, selective serotonin reuptake inhibitors for depression, and amantadine for cognitive impairment (12). Unfortunately, because there is little supportive evidence for the use of medications for PCS in athletes, these strategies should be considered only by experienced providers after failure of more conservative measures.

Rehabilitation techniques play an increasing role in the management of prolonged concussion recovery. Cognitive behavioral therapy may be helpful in managing emotional and sleep disturbances, as well as other physical symptoms such as posttraumatic headache. Neurocognitive rehabilitation may enhance memory, attention and general cognitive performance. Vestibular rehabilitation may help relieve dizziness and improve gait and balance. It has been postulated that prolonged rest may actually be detrimental to recovery. Some experts advocate a supervised and controlled aerobic exercise rehabilitation program for athletes with symptoms lasting beyond three weeks. Gradual progression of exercise at a subsymptom threshold can aid in recovery (13).

Chronic Traumatic Encephalopathy

The third major concern surrounding sports-related concussion involves the cumulative effects of repeated head trauma. The investigation into long-term neuropathologic, cognitive, and behavioral changes is not well established. Some research supports a decline in neurocognitive function with multiple concussions, but other studies have failed to demonstrate cumulative adverse effects (14). Chronic traumatic encephalopathy (CTE) was first described in boxers as dementia pugilistica in the 1930s, referring to boxer's dementia. CTE is a neurodegenerative disease found in individuals with a history of repetitive mild traumatic brain injury. It shares clinical similarities with Alzheimer's dementia and parkinsonism, but diagnosis is made only by distinct changes on post-mortem neuropathologic examination.

Although the risks of developing neurodegenerative disease from boxing have been recognized for decades, researchers and the media have more recently brought attention to this risk in football following several high-profile cases and tragic deaths. CTE generally occurs later in life, long after retirement from sports, and is characterized by an insidious-onset of cognitive decline and behavioral changes. Deterioration of mental health has also been highlighted as a concern. Clinical diagnosis is complicated by the lack of standard criteria, the requirement for autopsy confirmation, and confounders such as substance abuse. Additionally, the exact relationship between sports-related concussion and CTE remains unclear (15). Risk factors within sport are largely unknown, including the significance of repetitive subconcussive head trauma or even a single lifetime concussion. Nonetheless, concerns about the cumulative effects of both concussive and subconcussive impacts are growing, and certain thresholds may predict later-life depression and cognitive impairment (16).

Based on the subacute and chronic consequences of concussion mentioned above, the question of retiring athletes from contact or collision sports is frequently encountered in clinical practice. There are no specific data or criteria on which to base retirement decisions, and each decision is highly individualized. Despite a lack of strict guidelines, it is generally understood that several variables will prompt this discussion: decreasing time intervals between concussions, relatively minor impacts causing or exacerbating symptoms, and increasing symptom burden or duration with each successive injury.

FUTURE DIRECTIONS

Concussion will always be an inherent risk of contact and collision sports. Present and future efforts toward mitigating this risk are focused on prevention, diagnosis, and improved understanding of long-term sequelae. Primary prevention includes enforcement of existing rules and careful consideration of further rule changes. Equipment use and modification is important for injury prevention, but despite manufacturers' claims, there is no conclusive scientific evidence that protective equipment prevents or reduces risk of concussion. Continued efforts toward educating the athletic community about injury recognition and significance, and

the importance of safe return to competition, is essential in limiting adverse outcomes.

Presently, sports-related concussion is a clinical diagnosis. Advances in areas like biomarker research and functional magnetic resonance imaging may someday offer a more objective view of this injury. Development of other technologies, such as force-measuring accelerometers in football helmets, may also change our understanding of head trauma, as may further research into the roles of age, gender, and genetic predisposition as risk factors for injury or long-term complications.

CONCLUSIONS

Our knowledge of sports-related concussion has grown exponentially in the past decade, but it is clear that we have only scratched the surface. Dissemination of information by media outlets has outpaced our true scientific understanding of concussion. This has been productive in educating the public about its significance, and education is integral in mitigating risk. However, it has arguably created unsubstantiated concern in the absence of sound evidence for poor long-term outcomes. The management of sports-related concussion has evolved from grading systems to consensus-based recommendations with a limited base of evidence. Currently, the standard for management incorporates a conservative, individualized approach guided by the principles of physical and cognitive rest, though the role of strict or prolonged rest is being challenged. Complex cases often require a multidisciplinary team consisting of primary care providers, sports medicine specialists, neurologists, mental health professionals, neuropsychologists, and physical therapists.

References

1. Langlois JA, Rutland-Brown W, Wald MM. The epidemiology and impact of traumatic brain injury: a brief overview. *J Head Trauma Rehabil*. 2006;21(5):375-8.
2. McCrory P, Meeuwisse W, Aubry M, et al. Consensus statement on concussion in sport: the 4th International Conference on Concussion in Sport held in Zurich, November 2012. *Clin J Sport Med*. 2013;23(2):89-117.
3. Giza CG, Hovda DA. The neurometabolic cascade of concussion. *J Athl Train*. 2001;36(3):228-35.
4. Chapter 16-91: School and Youth Programs Concussion Act. Retrieved September 6, 2016, http://webserver.rilin.state.ri.us/Statutes/TITLE16/16-91/INDEX.HTM
5. Collins MW, Lovell MR, McKeag DB. Current issues in managing sports-related concussion. *JAMA*. 1999;282(24):2283-5.
6. McCrea M, Guskiewicz KM, Marshall SW, et al. Acute effects and recovery time following concussion in collegiate football players: the NCAA Concussion Study. *JAMA*. 2003;290(19):2556-63.
7. Halstead ME, McAvoy K, Devore CD, et al. Returning to learning following a concussion. *Pediatrics*. 2013;132(5):948-57.
8. Van Kampen DA, Lovell MR, Pardini JE, et al. The "value added" of neurocognitive testing after sports-related concussion. *Am J Sports Med*. 2006;34(10):1630-5.
9. Johnson EW, Kegel NE, Collins MW. Neuropsychological assessment of sport-related concussion. *Clin Sports Med*. 2011;30(1):73-88.
10. McCrory P, Davis G, Makdissi M. Second impact syndrome or cerebral swelling after sporting head injury. *Curr Sports Med Rep*. 2012;11(1):21-3.
11. Jotwanu V, Harmon KG. Post-concussion syndrome in athletes. *Curr Sports Med Rep*. 2010;9(1):21-6.
12. Meehan WP 3rd. Medical therapies for concussion. *Clin Sports Med*. 2011;30(1):115-24.
13. Leddy JJ, Willer B. Use of graded exercise testing in concussion and return-to-activity management. *Curr Sports Med Rep*. 2013;12(6):370-6.
14. Belanger HG, Spiegel E, Vanderploeg RD. Neuropsychological performance following a history of multiple self-reported concussions: a meta-analysis. *J Int Neuropsychol Soc*. 2010;16(2)262-7.
15. Stern RA, Riley DO, Daneshvar DH, et al. Long-term consequences of repetitive brain trauma: chronic traumatic encephalopathy. *PM R*. 2011:3(10 Suppl 2):S460-7.
16. Montenigro PH, Alosco ML, Martin B. Cumulative head impact exposure predicts later-life depression, apathy, executive dysfunction, and cognitive impairment in former high school and college football players [published online March 30, 2016]. *J Neurotrauma*. 2016.

Author

Jeffrey P. Feden, MD, Associate Professor (Clinical), Department of Emergency Medicine, Alpert Medical School of Brown University, Providence, RI.

Disclosures

None

Correspondence

Jeffrey P. Feden, MD
Department of Emergency Medicine
593 Eddy Street, Claverick 2
Providence, Rhode Island 02903
401-444-5826
Fax 401-444-5166
jfeden@lifespan.org

Diagnosis and Management of Meniscal Injury

JACOB BABU, MD, MHA; ROBERT M. SHALVOY, MD; STEVE B. BEHRENS, MD

ABSTRACT

Meniscal injury is a common cause for presentation to the emergency department or primary care physician's office. Meniscal injuries can be the result of a forceful, twisting event in a young athlete's knee or it can insidiously present in the older patient. Many patients with meniscal pathology appropriately undergo conservative management with a primary care physician while some may need referral to an orthopedist for operative intervention. Arthroscopic surgery to address the menisci is the most frequently performed procedure on the knee and one of the most regularly performed surgeries in orthopedic surgery.[1] The purpose of this paper is to help elucidate the diagnosis and management of meniscal pathology resulting in knee pain.

KEYWORDS: meniscal injury, knee pain, osteoarthritis, arthroscopy, orthopedic referral

INTRODUCTION

The frequency in which meniscal tears occur makes it an important injury to identify by the medical practitioner. Acute, traumatic tears in the young patient and atraumatic, degenerative tears in the older patient represent a continuum of pathology, often presenting with their own difficulties in diagnosis and management. The prevalence of meniscal tears in the general population has been challenging to identify due to the high frequency of asymptomatic or undiagnosed lesions. In some Northern European countries, the estimated incidence of meniscal tears is 2 per 1000 person-years.[2] A study by Englund et al., focusing on degenerative tears, found that 35% of enrolled patients older than 50 years old had imaging evidence of a meniscal tear, with ⅔ of these being asymptomatic.[3] Risk factors associated with the development of a symptomatic meniscal tear have been identified to be a BMI > 25 kg/m^2, male sex, and occupations requiring kneeling, squatting or stair-climbing.[2-4] A military study looking at more acute, traumatic meniscal tears estimated the incidence in active duty personnel to be 8.27 per 1000 person-years.[5] In this study, age was found to be a variable associated with elevated rates of injury, with tears occurring 4 times as often in those over 40 compared to those less than 20 years of age.[5] Arthroscopic meniscectomy is estimated to occur 400,000-700,000 times annually.[1,6]

PRESENTATION

Knee pain can be the result of numerous possible intra- and extra-articular diagnoses, all of which must be kept in the differential when evaluating a patient. Meniscal tears can be identified by asking a few focused questions during the patient evaluation. The mechanism of injury is important as are the presence of specific symptoms after injury.

Acute meniscal tears are most often associated with a twisting mechanism to the knee while the foot is planted, providing an axial load. The joint swelling with a meniscus tear is more likely to present in a delayed fashion (> 24 hours).

Atraumatic, degenerative meniscal pathology more frequently presents with an insidious onset of pain. This diagnosis can be difficult to distinguish from osteoarthritis in the older patient. Mechanical symptoms are relatively common, with patients often describing the sensation of 'locking,' 'clicking,' 'popping,' and sometimes even a feeling of 'giving way' of the knee. Symptoms tend to wax and wane with activity levels.

On physical examination, joint line tenderness is often described as the most sensitive finding for diagnosing a meniscal tear; however, it is not very specific.[7] Blocks to active and passive range of motion, especially to deep flexion, are associated with more complex meniscal tears. A few provocative examination maneuvers for meniscal pain include the Apley Compression, McMurray, Steinman and Thessaly tests, demonstrated in **Figures 1** and **2**.[7,8] The basic premise of these tests involves applying an axial force through the knee joint to simulate weight-bearing while providing a rotational moment about the leg to try to elicit clicking, popping or pain. Kocabey et al. evaluated the effectiveness of various physical examination maneuvers in diagnosing meniscal pathology and found the combination of joint line tenderness, positive McMurray, Steinmann and Apley tests to have an 80% sensitivity for medial meniscal pathology and a 92% sensitivity for lateral meniscal pathology.[8]

ANATOMY

The menisci are fibrocartilaginous structures which importantly serve as load-sharing components of the knee joint. By increasing the surface area of contact between the femur and tibia, they can significantly decrease contact stresses experienced by articular cartilage. Menisci also function as secondary restraints to anterior/posterior translation of

Figure 1. The Thessaly test consists of internal and external rotation of the body with the knee flexed at 5 and 20 degrees. The examiner can offer assistance by holding the patient's hands for stabilization. Reproduction of symptoms/pain is a positive finding.

Figure 2. The McMurray Test is performed with the patient in the supine position. The examiner places one hand on the heel, which will provide internal and external rotation moments on the tibia. The other hand is free to palpate the medial/lateral knee joint line and serve as a lever for valgus/varus forces. Reproduction of pain or 'clicking' is considered positive.

the tibia with the primary restraint being provided by the cruciate ligaments. The menisci are triangular in cross-section, and predominantly comprised of water, proteoglycans and Type 1 collagen.[6] The medial meniscus is c-shaped with multiple capsular attachments including the medial collateral ligament, making it much less mobile than the lateral meniscus which is more circular and devoid of ligamentous constraint. This disparity in motion contributes to the frequency in which each meniscus is injured. The medial meniscus is injured much more often than the lateral meniscus, with the posterior horn being the most afflicted component. The lateral meniscus is more commonly injured in association with ACL tears. In ACL-deficient knees, the menisci become increasingly important restraints to anterior translation of the tibia, predisposing it to injury. The medial and lateral inferior genicular arteries provide blood supply to the peripheral ¼ to ⅓ of the menisci, with the remaining central portion of the meniscus receiving its nutrition via diffusion from the synovial fluid.[6] The poor vascularity of the central meniscus accounts for its very limited inherent capacity to heal. The menisci have been found to have nociceptor/mechanoreceptor innervation at the peripheral ⅔ and at the anterior and posterior horns from histologic study.[9]

IMAGING

Plain radiographs of the knee provide little information about meniscal pathology. However, they are still valuable initial tests and provide information about bony anatomy and alignment. MRI is the most sensitive diagnostic imaging test available, albeit with a high false positive rate. MRI is often not necessary when osteoarthritis is recognized on plain films or there is a high clinical suspicion for meniscal pathology. On MRI, a linear hyperintensity that extends to the superior or inferior joint surface is diagnostic of a meniscal tear, most sensitively identified on T1 sagittal and coronal slices.[10] Parameniscal cysts visualized on MRI are most often seen in the presence of meniscal tears, so images must be carefully scrutinized when cysts are present. A study performed by Zanetti et al. utilized MRI to evaluate 100 patients that had unilateral symptoms consistent with a meniscal tear.[11] MRIs were performed on the symptomatic and asymptomatic contralateral knee. Meniscal tears were found in 57 of the symptomatic knees and 36 of the asymptomatic knees. [11] Symptoms correlated most with radial, vertical and complex, displaced types of meniscal tears.[11] Another study showed that MRI had a sensitivity of 91.4 percent and specificity of 81.1 percent for identifying medial meniscus tears and a sensitivity and specificity of 76 and 93.3 percent, respectively, for identifying lateral-sided tears.[12] The management of meniscal tears is centered on the presence of symptoms; this study recognizes that a large percentage of meniscal tears are asymptomatic.

TEAR CONFIGURATION

Vertical or longitudinal tears in the sagittal plane, as seen in **Figure 3**, are the most common type of meniscal tear and can be repaired when present in the peripheral third of the meniscus.[6] Radial tears are tears that initiate in the

central portion of the meniscus and propagate to the periphery; they are usually not repairable due to the poor vascularity of this area of the meniscus. When these tears are symptomatic, a partial meniscectomy is indicated. Bucket-handle tears are vertical tears with displacement that can cause mechanical blocks to flexion/extension. Flap and parrot-beak tears are tears that initiate centrally and continue in a circumferential manner.[6]

Figure 3. Meniscal tear patterns
Image Courtesy of Michaela Procaccini

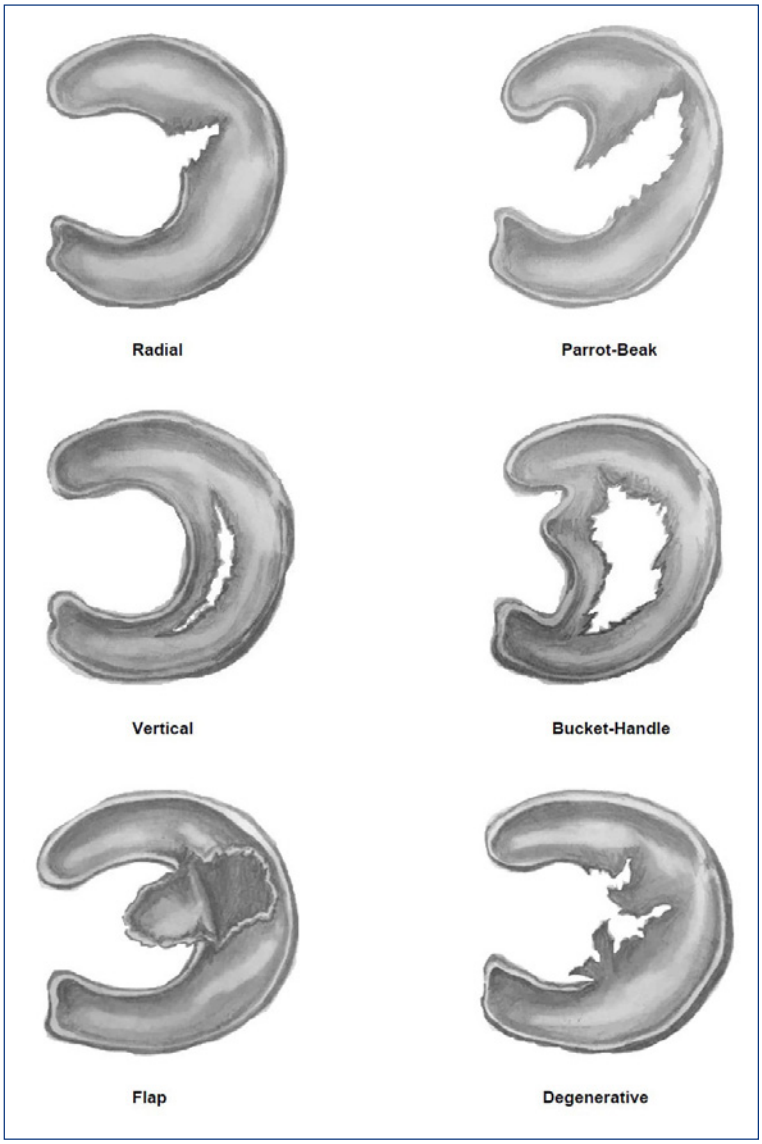

MANAGEMENT

Meniscal tears require treatment when pain is unmanageable or function is impaired. Some meniscal tears are managed successfully without operative intervention. This is typically consistent with small radial tears and stable, nondisplaced longitudinal tears. ACL-deficient knees with no plan for ACL reconstruction and degenerative tears in patients with osteoarthritis are usually not candidates for arthroscopic treatment.[6] Several studies have shown good results from managing certain meniscal tears conservatively with a protocol of ice, NSAIDs, and physical therapy.[13-16] Physical therapy for these injuries focuses on strengthening the muscles of the injured extremity, especially surrounding the knee, as well as maintaining range of motion of the knee and hip.[17-18] Supervised therapy sessions emphasizing exercises such as quadriceps sets, hamstring curls, straight-leg raises, and heel raises have been shown to produce statistically significant improvements in knee pain and functional outcome scores.[17-18] Patients should be encouraged to avoid deep-knee flexion activities that exacerbate their pain such as squatting and kneeling.[17-18] Intra-articular steroid injections can be useful adjuncts to minimize inflammation and suppress symptoms in patients with osteoarthritis. Several studies have shown statistically significant, short-term improvement in pain following an intra-articular steroid injection lasting 2–4 weeks or longer.[13]

Katz et al. performed a randomized controlled trial comparing arthroscopic meniscectomy to a standardized physical therapy regimen in 351 patients 45 years and older with MRI-confirmed meniscal tear and osteoarthritis.[14] This study showed no significant differences in magnitude of improvement in functional status evaluated by Western Ontario and McMaster Arthritis Index (WOMAC) as well as pain at 6 and 12 months after intervention.[14] Moseley et al. compared outcomes after randomization of 180 patients with osteoarthritis and meniscal tears to an arthroscopic debridement, arthroscopic lavage, or placebo surgery group and reported no significant differences in the Knee-Specific Pain Scale at one- and two-year follow-up.[15] Sihvonen et al. evaluated outcomes after random assignment to either arthroscopic partial-meniscectomy or a sham-controlled surgery for patients with symptoms consistent with a degenerative medial meniscus tear without osteoarthritis.[16] There were no significant differences in change from baseline to 12 months in any of the primary outcome scores, regardless of intervention.[16] The effect of various biases, crossover from treatment groups, and the external validity of these trials have recently brought some of these data into question.[19] These studies demonstrate the difficulty practitioners have deciphering whether knee pain is the result of osteoarthritis or a symptomatic meniscal injury, and subsequently determining the appropriate management. However, they do reinforce the importance of attempting conservative management, especially for the older patient with a degenerative tear. Some clues that can help identify the source of pain are the mechanism of injury, radiographic findings consistent with osteoarthritis, and patient demographics.

Patients with large or complex tears, a traumatic mechanism, or a large joint effusion are likely candidates for operative intervention. Severe pain with provocative maneuvers such as the McMurray, Apley, and Steinman tests or any patient with a locked knee are also likely surgical candidates.[6, 20] Patients with persistent symptoms after a period of conservative management should receive orthopedic consultation for either arthroscopy or arthroplasty as appropriate.[6, 20] Operative options include partial meniscectomy, total meniscectomy, meniscal repair, and meniscal transplantation. A partial meniscectomy is by far the most common procedure preferred for centrally located radial tears, complex tears away from the periphery, and degenerative tears.[20]

Peripheral tears that have good vascularity and subsequently a greater likelihood of healing are often better targeted by meniscal repair procedures. [6, 20] This includes longitudinal tears located peripherally, especially in young patients, and tears associated with ACL injury when repaired concomitantly.[20]

Total meniscectomies are rarely performed considering the implication of increased stresses experienced by articular cartilage as well as early degenerative changes.[6] Meniscal transplantation is usually considered after partial or total meniscectomy with persistent symptoms in younger patients that have reached skeletal maturity without arthritic changes of the knee.

CONCLUSION

Meniscal injury is one of the more common musculoskeletal conditions and a frequent cause of knee pain. It is important for physicians to recognize meniscal pathology as a source of knee pain and not solely an MRI finding. Painful tears can be managed conservatively in certain circumstances as well as surgically with success.

References

1. Kim S, Bosque J, Meehan J. P, Jamali A, Marder R. (2011). Increase in outpatient knee arthroscopy in the United States: a comparison of National Surveys of Ambulatory Surgery, 1996 and 2006. *The JBJS. American volume*, *93*(11), 994-1000.
2. Bhattacharyya T, Gale D, Dewire P, Totterman S, Gale M. E, McLaughlin S, Einhorn T, et al. (2003). The clinical importance of meniscal tears demonstrated by magnetic resonance imaging in osteoarthritis of the knee. *The JBJS. American volume*, *85-A*, 4-9.
3. Englund M, Guermazi A, Gale D, Hunter D.J, Aliabadi P, Clancy M, Felson D. (2008). Incidental meniscal findings on knee MRI in middle-aged and elderly persons. *N Engl J Med*, *359*(11), 1108-1115.
4. Snoeker B, Bakker E, Kegel C, Lucas C. (2013). Risk factors for meniscal tears: a systematic review including meta-analysis. *J Orthop Sports Phys Ther*, *43*(6), 352-67.
5. Jones J.C, Burks R, Owens B, Sturdivant R, Svoboda S, Cameron K. (2012). Incidence and risk factors associated with meniscal injuries among active-duty US Military service members. *J Athl Train*, *47*(1), 67-73.
6. Boyer M. (2014). *AAOS Comprehensive Orthopedic Review.* Rosemont, IL: American Academy of Orthopedic Surgeons, 2, 1397-1402.
7. Fowler PJ, Lubliner JA. The predictive value of five clinical signs in the evaluation of meniscal pathology. *Arthroscopy,* 1989;5:184-6.
8. Kocabey Y, Tetik O, Isbell W, Atay O, Johnson D. (2004). The value of clinical examination versus magnetic resonance imaging in the diagnosis of meniscal tears and anterior cruciate ligament rupture. *Arthroscopy*, *20*(7), 696-700
9. McMurray T. The semilunar cartilages. *Br J Surg*, 1942;29:407-14.
10. Sanders T, Miller M. (2005). A Systematic Approach to Magnetic Resonance Imaging Interpretation of Sports Medicine Injuries of the Knee. *Am J Sports Med*, *33*(1), 131-148.
11. Zanetti M, Pfirrmann C, Schmid M, Romero J, Seifert B, Hodler J. (2003). Patients with suspected meniscal tears: Prevalence of abnormalities seen on MRI of 100 symptomatic and 100 contralateral asymptomatic knees. *AJR Am J Roentgenol, 181*(3), 635-641
12. Crawford R, Walley G, Bridgman S, Maffulli N. (2007). Magnetic resonance imaging versus arthroscopy in the diagnosis of knee pathology, concentrating on meniscal lesions and ACL tears: A systematic review. *British Medical Bulletin*.
13. Bellamy N, Campbell J, Robinson V, Gee T, Bourne R, Wells G. (2006). Intraarticular corticosteroid for treatment of osteoarthritis of the knee. *Cochrane Database Syst Rev*, (2), CD005328
14. Katz J, Brophy R, Chaisson C, Chaves L, Cole B, Dahm D, Donnell-Fink L, et al. (2013). Surgery versus physical therapy for a meniscal tear and osteoarthritis. *N Engl J Med, 368*(18), 1675-84.
15. Moseley J, O'Malley K, Petersen N, Menke T, Brody B, Kuykendall D, Hollingsworth J, et al. (2002). A Controlled Trial of Arthroscopic Surgery for Osteoarthritis of the Knee. *N Engl J Med*, 347(2):81-8
16. Sihvonen R, Paavola M, Malmivaara A, Itälä A, Joukainen A, Nurmi H, Kalske J, et al. (2013). Arthroscopic partial meniscectomy versus sham surgery for a degenerative meniscal tear. *N Engl J Med*, *369*(26), 2515-24.
17. Stensrud S. (2012). A 12-Week Exercise Therapy Program in Middle-Aged Patients With Degenerative Meniscus Tears: A Case Series With 1 Year Follow Up. *J Orthop Sports Phys Ther*, *42*(11), 919-931.
18. Yim J, Seon J, Song E, Choi J, Kim M, Lee K, Seo H. (2013). A comparative study of meniscectomy and nonoperative treatment for degenerative horizontal tears of the medial meniscus. *Am J Sports Medicine*, 41:1565–1570.
19. Ha A, Shalvoy R, Voisinet A, Racine J, Aaron R. (2016). Controversial Role of Arthroscopic Meniscectomy of the Knee: A Review. *WJO,* 7(5):287-92.
20. Mordecai S, Al-Hadithy N, Ware H, Gupte C. (2014). Treatment of meniscal tears: An evidence based approach. *WJO, 5*(3), 233-41.

Authors

Jacob Babu, MD, MHA, Resident, Department of Orthopaedics, Alpert Medical School of Brown University, Providence, RI.

Robert M. Shalvoy, MD, Executive Chief of Orthopedic Surgery & Sports Medicine, Care New England Health System, Assistant Professor of Orthopedic Surgery, Alpert Medical School of Brown University, Providence, RI.

Steve B. Behrens, MD, Attending Orthopedic Surgeon, Care New England Health System, Providence, RI.

Correspondence

Jacob Babu, MD
Department of Orthopaedics
Rhode Island Hospital
593 Eddy Street
Providence, RI 02903
401-444-4030
jacob_babu@brown.edu

Understanding Athletic Pubalgia: A Review

BRIAN COHEN, MD; DOMINIC KLEINHENZ, MD; JONATHAN SCHILLER, MD; RAMIN TABADDOR, MD

ABSTRACT

Athletic Pubalgia, more commonly known as sports hernia, is defined as chronic lower abdominal and groin pain without the presence of a true hernia. It is increasingly recognized in athletes as a source of groin pain and is often associated with other pathology. A comprehensive approach to the physical exam and a strong understanding of hip and pelvic anatomy are critical in making the appropriate diagnosis. Various management options are available. We review the basic anatomy, patholophysiology, diagnostic approach and treatment of athletic pubalgia as well as discuss associated conditions such as femoroacetabular impingement.

KEYWORDS: athletic pubalgia, groin pain, sports hernia, impingement

INTRODUCTION

Hip and groin pain has long been a diagnostic dilemma in athletes given the complexity of the anatomy and the multiple sources of pathology. Athletic pubalgia is increasingly identified as a source of pain in athletes as it is becoming more recognized and better understood. Originally termed "Gilmore's groin" over 40 years ago, it has also been known as sportsmen's hernia, groin disruption injury, sports hernia and, most recently, core muscle injury (CMI).[1,2,3,4] The evolution from "hernia" to CMI/athletic pubalgia stems from our developed understanding that there is no true hernia or deficiency from the posterior wall of the inguinal canal but rather an injury to the various structures that comprise the pubic aponeurosis.[4,5,6] Athletic pubalgia can occur in isolation but often occurs in the setting of other hip and pelvic pathology which can make its diagnosis challenging. Although this is much more common in athletes, it can be seen in non-athletes and is referred to simply as pubalgia in this population.

ANATOMY AND PATHOPHYSIOLOGY

The pubic symphysis is believed to act as a fulcrum for the anterior pelvis and, according to Meyers, a majority of pathology stems from this fulcrum point.[7] It is a common attachment site for the rectus abdominus and adductor longus which are confluent and form a sheath anterior to the pubis. The confluence of the rectus abdominus, the conjoint tendon (formed by the internal oblique and transversus abdominus) and external oblique form the pubic aponeurosis, which is also confluent with the adductor and gracilis. The rectus abdominus flexes the trunk, compresses the abdominal viscera, and stabilizes the pelvis for motion at the hip while the adductors stabilize the anterior pelvis. During athletics, a large amount of force occurs at the anterior pelvis in which the pubic symphysis is its center. The opposing forces of the adductor longus directly against the rectus abdominus at the pubic symphysis fulcrum point are thought to be implicated as the origin mechanism of athletic pubalgia. Therefore, when the rectus is weakened, the adductor longus pulls in an unopposed fashion. Typically this is from chronic or acute intense muscle contractions by the athlete while hyperextending and/or twisting the trunk. The inequality of forces acting on the anterior pelvis leads to tearing at the insertion point of the rectus abdominus. (**Figure 1**) Athletic pubalgia is more common in males due to a narrower pelvis that cause greater shifts in force and less stability than the wider female pelvis.[7]

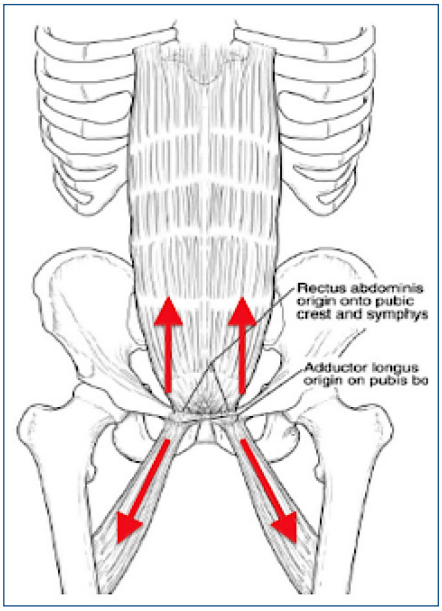

Figure 1. Pathoanatomy of Athletic Pubalgia [7]
The rectus abdominus and adductor longus muscles pull in the opposite direction. With injury to the rectus an imbalance in muscle forces occurs causing groin pain.

PATIENT HISTORY

Chronic lower abdominal and groin pain is increasingly more recognized in high-level athletes. Forces across the pelvis increase as muscle strength increases, which may explain why athletes are commonly affected. Activities that can lead to athletic pubalgia involve running, kicking, cutting

and twisting movements, and explosive turns and changes in direction. In the United States, soccer, ice hockey, and American football players are most commonly affected.[1,8,9]

Athletes usually present with the complaint of exercise-related unilateral lower abdomen and anterior groin pain that may radiate to the perineum, inner thigh, and scrotum. Pain is mostly relieved with rest. However, even with resolution of symptoms after a period of rest, the pain often returns with return to play. Pain can occur gradually, but 71% of athletes will relate the recurrence to a specific event.[1,9] This event can include trunk hyperextension and/or hip hyperabduction leading to increased tension in the pubic region. Kachingwe and Grech explained 5 signs and symptoms that they felt encompassed athletic pubalgia: "(1) a subjective complaint of deep groin/lower abdominal pain, (2) pain that is exacerbated with sport-specific activities such as sprinting, kicking, cutting, and/or sit-ups and is relieved with rest, (3) palpable tenderness over the pubic ramus at the insertion of the rectus abdominus and/or conjoined tendon, (4) pain with resisted hip adduction at 0, 45 and/or 90 degrees of hip flexion, and (5) pain with resisted abdominal curl-up." [9]

PHYSICAL EXAM

One should start palpation laterally at the inguinal ligament and work centrally to the pubic tubercle. It is important to include the pubic symphysis as osteitis pubis can often be present with athletic pubalgia. Exam findings include tenderness at or just above the pubic tubercle near the rectus insertion or hip adductor origin on the affected side. Pain can also be elicited with resisted sit-up and hip flexion. There is no a bulge at the external inguinal ring, or palpable true hernia. Valsalva maneuvers can occasionally reproduce symptoms. One should evaluate the adductor longus as a source of isolated pain by resisted leg adduction in both flexion and extension. This can also exacerbate the rectus abdominus symptoms. Adductor tenderness can be found in as many as 36% of athletes with athletic pubalgia.[1] A sensory exam should be performed as sensory disturbances and dysethesias in the lower abdomen, inguinal region, anteromedial thigh, and genitals can be present with occasional entrapment of the iliohypogastric, ilioinguinal, and genitofemoral nerves.[19] Both hips must be examined for range of motion and provocative maneuvers to rule out isolated findings of intra and extra-articular pathology that can coexist with athletic pubalgia. (**Table 1**)

Table 1. Examination for Groin and Hip

Athletic Pubalgia Test	Maneuver	Interpretation
Resisted Sit up	Patient supine, stabilizes the patient's feet. Arms straight ahead and sit up is performed. Hold for 5 seconds. .	A positive test is when the pain at rectus insertion is reproduced
Single or Bilateral Resisted Leg Adduction	Patient supine, flex leg to 30°. Places hands on the medial aspect of the patient's heel and instructs the patient to resist abduction . This can be done with isolated leg or simultaneously with contralateral leg	A positive test is when this reproduces the patient's pain
Hip Test	**Maneuver**	**Interpretation**
FADIR (Flexion, Adduction, Internal Rotation)	Patient supine, raises leg with hip flexed to 90 degrees and knee flexed to 90 degrees, adduct and internally rotates the hip	Positive if pain, suggest femoral acetabular impingement, labral tear
FABER (Flexion, Abduction, external rotation) (also know as Patrick test)	Patient supine, flex knee to 90 degrees, foot placed on opposite knee places one hand on opposite iliac crest to stabilizes pelvis against table, other hand placed on knee and externally rotates hip	Positive if pain, suggest sacroiliac disorder is pain posterior, if pain in groin suggest femoral acetabular impingement, labral tear, iliopsoas tendinits
Scour	Patient supine , passively flex and adducts the hip and places the knee in full flexion, then downward force along the shaft of the femur is applied while passively adducting/abducting and externally/internally rotating the hip	Positive is pain/catching/clicking must note where in motion the symptom occur, suggest hip labrum, capsulitis, osteochondral defects, acetabular defects, osteoarthritis, avascular necrosisand femoral acetabular impingment syndrome
DEXRIT (Dynamic External Rotatory Impingement Test)	Patient supine with contralateral hip flexed 90 degrees, affected hip flexed and brought through a wide arc of external rotation and abduction, and extension	Positive if pain, suggest femoral acetabular impingement, labral tear
DIRIT (Dynamic Internal Rotatory Impingement Test)	Patient supine with the contralateral hip flexed 90 degrees, affected hip flexed and brought through a wide arc of internal rotation and adduction, and extension	Positive if pain, suggest femoral acetabular impingement, labral tear

FEMOROACETABULAR IMPINGEMENT (FAI) AND OTHER ASSOCIATED CONDITIONS

Many disorders around the hip and pelvis can coexist with athletic pubalgia making diagnosis difficult. These include acetabular labral tears, adductor injuries, snapping hip syndromes, iliopsoas tendonitis, osteitis pubis, and femoroacetabular impingement. (**Figure 2**) One must rule out a true

Figure 2. Demonstration of a Pincer and Cam lesion

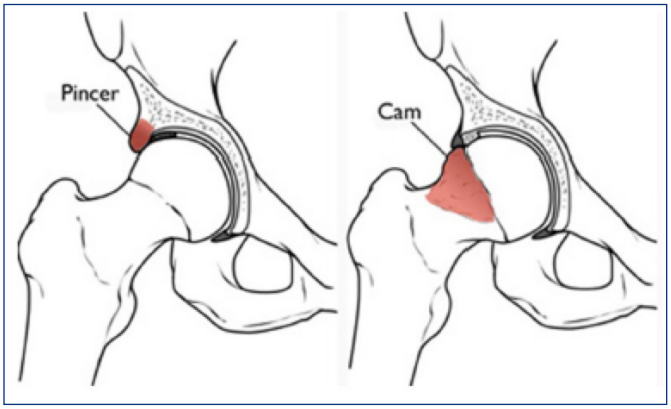

(Reproduced with permission from the American Academy of Orthopedic Surgeons)

Figure 3. Common X-ray findings Associated with Athletic Pubalgia
Anteroposterior pelvic radiograph in a collegiate hockey player with clinical examination consistent with intra-articular hip and athletic pubalgia symptoms reveals bilateral cam type de-formities (solid arrow), acetabular retroversion (dashed curved line), and osteitis pubis (dashed arrow).

Reprinted with permission from SAGE Publications, Thousands Oaks, CA. All permission requests for this image shoulder be made to copyright holder.

groin hernia, genitourinary and gynecological disorders, and intra-abdominal sources of pain that can mimic athletic pubalgia symptoms.

Recent literature has suggested a strong relationship between athletic pubalgia and FAI. Addressing one or the other independently may not resolve symptoms completely. Femoroacetabular impingement is defined as an abnormal contact between the femoral neck and the acetabular rim during terminal motion of the hip due to excessive bone on the acetabular rim, the femoral neck or both. [12] (**Figure 2 and 3**) Limited range of motion associated with FAI can lead to compensatory patterns of movement around the pelvis and trunk.[13] In a cadaveric study, Birmingham showed that cam morphology restricts hip motion and results in increased stress and motion on the pubic symphysis. This causes excessive strain at these joints and on the muscles that attach to them predisposing patients to athletic pubalgia.[14] Therefore, treatment of FAI may normalize hip motion which can restore core and pelvic mechanics.[15]

Multiple studies have shown that the treatment of athletic pubalgia alone may lead to poorer results and inability to return to play. Larson showed that pubalgia surgery alone allowed only 25% of patients to return to the previous level of sport, whereas arthroscopic treatment of FAI alone resulted in a 50% return to the previous level. However, when both conditions were surgically treated, 89% returned to sports.[13] Hammound reported similar findings with no patients returning to sport after athletic pubalgia surgery alone.[15]

Proximal adductor tendonopathy is often associated with athletic pubalgia and FAI. One study showed that 94% of athletes with adductor-related pain had radiographic signs of FAI.[10] Patients may also develop osteitis pubis, a stress injury to the perisymphyseal pubic bones secondary to increased strain on the anterior pelvis, and internal snapping hip syndrome, an iliopsoas tendinitis resulting from irritation of a tight iliopsoas tendon snapping over the iliopectineal eminence as the hip moves from flexion to extension.[1] Intra-articular hip pathology that may produce similar symptoms to athletic pubalgia include synovitis, loose bodies, osteoarthritis, avascular necrosis and torn acetabular labrum.

DIAGNOSTIC IMAGING AND DIAGNOSTIC INJECTIONS

Radiographic evaluation includes a standing anteroposterior (AP) pelvis and lateral hip radiographs. One should look for intra-articular disorders including FAI, arthritis, loose bodies and acetabular dysplasia. Extra-articular pathology that may be visible on radiographs includes osteitis pubis, acute or chronic pelvic avulsion fractures/apophyseal injuries and fractures. Magnetic resonance imaging (MRI) of the pelvis is important to obtain for suspicion of athletic pubalgia and other already discussed pathology, although a dedicated hip MR arthrogram should be performed if there is specific concern for hip pathology such as FAI and labral tears. Concern for athletic pubalgia should be specified in the history. Tears of the rectus abdominus on MRI are uncommon. When a tear is seen, it is essentially pathognomonic for athletic pubalgia. Zoga found MRI to be 68% sensitive and 100% specific for rectus abdominus pathology when compared with findings at surgery. Rectus disruptions are seen as a cleft sign with increased signal on T2-weighted images at the rectus abdominus/adductor aponeurosis. (**Figure 4**) Also, MRI is 86% sensitive and 89% specific for adductor pathology and 100% sensitive for osteitis pubis.[16]

Diagnostic intra- and extra-articular injections of local anesthetic and/or corticosteroid can be helpful to make a diagnosis. This can be done either fluoroscopically or ultrasound guided. Injection of the hip joint followed by provocative maneuvers can be used to distinguish hip from pelvic pain. Continued pain in the lower abdominal/

Figure 4. MRI of Pelvis

Magnetic resonance imaging of the hip and pelvis in 22-year-old Division 1 football player with left sided lower abdominal and proximal adductor related pain reveals a disruption of the distal rectus abdominus/adductor aponeurosis on the left (solid arrow).

Reprinted with permission from SAGE Publications, Thousands Oaks, CA. All permission requests for this image shoulder be made to copyright holder.

Figure 5. Algorthrim for Treatment of Athletic Pubalgia

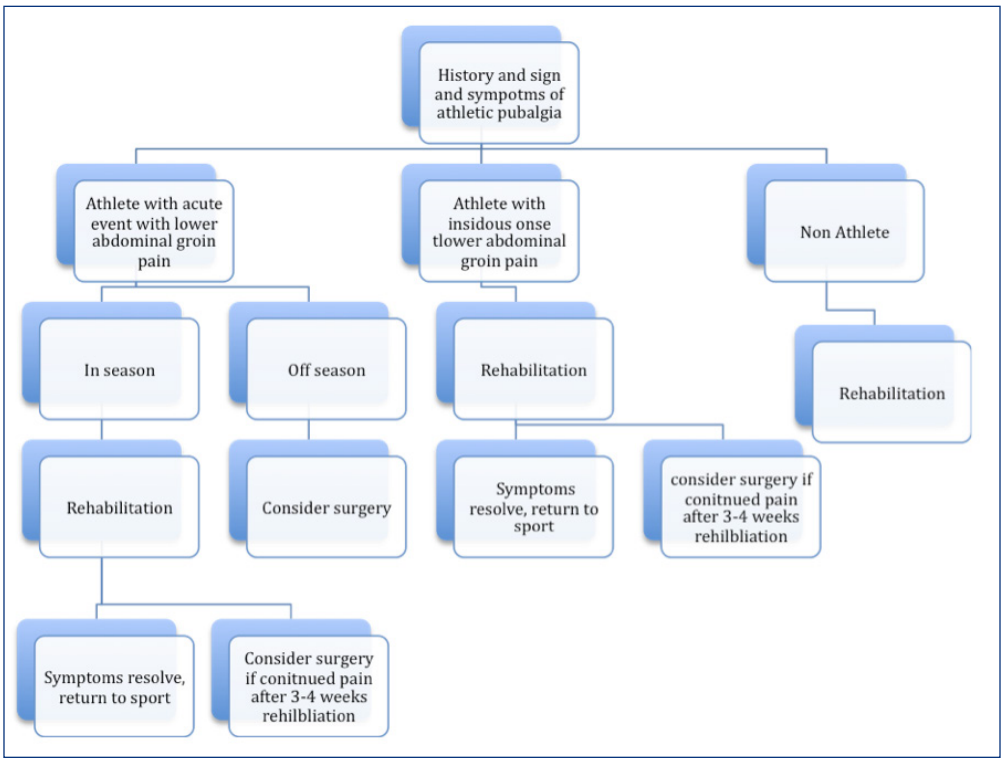

adductor regions, despite an intra-articular injection, can help diagnose athletic pubalgia. Pubic symphysis injections can be performed when osteitis pubis is suspected. Pubic cleft and psoas bursal injections can also be performed for adductor and psoas-related pain, respectively.

CONSERVATIVE TREATMENT

Rehabilitation with physical therapy is first-line treatment for most patients with athletic pubalgia. However, treatment should be individualized based on the level of the athlete, the length of time before the athlete is expected to return to play, and timing of sport season. (**Figure 5**) Physical therapy should include core strengthening and stabilization, restoration of pelvic tilt and postural training. Increasing range-of-motion of the hip should be done with caution in patients with underlying hip pathology/FAI as changes in the pelvic motion may increase the patient's symptoms. Generally, conservative treatment should be attempted for 3 months before considering surgery. In-season athletes can trial a 4-week period of rest. Pharmacological treatments include nonsteroidal anti-inflammatories and oral steroid taper. Injections include selective corticosteroid or platelet-rich plasma injections into the rectus abdominus and/or adductor longus origin. After this rest period, return to sport can be trialed. If pain continues, it is up to the athlete whether or not to return to play. Return to play is not believed to worsen the tear or the surgical results of repair.[17] Paajanen compared nonsurgical treatment consisting of physical therapy and corticosteroid injections with surgical treatment for athletes with chronic groin pain. Twenty-three percent of patients in the nonsurgical group crossed over into the surgical arm due to continued pain. Only 50% of the nonsurgical patients returned to sport at 1-year. At 1-year follow-up, 97% of patients in the surgical group were pain free and returned to full sport.[18]

SURGICAL TREATMENT

If the athlete has continued pain despite a trial of nonsurgical management, surgery may be warranted. Athletes should be referred for evaluation to an orthopedic or general surgeon who is familiar with the recognition, treatment and management of athletic pubalgia. Multiple operations and

techniques including laparoscopic and open procedures exist which make it difficult to compare outcomes. Most techniques have satisfactory results reported in the literature. Principles of operative management include reinforcement of the posterior wall and fixation of the rectus abdominus or conjoint tendon. Most also recommend adductor tenotomy when adductor pain and dysfunction is present. Femoroacetabular surgery should also be considered accordingly if recognized as a contributing issue, as previously discussed. A full return to sport is expected at about 6–8 weeks if an isolated athletic pubalgia repair is performed and 4 months if FAI surgery is concomitantly done.[17]

SUMMARY

Though referred to as many names in the literature, chronic lower abdominal and groin pain without a true hernia is known as athletic pubalgia. It is most commonly seen in male athletes. The pathophysiology is based on weakening or tearing of the lower abdominal or adductor muscles and their opposing forces on the pubic bone. Symptoms include exercise-related unilateral lower abdominal and anterior groin pain that is relieved with rest. Examination shows tenderness at or just above the pubic tubercle near the rectus insertion and pain with a resisted sit-up. Intra-articular hip, genitourinary, and intra-abdominal pathology, as well as gynecological sources of pain in women, must be ruled out. FAI has been shown to be associated with athletic pubalgia and addressing both pathologies may be necessary for complete relief. Plain radiographs, pelvic MRI, and diagnostic injection should used to help make a diagnosis. Conservative treatment is the mainstay and physical therapy should be tried prior to any surgery. However, the timing and length of therapy should be individualized to the athlete. With failure of conservative treatment, referral to a specialist should be made for repair. Results of surgical treatment allow most athletes to return to play at 6 weeks.

References

1. Meyers C, Foley D, Garrett W, Lohnes J, Mandlebaum B. Management of severe lower abdominal or inguinal pain in high-performance athletes. PAIN (Performing Athletes with Abdominal or Inguinal Neuromuscular Pain Study Group). *Am J Sports Med.* 2000 Feb;28(1):2–8.
2. Gilmore J. Groin pain in the soccer athlete: fact, fiction, and treatment. *Clin Sports Med.* 1998 Oct;17(4):787–793, vii.
3. Garvey J, Hazard H. Sports hernia or groin disruption injury? Chronic athletic groin pain: a retrospective study of 100 patients with long-term follow-up. Hernia J *Hernias Abdom Wall Surg*. 2014;18(6):815–23.
4. Taylor D, Meyers W, Moylan J, Lohnes J, Bassett F, Garrett W. Abdominal musculature abnormalities as a cause of groin pain in athletes. Inguinal hernias and pubalgia. *Am J Sports Med.* 1991 Jun;19(3):239–42.
5. Polglase A, Frydman G, Farmer K. Inguinal surgery for debilitating chronic groin pain in athletes. *Med J Aust.* 1991 Nov 18;155(10):674–7.
6. Malycha P, Lovell G. Inguinal surgery in athletes with chronic groin pain: the "sportsman's" hernia. *Aust N Z J Surg.* 1992 Feb;62(2):123–5.
7. Meyers W, Greenleaf R, Saad A. Anatomic basis for evaluation of abdominal and groin pain in athletes. *Oper Tech Sports Med.* 2005 Jan;13(1):55–61.
8. Nam A, Brody F. Management and therapy for sports hernia. *J Am Coll Surg.* 2008 Jan;206(1):154–64.
9. Kachingwe A, Grech S. Proposed algorithm for the management of athletes with athletic pubalgia (sports hernia): a case series. *J Orthop Sports Phys Ther*. 2008 Dec;38(12):768–81.
10. Weir A, de Vos R, Moen M, Hölmich P, Tol J. Prevalence of radiological signs of femoroacetabular impingement in patients presenting with long-standing adductor-related groin pain. *Br J Sports Med.* 2011 Jan;45(1):6–9.
11. Meyers W, Lanfranco A, Castellanos A. Surgical management of chronic lower abdominal and groin pain in high-performance athletes. *Curr Sports Med Rep*. 2002 Oct;1(5):301–5.
12. Beck M, Kalhor M, Leunig M, Ganz R. Hip morphology influences the pattern of damage to the acetabular cartilage: femoroacetabular impingement as a cause of early osteoarthritis of the hip. *J Bone Joint Surg Br*. 2005 Jul;87(7):1012–8.
13. Larson C, Pierce B, Giveans M. Treatment of athletes with symptomatic intra-articular hip pathology and athletic pubalgia/sports hernia: a case series. *Arthrosc J Arthrosc Relat Surg Off Publ Arthrosc Assoc N Am Int Arthrosc Assoc.* 2011 Jun;27(6):768–75.
14. Birmingham P, Kelly B, Jacobs R, McGrady L, Wang M. The effect of dynamic femoroacetabular impingement on pubic symphysis motion: a cadaveric study. *Am J Sports Med.* 2012 May;40(5):1113–8.
15. Hammoud S, Bedi A, Magennis E, Meyers W, Kelly B. High incidence of athletic pubalgia symptoms in professional athletes with symptomatic femoroacetabular impingement. *Arthrosc J Arthrosc Relat Surg Off Publ Arthrosc Assoc N Am Int Arthrosc Assoc.* 2012 Oct;28(10):1388–95.
16. Zoga A, Kavanagh E, Omar I, Morrison W, Koulouris G, Lopez H, et al. Athletic pubalgia and the "sports hernia": MR imaging findings. *Radiology.* 2008 Jun;247(3):797–807.
17. Litwin D, Sneider E, McEnaney P, Busconi B. Athletic Pubalgia (Sports Hernia). *Clin Sports Med.* 2011 Apr;30(2):417–34.
18. Paajanen H, Brinck T, Hermunen H, Airo I. Laparoscopic surgery for chronic groin pain in athletes is more effective than nonoperative treatment: a randomized clinical trial with magnetic resonance imaging of 60 patients with sportsman's hernia (athletic pubalgia). *Surgery.* 2011 Jul;150(1):99–107.
19. Larson C. Sports hernia/athletic pubalgia: evaluation and management. *Sports Health.* 2014 Mar;6(2):139–44.

Authors

Brian Cohen, MD, Department of Orthopedics, The Warren Alpert Medical School of Brown University.

Dominic Kleinhenz, MD, Department of Orthopedics, The Warren Alpert Medical School of Brown University.

Jonathan Schiller, MD, Department of Orthopedics, The Warren Alpert Medical School of Brown University.

Ramin Tabaddor, MD, Ortho Rhode Island, 1567 South County Trail, East Greenwich, RI 02818.

Correspondence

Brian Cohen, MD
Department of Orthopedics
Rhode Island Hospital
593 Eddy Street
Providence, RI 02903
bharriscohen@gmail.com