Selective Laser Trabeculoplasty as Primary Treatment for Open-Angle Glaucoma

LAITH M. KADASI, MD; SAFA WAGDI, MD; KIMBERLY V. MILLER, MD

ABSTRACT

Open-angle glaucoma is a silent, chronic disorder which results in progressive and permanent vision loss. Designing the optimal treatment regimen can be particularly challenging in the management of high-risk patients with frequent loss to follow-up or a longstanding history of medication noncompliance. In this article we aim to review fundamental techniques in glaucoma diagnosis and treatment with emphasis on the strengths and weaknesses of selective laser trabeculoplasty, a technique in modern therapy which may mold the future of primary treatment in open angle glaucoma management.

KEYWORDS: selective laser trabeculoplasty, glaucoma, laser surgery

INTRODUCTION

Glaucoma can be defined as a group of diseases that features a progressive optic neuropathy accompanied by characteristic visual field changes, with or without increased intraocular pressure. The most common form, primary open-angle glaucoma (POAG) is a disease that affects more than 2 million individuals in the United States, and is projected to increase to more than 3 million by 2020.[1] It is characterized by a progressive, excavated optic neuropathy and is associated with stereotyped patterns of irreversible visual field loss which can eventually lead to blindness. Although the primary risk factors for this disease include the elevation of intraocular pressure (IOP), the presence or absence of ocular hypertension does not have a role in the definition of glaucoma itself. This article will review our current understanding of glaucoma diagnosis as well as an analysis of the benefits and weaknesses of selective laser trabeculoplasty, a technique in modern therapy which may mold the future of primary treatment in open-angle glaucoma management.

DIAGNOSIS

The identification of glaucoma can be challenging and requires careful assessment of multiple factors and diagnostic tests in order to establish POAG as a definitive diagnosis. Patients are often first established as glaucoma suspects on the basis of risk factors and receive an official designation of open-angle glaucoma following the assessment of IOP, gonioscopy, visual field deficits, and detailed assessment of the optic nerve and retinal nerve fiber layer itself.

Risk Factors

Accepted risk factors in primary open-angle glaucoma include race, specifically African and to a lesser extent Hispanic ancestry, advanced age, elevated intraocular pressure, cup-to-disc ratio, decreased central corneal thickness, and family history of glaucoma.[15-17] Diabetes mellitus has a strong association with open-angle glaucoma, but remains controversial as a risk factor due to conflicting findings as an independent risk factor for disease among major studies.[15,17]

Optic Nerve Assessment

In visualization of the optic nerve using ophthalmoscopy, it is beneficial to evaluate not only the cup-to-disc ratio, but also the distribution of tissue around the margin of the optic disc such as vertical cupping.[15,16] Referral for ophthalmologic consultation in patients with an elevated cup-to- disc ratio or an atypical distribution of neuroretinal tissue at the optic disc will enable further assessment with Optical Coherence Tomography (OCT), an increasingly valuable screening tool which facilitates in the quantification of the retinal nerve fiber layer and ganglion cell layer of the retina, and can result in earlier detection of tissue loss in glaucoma suspects prior to the onset of visual field changes.[3]

Goldmann Applanation Tonometry

The gold standard for obtaining the IOP measurement is via Goldmann Applanation Tonometry (GAT).[20] This test requires the application of a prism mounted on the head of a tonometer against the corneal surface. The tonometer interface viewed by the clinician, adjusting the force applied to the tonometer head until the device indicates the force in mmHg necessary to flatten a 3.06mm diameter portion of the corneal surface. Ocular hypertension is considered pressure greater than 21mmHg. Alternative methods of intraocular pressure measurement are frequently used such as Pascal and ICare tonometry with concordance.[18] These methods are more susceptible to error associated with abnormalities in corneal curvature and central corneal thickness, respectively.

Figure 1. Photograph of the iridocorneal angle during gonioscopy. This image depicts an open angle with visualization of anatomical structures: **A:** Schwalbe's Line, **B:** Nonpigmented Trabecular Meshwork, **C:** Pigmented Trabecular Meshwork, **D:** Scleral Spur, **E:** Iris.



Gonioscopy

Direct visualization of the anterior chamber angle is limited due to the phenomenon of total internal reflection. For this reason mirrors are applied in indirect gonioscopy to reflect light from the iridocorneal angle, allowing complete visualization of the trabecular meshwork in order to identify alternative causes of glaucomatous damage (**Figures 1 and 2**). This analysis includes identifying the presence or absence of neovascularization, or dense pigment deposition as seen in secondary open-angle glaucomas such as pigment dispersion or pseudoexfoliation. Furthermore, obscuration of angle structures can be seen in anatomically narrow angles, predisposing these patients towards angle closure glaucoma.

Visual Field

The gold standard for objective visual field assessment in glaucoma is known as automated static threshold perimetry. Visual field abnormalities do not appear until a substantial volume of ganglion cells are lost.[3,19] Although several alternative methods of visual field measurement are available with variable sensitivity, Humphrey Visual Field testing remains the standard of care for glaucoma patients. Monitoring of characteristic visual field changes and progression remains a mainstay of glaucoma treatment.

Figure 2. Schematic of indirect gonioscopy. This image depicts the method in which gonioscopy can be used to view a reflection of the iridocorneal angle.

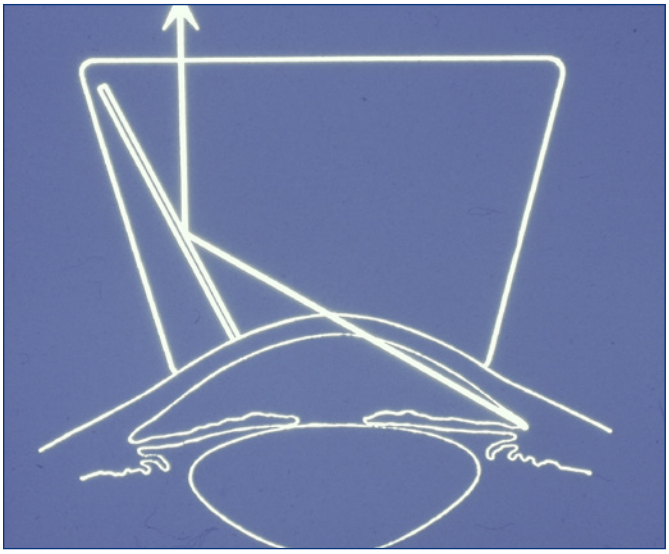

MANAGEMENT

Although the pathogenesis of glaucoma remains poorly understood, successful treatment strategies at this time are directed toward lowering intraocular pressure due to a strong association with delay in the progression of glaucoma in treated patients.[2] As a result, predominant trials in open-angle glaucoma therapy over the past several decades have been directed towards comparison among pressure lowering therapy in the form of topical medications, surgery, and laser trabeculoplasty.[4-14] Designing the optimal treatment regimen can be particularly challenging in the management of high risk patients with frequent loss to follow-up or a long-standing history of medication noncompliance.

Traditionally, open-angle glaucoma treatment is initiated with topical medications (**Table 1**), with the eventual consideration of treatment alternatives if there is failure to respond or medication noncompliance.[11] The glaucoma laser trials supported consideration of a "laser first" approach due to the illustration that initial laser therapy was equally effective to topical therapy in direct comparison.[6] These

Table 1. Topical Glaucoma Medications and Systemic Side Effects

Drug Class	Common Topical Agents	Common Systemic Effects
Alpha 2 Adrenergic Agonists	Apraclonidine, Brimonidine	Dizziness, Fatigue, Headache, Insomnia, Myalgia, Nausea, Xerostomia
Beta Adrenergic Antagonists	Betaxolol, Cartelol, Levobunolol, Metipranolol, Timolol	Bradycardia, Bronchospasm, CNS Depression, Heart Block, Hypotension
Carbonic Anhydrase Inhibitors	Brinzolamide, Dorzolamide	Acidosis, Blood Dyscrasias, Depression, Diarrhea, Hypokalemia, Nephrolithiasis
Parasympatho-mimetic Agents	Pilocarpine	Abdominal Cramps, Increased Salivation
Prostaglandin Analogues	Bimatoprost, Latanoprost, Travoprost	Arthralgia, Malaise, Headache

trials took place using an older method of therapy known as argon laser trabeculoplasty (ALT), which has been mostly replaced by a newer and safer alternative, selective laser trabeculoplasty (SLT).

Selective Laser Trabeculoplasty

Due to its extremely favorable safety and efficacy profile, SLT has gained acceptance as a mainstay in open-angle glaucoma management.[4,5] In the coming decade, SLT is likely to become the primary therapy of choice in open-angle glaucoma, due to the safety and cost effectiveness of the procedure, the decreased burden of compliance on patients when compared with traditional therapies, and the ease with which retreatment and traditional operative interventions can be performed in post-procedural patients.

An important consideration in laser therapy safety and cost is the duration of procedure efficacy. Approximately 50% of eyes have been found to fail after SLT following a 2-year period, requiring retreatment.[13,14] Selective Laser Trabeculoplasty remains a relatively young technique with limited data regarding the effects of repeated therapy over a 10-20 year course. These effects must be weighed against the adverse effects of long-term medication or multiple glaucoma surgeries, as patients using topical therapy for long periods of time frequently experience chemical irritation and delayed hypersensitivity reactions such as dermatoconjunctivits medicamentosa. Similarly, traditional glaucoma surgeries have high complication and vision loss rates, making their use limited in early and moderate stage disease. Thus far the side effect profile of SLT compares favorably to those of medical therapy or surgical options, with an absence of systemic adverse effects and elimination of the procedural risks associated with operative monitored anesthesia care or general anesthesia in surgical patients. SLT has been associated with mild post-procedural redness, photophobia, and discomfort in the setting of transient anterior chamber inflammation with reported incidences ranging from 0% to 66%.[7] A transient, 12-24 hour paradoxical increase in intraocular pressure has also been noted, which can be addressed prophylactically with IOP-lowering medications.[4] Isolated observations of very rare complications such as peripheral anterior synechiae, hyphema, and corneal edema have also been described.[8-10] Cost comparison studies directly assessing medical therapy and primary SLT over a 6-year horizon while assuming perfect drop administration efficiency rates have also found savings ranging from $200-3000 per patient, including adjustment for the potential need for retreatment every 2-3 years.[12]

The decreased burden of compliance on patients is perhaps the strongest factor in considering SLT in this lifelong disease. A patient on bilateral maximal medical therapy using a combined ophthalmic preparation such as dorzolamide-timolol in addition to an alpha agonist and prostaglandin analog may be required to administer as many as 6 drops daily for life; if these drops are administered correctly the patient would wait 5 minutes following each when medication administration times coincide. In the presence of comorbid osteoarthritis, incoordination, or postural limitations the decreased efficiency of medication administration will further contribute to increased medical cost due to medication wasting and noncompliance.

CONCLUSION

Open-angle glaucoma is a devastating disease that presents many unique challenges in diagnosis and management. As the technique of SLT matures there will be an increasing body of evidence in support of the use of this technique as primary therapy.

References

1. Eye Diseases Prevalence Research Group. "Prevalence of open-angle glaucoma among adults in the United States." *Archives of ophthalmology*122.4 (2004): 532.
2. Heijl, Anders, et al. "Reduction of intraocular pressure and glaucoma progression: results from the Early Manifest Glaucoma Trial." *Archives of ophthalmology* 120.10 (2002): 1268-1279.
3. Kuang, Tammy M., et al. "Estimating Lead Time Gained by Optical Coherence Tomography in Detecting Glaucoma before Development of Visual Field Defects." *Ophthalmology* 122.10 (2015): 2002-2009.
4. Latina, Mark A., et al. "Q-switched 532-nm Nd: YAG laser trabeculoplasty (selective laser trabeculoplasty): A multicenter, pilot, clinical study11;Dr. Mark A. Latina has financial interest in this technology." *Ophthalmology*105.11 (1998): 2082-2090.
5. Damji, Karim F., et al. "Selective laser trabeculoplasty vargon laser trabeculoplasty: a prospective randomised clinical trial." *British journal of ophthalmology* 83.6 (1999): 718-722.
6. Glaucoma Laser Trial Research Group. "The Glaucoma Laser Trial (GLT) and glaucoma laser trial follow-up study: 7. Results." *American Journal of Ophthalmology* 120.6 (1995): 718-731.

7. Wong MO, Lee JW, Choy BN, et al. Systematic review and meta-analysis on the efficacy of selective laser trabeculoplasty in open-angle glaucoma. *Surv Ophthalmol*. 2015; 60: 36–50.
8. Rhee DJ, Krad O, Pasquale LR. Hyphema following selective laser trabeculoplasty. *Ophthalmic Surg Lasers Imaging*. 2009; 40: 493–494.
9. Wong MO, Lee JW, Choy BN, et al. Systematic review and meta-analysis on the efficacy of selective laser trabeculoplasty in open-angle glaucoma. *Surv Ophthalmol*. 2015; 60: 36–50.
10. Knickelbein JE, Singh A, Flowers BE, et al. Acute corneal edema with subsequent thinning and hyperopic shift following selective laser trabeculoplasty. *J Cataract Refract Surg*. 2014; 40: 1731–1735.
11. Lee, David A., and Eve J. Higginbotham. "Glaucoma and its treatment: a review." *American journal of health-system pharmacy* 62.7 (2005).
12. Lee, Richard, and Cindy ML Hutnik. "Projected cost comparison of selective laser trabeculoplasty versus glaucoma medication in the Ontario Health Insurance Plan." *Canadian Journal of Ophthalmology/Journal Canadien d'Ophtalmologie* 41.4 (2006): 449-456.
13. Weinand FS, Althen F. Long-term clinical results of selective laser trabeculoplasty in the treatment of primary open angle glaucoma. *Eur J Ophthalmol*. 2006; 16: 100–104.
14. Bovell AM, Damji KF, Hodge WG, et al. Long-term effects on the lowering of intraocular pressure: selective laser or argon laser trabeculoplasty? *Can J Ophthalmol*. 2011; 46: 408–413.
15. Gordon, Mae O., et al. "The Ocular Hypertension Treatment Study: baseline factors that predict the onset of primary open-angle glaucoma." *Archives of ophthalmology* 120.6 (2002): 714-720.
16. Quigley, Harry A. "European glaucoma prevention study." *Ophthalmology*112.9 (2005): 1642-1643.
17. AGIS investigators. "The Advanced Glaucoma Intervention Study (AGIS): 12. Baseline risk factors for sustained loss of visual field and visual acuity in patients with advanced glaucoma." *American journal of ophthalmology* 134.4 (2002): 499-512.
18. Johannesson, Gauti, et al. "Pascal ICare and Goldmann applanation tonometry–a comparative study." *Acta ophthalmologica* 86.6 (2008): 614-621.
19. Williams, Zinaria Y., et al. "Optical coherence tomography measurement of nerve fiber layer thickness and the likelihood of a visual field defect." *American journal of ophthalmology* 134.4 (2002): 538-546.
20. Goldmann H and Schmidt T (1957): Applanation tonometry. Ophthalmologica 134:221–242.

Authors

Laith M. Kadasi, MD, Department of Ophthalmology, Alpert Medical School of Brown University; Rhode Island Hospital, Providence, RI.

Safa Wagdi, MD, Clinical Assistant Professor of Surgery (Ophthalmology), Alpert Medical School of Brown University; Rhode Island Hospital, Providence, RI.

Kimberly V. Miller, MD, Clinical Assistant Professor of Surgery (Ophthalmology), Alpert Medical School of Brown University; Rhode Island Hospital, Providence, RI.

Disclosures

None

Correspondence

Laith M. Kadasi, MD
Alpert Medical School of Brown University/ Rhode Island Hospital
Department of Ophthalmology
1 Hoppin Street, Suite 200
Providence, RI 02903
401-444-5509
Fax 401-444-7076
Laith.Kadasi@gmail.com