Unilateral Greater Occipital Nerve Compression Causing Scalp Numbness

ELISA R. WING, BA, MD'16; BRIAN R. OTT, MD

KEYWORDS: greater occipital nerve, nerve compression, scalp numbness, occipital neuralgia

INTRODUCTION

The most common disorder of the greater occipital nerve is occipital neuralgia, manifested as pain related to compression or irritation of the nerve,[1] but here we present an unusual case of greater occipital nerve compression resulting in unilateral scalp numbness.

CASE PRESENTATION

A 50-year-old male developed a painless swelling over the scalp of the right occiput following an ablative cardiac procedure. Upon waking from general anesthesia, he noticed a "bump" on the back of his head and complete loss of sensation over his right scalp, extending rostrally to behind the hairline, caudally to the nuchal line, medially to the midline, and laterally to above the ear. He also had a new soft tissue mass over his right occiput. He denied hearing loss, tinnitus, visual disturbances, or difficulty speaking or swallowing.

On physical examination, the right scalp was hypesthetic to light touch, pinprick, temperature, and vibration over the involved region. The left scalp, however, had intact sensation in all modalities. Over the right occiput, there was a mass measuring approximately 4 cm x 2 cm with overlying erythema. It was tense, non-fluctuant, and tender to palpation.

The patient was treated with warfarin, and his INR was found to be supratherapeutic to 4.7. A CT scan of head and neck showed swelling and increased subcutaneous stranding over the right occiput, rather than hematoma formation, and a known stable lipoma over the left occiput.

No intervention was undertaken to relieve the swelling. After 4 weeks, he reported that the swelling had completely resolved and the symptoms of sensory loss had subsided to approximately 80% of normal.

DISCUSSION

A hematoma was suspected due to the mass's appearance and the patient's supratherapeutic INR, but imaging suggested that the mass was mainly composed of soft tissue

Figure 1. Patient's right occiput 24 hours after development of mass and right scalp numbness.

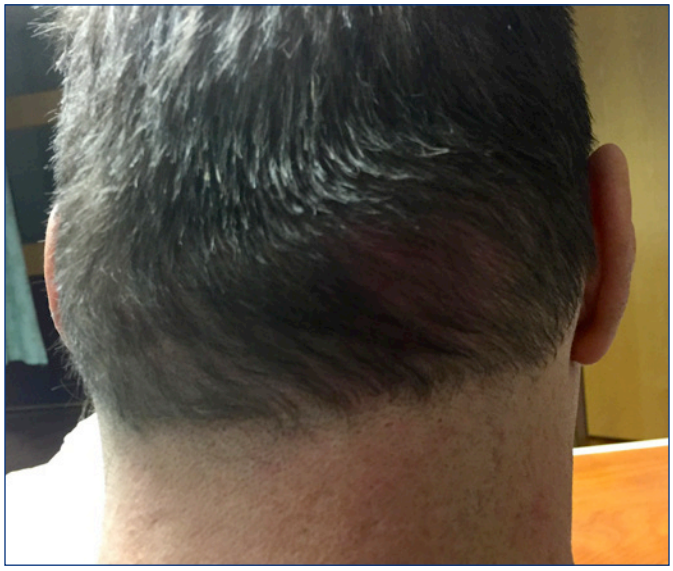

Figure 2. CT scan demonstrating swelling and increased subcutaneous stranding over the right occiput.

swelling and inflammation. We believe that the swelling was related to trauma and subsequently caused compression of the greater occipital nerve. This nerve is derived from the C2 nerve root and provides superficial sensory innervation of the posterior scalp extending rostrally to meet the territory innervated by trigeminal cranial nerve V1. The greater occipital nerve becomes superficial after insertion in the trapezius muscle at the nuchal line. It also has a close relationship with the occipital artery, which alone can compress the nerve or be the source of bleeding in a hematoma.[2]

A literature review yielded one case of an obese 48-year-old woman who developed bilateral occipital neuropathy following a 4-hour thyroid surgery during which her neck was extended.[3] Her bilateral scalp numbness and pain resolved completely by 6 weeks. This case as well as ours suggest that post-operative compressive neuropathies of the occipital nerve carry a good prognosis and would be expected to resolve spontaneously without any residual deficits. Ensuring appropriate positioning and padding during prolonged time under anesthesia may reduce the risk of developing occipital nerve compression, though no specific risk factors, other than perhaps anatomic variation, have been identified.

Acknowledgment

The authors would like to thank Dr. Nadia Shaikh for her help in the conception of this piece.

References

1. Vanelderen Pascal, Arno Lataster, Robert Levy, Nagy Mekhail, Maarten Van Kleef, Jan Van Zundert. "8. Occipital Neuralgia." *Pain Practice.* 10.2 (2010):137-44.
2. Jeffrey E. Janis, MD; Daniel A. Hatef, MD; Ivica Ducic, MD, PhD; Edward M. Reece, MD, MS; Adam H. Hamawy, MD; Stephen Becker, MD; Bahman Guyuron, MD. "The Anatomy of the Greater Occipital Nerve: Part II. Compression Point Topography." *Plastic and Reconstructive Surgery* 5.126 (2010):1563-572.
3. Schulz-Stübner S. "Bilateral Occipital Neuropathy as a Rare Complication of Positioning for Thyroid Surgery in a Morbidly Obese Patient." *Acta Anaesthesiologica Scandinavica* 48.1 (2004): 126-27.

Authors

Elisa R. Wing, BA, is a 2016 MD candidate at the Warren Alpert Medical School of Brown University, Providence, RI.

Brian R. Ott, MD, is a Professor in the Department of Neurology at the Warren Alpert Medical School of Brown University, Providence, RI, and Director of The Alzheimer's Disease & Memory Disorders Center at Rhode Island Hospital, Providence, RI.

Disclosures

None

Correspondence

Elisa Wing
Alpert Medical School
222 Richmond St., Box G-9566
Providence, RI 02903
elisa_wing@brown.edu