Pulmonary Zygomycosis in a Diabetic Patient: Treated with Pneumonectomy and Antifungal Agents

AHMED MAHMOOD, MD; MICHAEL CHAUMP, MD; BETTINA KNOLL, MD; BASSAM ASWAD, MD

A 47-year-old woman with diabetes type II, asthma, managed with albuterol and inhaled steroids, and a history of laparoscopic gastric bypass six years ago, presented to her primary care provider with cough and gray-colored sputum for one week, and was initiated on azithromycin and prednisone. One week later she presented to the Emergency Department with progressive cough, shortness of breath, thirst, increased urinary frequency, and altered mental status. She was found to be in a hyperglycemic, hyperosmolar state. A chest radiograph showed left upper-lobe opacity and computed tomography of her chest revealed a large left upper-lobe cavitary lesion. Sputum cultures were positive for *Rhizopus* species. Treatment with AmBisome was initiated and the patient underwent left-sided pneumonectomy.

Pathological evaluation of the lobe revealed a 7.5 x 6.8 x 3.3 cm sharply demarcated necrotic cavity involving the majority of the left upper lobe with little surrounding uninvolved lung parenchyma (**Figure 1**). The cavity was surrounded by an erythematous rim, and within contained discohesive black-brown necrotic debris. Microscopic examination was significant for necrosis and acute inflammation, both surrounding and within the cavitation. Innumerable broad hyphae with rare septations were identified. The hyphae were irregularly branched at 90-degree angles, consistent with *Rhizopus* sp. (**Figure 2**). A Periodic acid-Schiff stain confirmed the presence of these organisms. The patient tolerated pneumonectomy well, and her clinical condition improved. Eventually she was discharged and scheduled for routine follow-up.

Rhizopus, Mucor and Rhizomucor

Fungi of the order *Mucorales* cause most human infection. They can be found on decaying vegetation and in the soil. Risk factors for infection include compromised immune status and include diabetes mellitus, malignancy and organ transplantation.[1] The genera most commonly found in human infections are Rhizopus, Mucor, and Rhizomucor.[2] The hyphae of *Mucor* are broad (5 to 15 micron diameter), with wide angle branching at approximately 90 degrees and rare septations.

Figure 1. Gross image of left upper lung lobe resection with cavitary lesion (center) and normal appearing surrounding lung parenchyma. Closer view of cavitary lesion shows surrounding uninvolved lung parenchyma. Black-brown necrotic debris is evident with the cavity (insert.)

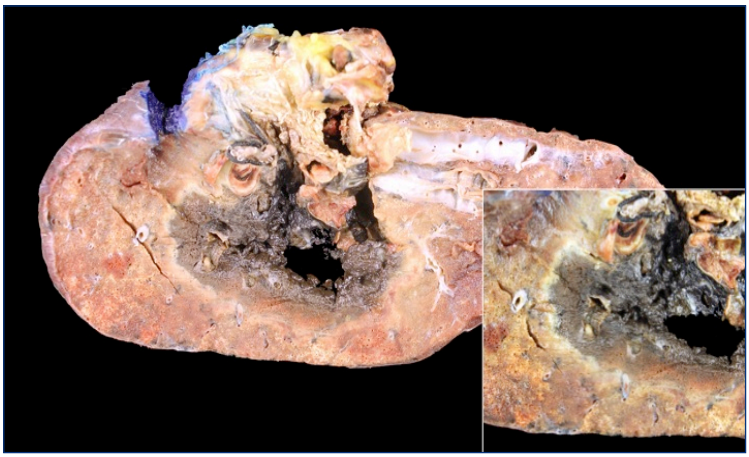

Figure 2. Microscopic image of the cavitary lesion with *Rhizopus* sp. (Hematoxalin and Eosin stain A, B, C).
A. Low magnification of the cavity with surrounding necrosis (40x).
B. Fungal organisms (center) with surrounding necrosis and inflammation (200x).
C Fungal organisms with broad hyphae and rare septations (400x).
D. Gamori Methenamine Silver stain of *Rhizopus* sp. with hyphae irregularly branched at 90 degree angles (400x).

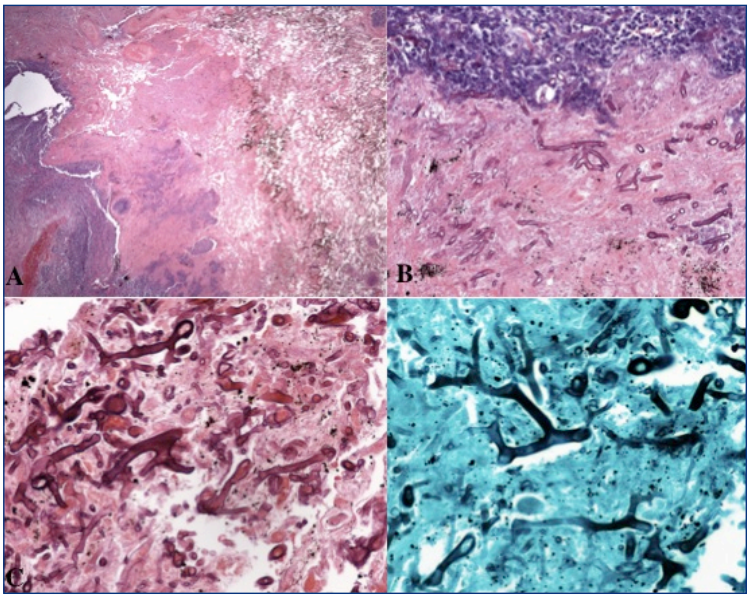

Rhizopus organisms have an enzyme, ketone reductase, which allows them to thrive in high glucose, acidic conditions. Serum from healthy individuals inhibits growth of Rhizopus, whereas serum from individuals in diabetic ketoacidosis stimulates growth.[3] Rhino-orbital-cerebral and pulmonary mucormycosis are acquired by the inhalation of spores.[4] The agents of mucormycosis are angioinvasive; thus, infarction of infected tissues is a hallmark of invasive disease.[5] Treatment of mucormycosis involves a combination of surgical debridement of involved tissues and antifungal therapy.[6] Elimination of predisposing factors for infection is also critical. Intravenous amphotericin B is the drug of choice. Therapy should continue until there is clinical resolution of the signs and symptoms of infection, as well as resolution of radiographic signs of active disease.[7] Despite early diagnosis and aggressive combined surgical and medical therapy, the prognosis for recovery from mucormycosis is poor. Independent risk factors for mortality include disseminated infection, renal failure, and infection with Cunninghamella species, while the use of surgery and administration of antifungal agent were associated with a better outcome.[2]

References

1. Lee FY, Mossad SB, Adal KA. Pulmonary mucormycosis: the last 30 years. *Arch Intern Med.* 1999 Jun 28;159(12):1301-9.
2. Roden MM, Buchanan WL, Knudsen TA, Sarkisova TA, Schaufele RL, Sein M, Sein T, Chiou CC, Chu JH, Kontoyiannis DP, Walsh TJ. Epidemiology and outcome of zygomycosis: a review of 929 reported cases. *Clin Infect Dis*. 2005;41(5):634.
3. Gale GR, Welch MA. Studies of opportunistic fungi. I. Inhibition of Rhizopus oryzae by human serum. *Am J Med Sci.* 1961;241:604.
4. Ferguson BJ. Mucormycosis of the nose and paranasal sinuses. *Otolaryngol Clin North Am*. 2000;33(2):349.
5. Greenberg RN, Scott LJ, Vaughn HH, Ribes JA. Zygomycosis (mucormycosis): emerging clinical importance and new treatments. *Curr Opin Infect Dis.* 2004;17(6):517.
6. Spellberg B, Walsh T, Kontoyiannis DP, Edwards J Jr, Ibrahim AS. Recent advances in the management of mucormycosis: from bench to bedside. *Clin Infect Dis*. 2009;48(12):1743.
7. Kontoyiannis DP, Lewis RE. (2011 Aug). How I treat mucormycosis. *Blood.* Aug 2011; 118(5):1216-24.

Authors

Ahmed Mahmood, MD, is a Resident, Department of Pathology, Rhode Island Hospital.

Michael Chaump, MD, is a Resident, Department of Pathology, Rhode Island Hospital.

Bettina Knoll, MD, is Assistant Professor of Infectious Diseases, Rhode Island Hospital.

Bassam Aswad, MD, is Assistant Professor of Pathology and Laboratory Medicine, Rhode Island Hospital.