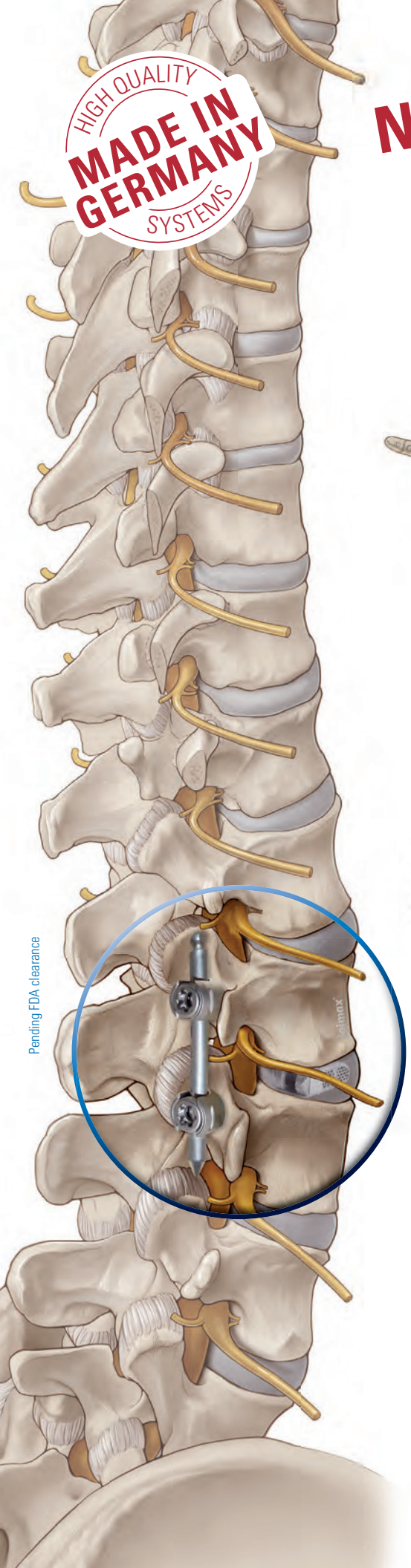

HIGH QUALITY MADE IN GERMANY SYSTEMS

Pending FDA clearance

joimax®

NEW

EndoLIF®

Endoscopic Lumbar Interbody Fusion

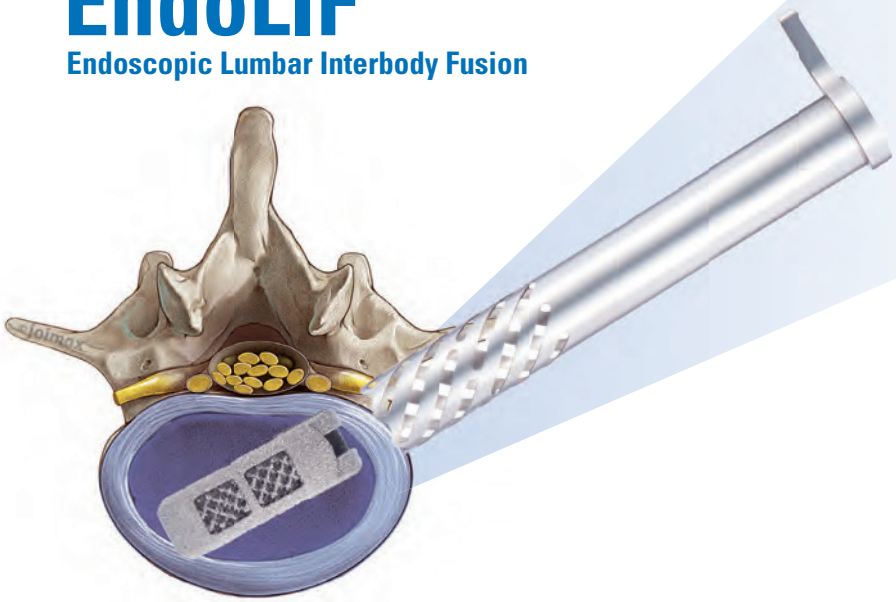

Access features

- Dura and nerve-gentle access by working tubes
- Preservation of the dorsal bony structures
- Tissue-sparing, atraumatic access through gradual tissue dilation
- Access through the spinal canal is avoided
- Procedure is possible without prior **TESSYS®** application

O(blique)-Cage features

- Ti6AL4V ELI material (titanium alloy)
- Osteoconductive surface structure
- Excellent visibility in X-ray and CT-images
- Cannulated for guided implantation
- Fillable with autologous bone or bone substitute
- Combined with Percusys® instrumentation

Percusys®

Percutaneous Screw-Rod-System

Advantages of Percusys®

- Ultra slim, extremely diverse, unique design
- Single sterile, pre-assembled pedicle screws, set screws and rods
- Polyaxial, monoaxial and quattroaxial, in all length and sizes (5, 6, 7, 8 mm)
- All screws are cannulated, fenestrated, self-drilling and self-tapping
- Unique design of multi-functional lengthening shaft for easiest use
- One instrument tray for all screws and a whole variety of surgical applications

joimax® Inc.
14 Goodyear, Suite 145
Irvine, CA 92618-3759, USA

Phone +1 949 859 3472
Fax +1 949 859 3473
Mail info@joimaxusa.com
Net www.joimaxusa.com

joimax® GmbH
Amalienbadstrasse 41
RaumFabrik 61
76227 Karlsruhe · Germany

Phone +49 (0) 721 255 14-0
Fax +49 (0) 721 255 14-920
Mail info@joimax.com
Net www.joimax.com

joined minimal access

Outpatient, Awake, Ultra-Minimally Invasive Endoscopic Treatment of Lumbar Disc Herniations

GABRIELE P. JASPER, MD; GINA M. FRANCISCO, BSC; ALBERT E. TELFEIAN, MD, PhD

ABSTRACT

BACKGROUND: Endoscopic discectomy is an ultra-minimally invasive outpatient surgical option for the treatment of lumbar herniated discs. The purpose of this study was to assess the benefit of tranforaminal versus interlaminar endoscopic discectomy in patients with single level Lumbar 5-Sacral 1(L5-S1) disc herniations and lumbar radiculopathy.

METHODS: After Institutional Review Board Approval, charts from 41 consecutive patients with complaints of lower back and radicular pain and an L5-S1 herniated disc who underwent an endoscopic procedure between 2007 and 2012 were reviewed. The transforaminal approach was used for patients with far lateral, foraminal, and paracentral disc herniations and the intralaminar approach was used for herniations that were more central.

RESULTS: The average pain relief 1-year postoperatively was 75.9% for the transforaminal group and 75.3% for the interlaminar group, both excellent results as defined by MacNab. The average preoperative visual analogue scale (VAS) scores were 8.2 and 8.4 for the transforaminal and interlaminar groups respectively, indicated in our questionnaire as severe and constant pain. The average 1-year postoperative VAS scores were 1.7 and 2.1, indicated in our questionnaire as mild and intermittent pain. There were no complications in the series of patients treated.

CONCLUSIONS: The 1-year follow-up data presented here for transforaminal and intralaminar approaches to L5-S1 disc herniations appears to indicate that either approach can be used as determined to best suit the pathology without sacrificing the probability of postoperative pain improvement.

KEYWORDS: Endoscopic discectomy, minimally-invasive, transforaminal, interlaminar

IRB approval: Meridian Health: IRB Study # 201206071J

BACKGROUND

Minimally invasive spine surgery is a broad term covering several different surgical approaches, but all are designed to access spine pathology while minimizing damage to the surrounding tissue. Transforaminal endoscopic lumbar discectomy represents the current pinnacle in minimally invasive spine surgery because the surgery is performed through a pea-sized incision (5-6 mm) in awake patients. This means faster recovery of the patient. Studies have shown shorter hospital stays and quicker return to work after endoscopic disc surgery.[1,2]

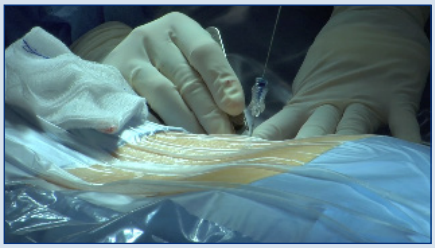

VIDEO: Endoscopic Lumbar Discectomy Surgical Procedure

Advances in endoscopic visualization and instrumentation, as well as increased patient demand for more minimally invasive procedures, have led to an increased popularity of the technique, particularly outside of the United States. Other studies have shown that endoscopic discectomy is a safe and effective alternative to conventional procedures, and has the advantages of being a truly minimally invasive procedure.[3-5] Rhode Island Hospital will be the first academic center in New England to offer this awake, ultra-minimally invasive endoscopic treatment for lumbar disc herniations this spring.

The authors describe here their experience with treating patients, who present with L5-S1 disc herniations and persistent lumbar radiculopathy despite conservative non-operative treatment, with endoscopic discectomy. Surgical approaches presented were chosen based on the location and morphology of the disc herniation, the height of the iliac crest and the need for foraminotomy. A retrospective study on average patient pain relief 1- year post-L5-S1 endoscopic discectomy is presented.

METHODS

Participants

After Institutional Review Board Approval, charts from 41 consecutive patients aged 25-87 (mean age of 46, 15 women (37%) and 26 men (63%)) with complaints of lower back and radicular pain who received endoscopic discectomy procedures for L5-S1 disc herniations between 2007 and 2012 were reviewed.

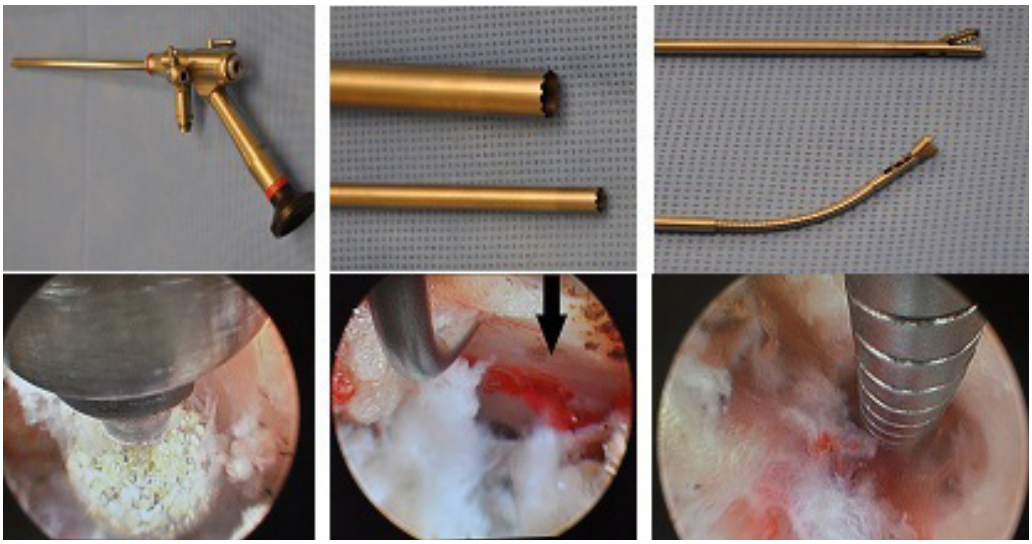

Figure 1. Instruments used in the TESSYS™ procedure are shown. Endoscope with working channel **(top left)**, large and small reamers for enlarging the neural foramen by removing the ventral portion of the superior articulating process **(top middle)**, straight and bendable graspers **(top right)**, diamond drill for enlarging the foramen **(bottom left)**, nerve hook for retracting the nerve root (*arrow*) **(bottom middle)**, and bendable grasping forceps reaching through the expanded foramen behind the pedicle for an extruded disc fragment **(bottom right)**.

Surgical Technique

Patients were selected for treatment based on the results of their MRI, physical exam, dermatomal pain pattern, and favorable response to transforaminal steroid injection. Patients were positioned on their sides (lateral decubitus) or lying face down (prone on a Wilson frame). Versed and fentanyl were given for conscious intravenous sedation and the rest of the procedure was performed with just local anesthetic. The surgeon began by inserting a set of guide rods and then a 6 mm working cannula under fluoroscopic guidance. Any bony removal necessary was performed with small bone reamers or an endoscopic drill (**Fig.1**). Rotating the cannula and endoscope allowed for 360-degree visualization of the annulus and exiting and traversing nerve roots (**Fig. 2**). The technical success of the foraminotomy procedure was determined by the visualization of the traversing nerve root (**Fig. 1**). Discectomy was performed with straight, upgoing, and bendable graspers (**Fig. 1**). At this point, whether using a transforaminal approach or interlaminar approach, the herniated disc and any bony overgrowth causing nerve root compression could be resected endsocopically under magnification.

The difference between the transforaminal approach and the interlaminar approach is the location of the operative "window." The entry point for the transforaminal approach is 8-18 cm off the midline with the target area being the neural foramen. This works well for lateral, foraminal and paracentral disc herniations. The interlaminar approach uses an entry point that is near midline and targets central disc herniations that are either above or below the exiting nerve root, which in the case of L5-S1 is the S1 nerve.

Measures

Follow-up questionnaires were filled out by the patient with each visit indicating the location, severity, and duration of pain. Patients were asked to rate their pain using a 0 – 10 scale, a modified form of the Visual Analog Scale (VAS). Each patient had MRI confirmation of disc herniation or protrusion prior to the procedure. Comparison was made between the two groups of patients: receiving endoscopic discectomies by transforaminal and interlaminar approaches. The overall pain relief in patients was calculated as a percentage of improvement between the preoperative and the 1-year postoperative VAS score. Overall success rate was then calculated on each patient. MacNab criteria

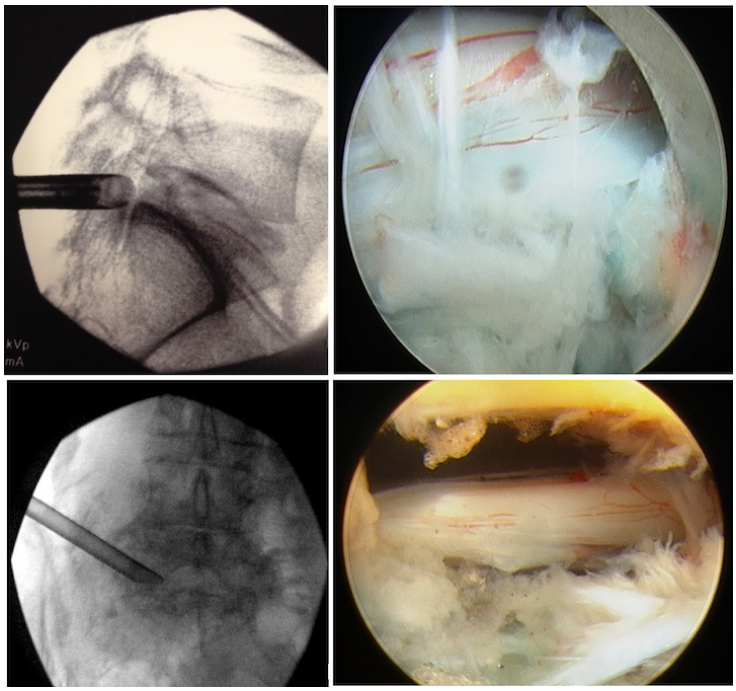

Figure 2. Fluoroscopic and endoscopic views from interlaminar and transforminal L5-S1 discectomies. Working channel seen in the L5-S1 interlaminar space **(top left)** and endoscopic view of the S1 nerve root (**above**) and herniated disc (below) **(top right).** Working channel seen in the L5-S1 transforaminal approach **(bottom left)** and endoscopic view of the ligamentum flavum (top and yellow) S1 nerve root (middle) and herniated disc (below) **(bottom right).**

was applied to each patient by characterizing pain relief of 75%-100% as excellent, 50%-74% as good, 25%-49% as fair, and 0%-24% as poor.[6] Success is based on an excellent, good, or fair outcome.

RESULTS

Of the 41 patients undergoing awake endoscopic surgical treatment for an L5-S1 disc herniation, 24 underwent a transforaminal approach and 17 an interlaminar approach. The average pain relief 1-year postoperatively was 75.9% for the transforaminal group and 75.3% for the interlaminar group, both excellent results as defined by MacNab.[6] The average preoperative VAS scores were 8.2 and 8.4 for the transforaminal and interlaminar groups respectively, indicated in our questionnaire as severe and constant pain. The average 1-year postoperative VAS scores were 1.7 and 2.1, indicated in our questionnaire as mild and intermittent pain. Only 1 patient in the transforaminal surgery group and 2 patients in the interlaminar group had results that were not at least excellent, good, or fair.

During the 1-year follow-up there were no cases of disc reherniations in either group. There were no complications of cerebrospinal fluid leak, nerve injury, or hemorrhage requiring return to the operating room. Previously reported complications can include infection, dysesthesia, thrombophlebitis, dural tear, vascular injury, and death.[4]

DISCUSSION

Other studies have shown that endoscopic spine surgery is an effective procedure for treating multiple pathologies in the lumbar spine including lateral, paracentral, central, extruded and even contralateral herniated discs as well as lateral recess stenosis.[2,7-10] The 41 patients treated here included cases in which sequestered herniated discs seen cephalad or caudal to the disc space were removed using specialized flexible instruments. The instruments enabled the surgeon to circumnavigate and reach into the epidural space and as far as the mid-vertebral body (**Fig. 1**). The unique surgical method and instrument design allowed for high success even in the more challenging area of L5-S1 presented here. The patients were sedated intraoperatively but conscious so nerve damage could be avoided. Each patient was asked throughout the procedure if he or she was experiencing leg pain, characteristic of manipulation of the nerve root. This nerve could be viewed and identified endoscopically allowing for further caution when working in the epidural space, adding to the safety of the procedure.

Changes in health care in the United States present challenges, among them how to deliver the highest-quality, most-effective care in the most cost-efficient way. In the United States, from 2002-2007, a study of Medicare patients showed a 15-fold increase in the frequency of complex spinal fusions performed in this older population – these included 360-degree and multilevel lumbar spinal fusions.[11] Multilevel complex spinal fusions represent a complex solution to the problem of degenerative spine disease. Most practitioners and patients in Rhode Island would likely agree that the availability of more "non-instrumented" minimally-invasive surgical options to spine care would be a welcome addition to our treatment armamentarium.

References

1. Molyneux S, Spens HJ, Gibson A. Transforaminal Endoscopic or Micro-Discectomy – Early Results of a Randomized Controlled Trial. Proceedings of Britspine. 2010.
2. Ruetten S, Komp M, Merk H, Godolias G. Full-endoscopic interlaminar and transforaminal lumbar discectomy versus conventional microsurgical technique: a prospective, randomized, controlled study. *Spine*. 2008;33(9):931.
3. Ruetten S, Komp M, Merk H, Godolias G. Full-endoscopic interlaminar and transforaminal lumbar discectomy versus conventional microsurgical technique: a prospective, randomized, controlled study. *Spine.* 2008;33(9):931-9.
4. Tenenbaum S, Arzi H, Herman A, Friedlander A, Levinkopf M, Arnold PM, Caspi I. Percutaneous posterolateral transforaminal endoscopic discectomy: clinical outcome, complications, and learning curve evaluation. *Surg Technol Int.* 2012; XXI:278-283.
5. Yeung AT, Tsou PM. Posterolateral Endoscopic Excision for Lumbar Disc Herniation. *Spine.* 2002;22(7):722-31.
6. MacNab I. Negative disc exploration. *JBJS (Am).* 1971;53A:891-903.
7. Thomé C, Barth M, Scharf J, Schmiedek P. Outcome after lumbar sequestrectomy compared with microdiscectomy: a prospective randomized study. *J Neurosurg Spine.* 2005;2(3):271-8.
8. Choi G, Lee SH, Lokhande P, Kong BJ, Shim CS, Jung B, Kim JS. Percutaneous endoscopic approach for highly migrated intracanal disc herniations by foraminoplastic technique using rigid working channel endoscope. *Spine.* 2008; 1:33:E508-15.
9. Ruetten S, Komp M, Merk H, Godolias G. Surgical treatment for lumbar lateral recess stenosis with the full-endoscopic interlaminar approach versus conventional microsurgical technique: a prospective, randomized, controlled study. *J Neurosurg Spine.* 2009;10(5):476-85.
10. Yeom KS, Choi YS. Full endoscopic contralateral transforaminal discectomy for distally migrated lumbar disc herniation. *J Orthop Sci.* 2011;16:263-9.
11. Deyo RA, Mirza SK, Martin BI, Kreuter W, Goodman DC, Jarvik JG. Trends, major medical complications, and charges associated with surgery for lumbar spinal stenosis in older adults. *JAMA.* 2010;303:1269-65.

Authors

Gabriele P. Jasper, MD, founded the Center for Pain Control in Brick and Milltown, NJ, and the Jasper Ambulatory Surgical Center.

Gina M. Francisco, BSc, is affiliated with the Center for Pain Control in New Jersey.

Albert Telfeian, MD, PhD, is Director of Pediatric Neurosurgery at Hasbro Children's Hospital and Associate Professor of Neurosurgery at the Alpert Medical School of Brown University, and Rhode Island Hospital, Providence RI.

Correspondence

Albert Telfeian, MD, PhD
Department of Neurosurgery
Rhode Island Hospital
593 Eddy Street
Providence, RI 02903
401-793-9132
Fax 401-444-2788
ATelfeian@Lifespan.org