Management of the 'Young' Patient with Hip Disease

SCOTT A. RITTERMAN, MD; LEE E. RUBIN, MD

ABSTRACT

Although hip arthritis typically affects older patients, there is a rapidly growing population of "young" patients experiencing debilitating symptoms from hip disease. Most commonly, osteoarthritis and avascular necrosis affect this population, but a variety of other primary structural and metabolic causes can also occur. The expectations of these younger patients are often distinct from geriatric patients, and the challenges in optimizing their care are unique in this demanding population. Selection of the implant, bearing surface, and surgical technique can all impact the success and longevity of total hip replacement. A consideration for respecting the native bone stock is an important consideration that can potentially reduce some of the future challenges of revision arthroplasty in this young population.

KEYWORDS: total hip replacement (THA), neck sparing arthroplasty (NSA)

Diagnosis and Management of Hip Disease in the Young Patient

Advanced arthritis of the hip joint can lead to profound changes in quality of life. Debilitating pain, stiffness, and altered gait biomechanics all affect the ability to stay mobile and maintain gainful employment; these concerns are magnified in the younger patient with hip disease. While hip arthritis typically affects older patients, there is a significant subset of active patients in their 30s, 40s, and 50s who are affected and were previously thought of as, "too young for a hip replacement." Over the last several decades, advances in hip replacement surgery are allowing us to rethink that position. Two major causes of advanced arthritis in young patients are primary (idiopathic) osteoarthritis and avascular necrosis. Most of the remaining cases are caused by inflammatory arthropathies, infections, trauma and congenital or developmental anatomical abnormalities.[1]

Osteoarthritis

Osteoarthritis is a chronic degenerative condition that is associated with, but not caused by, aging. It can be categorized into primary or secondary causes. Primary osteoarthritis remains idiopathic in nature. While its exact pathophysiology is unknown, some believe that minor developmental abnormalities lead to impingement within the joint, altered biomechanics and ultimately cartilage loss.[2] Secondary osteoarthritis can be due to an identifiable cause such as trauma to the femoral head, post-infection arthritis, slipped capital femoral epiphysis, or hip dysplasia.

As we age, the water content of cartilage increases with a concomitant decrease in protein content, both leading to degeneration. The progressive loss of the cartilage matrix leads to recurrent bouts of inflammation as bone contacts bone, and reactive bone called osteophyte forms around the joint. In the subchondral bone, hardening and cyst formation occurs. Repeated bouts of inflammation also extend into the peri-articular soft tissues leading to deformity and contractures of the capsule, supporting ligaments, and tendons. Put together, these changes lead to pain, stiffness, and gait disturbances. Its commonality among close relatives hints at a genetic predisposition, which is not currently understood.[1]

Avascular Necrosis

Avascular necrosis, also known as osteonecrosis, is the most common reason for advanced hip arthritis in the young patient.[3,4] Avascular necrosis occurs when the bone in the femoral head loses its blood supply. The weakened bone leads to cyst formation and collapse of the bony architecture with a resulting deformation in the shape of the femoral head. This painful process results in a rapidly progressing arthritis. Common causes are alcohol abuse, prolonged use of corticosteroids, hypercoagulable states (ie. Sickle cell disease[5] or lupus) and trauma to the hip resulting in altered blood flow to the femoral head. Smoking is also postulated to have a role in the microvascular manifesations of the disease.

Many other cases are idiopathic in nature. Initial treatment begins with medical management and may include anti-inflammatory medication. Some studies have demonstrated bisphosphonate use may delay or prevent femoral head collapse; further studies have not supported it. Though many have been investigated, there is no single pharmacological agent that can prevent the naturally advancing course of osteonecrosis.[4]

If significant pain relief is not achieved with conservative care, most patients turn to surgical management. When diagnosed early before collapse of the femoral head, a core decompression can be performed to preserve the joint. In this procedure, a canal is drilled into the femoral head with the hope of reducing the intraosseous pressure to relieve

pain, and stimulate a healing response in the femoral head by increasing blood flow. Typically these techniques relieve pain, but often only delay eventual femoral head collapse. Unfortunately, many of these patients will still develop femoral head collapse and the associated findings of acute-onset severe arthrosis associated with debilitating pain, and will then need a hip replacement.

Presentation and Management

Common symptoms of hip arthritis include pain in the groin, especially while weight bearing and increasing with use. The arthritic hip is typically stiff in the morning and the patient may note difficulty getting up from a chair after a prolonged time seated. There is a noted decreased range of motion and activity tolerance, with particular difficulty in donning socks and tying shoelaces. The resulting disuse of the hip second to pain leads to atrophy of the musculature. Muscle weakness, in addition to avoiding weight bearing on the affected extremity, can lead to the development of an antalgic limp. A cane or crutch may be used to offload body weight, and pain may also be referred to the lower back or ipsilateral knee.

Nonsurgical management of arthritis is typically geared toward the inciting factor whether that is stopping an offending agent (steroids, alcohol), or the use of disease modifying anti-rheumatic drugs (DMARDs) in inflammatory arthropathies. Virtually all patients with arthritis can benefit from other nonsurgical interventions such as weight loss, activity modification and anti-inflammatory medications. Each patient is affected differently and it is difficult to know the expected rate of progression in each.

Patients in significant pain and discomfort will typically seek the help of a hip specialist. For those who quickly progress to debilitating arthritis, a replacement may be the only option regardless of age. In the past, younger patients had limited surgical options. Hip arthrodesis, or fusion, had poor results with limited functionality and frequently lead to atrophy of hip musculature and pericapsular contractures making reversal difficult. Deficient hip abductors predispose to dislocation as well. [3] Healthy, young, active patients with advanced arthritis are ideal candidates for a replacement due to their good muscle tone and ability to remodel bone and enjoy predictable increases in quality of life. Other surgical options not discussed further can include femoral or acetabular osteotomies for deficiencies in the proximal femur or acetabulum respectively. These are reserved for anatomic or congenital abnormalities that lead to altered hip biomechanics and also significant pain.

Surgical Options for Hip Replacement in the Young Patient

A total hip replacement is one of the most reliably successful procedures in orthopaedics. Long-term data has shown that with a well positioned modern prosthesis we can give our patient reliable pain relief that has a very high chance (>80% in most cases) of lasting over twenty years.[6,7] While this may be very comforting to a 75-year-old retired patient with relatively low functional demands, it will not suffice for patient with advanced arthritis in their 30s. For this reason, in the past many surgeons were reluctant to perform joint replacement surgeries in young patients for fear of condemning them to multiple revisions over a lifetime of use. With current technology, we can now provide young and active patients with long lasting pain relief with the confidence that we will be able to revise these prostheses in the future if needed.

The ideal hip replacement prosthesis for a young patient would be easily integrated, forming a long lasting bond with the host bone, yet be easily removed if needed. Most modern hip prostheses are made of titanium and are cementless. They use biological ingrowth for osseous integration of both the femoral and acetabular components. The prosthesis is typically coated with thousands of tiny particles that give the surface a roughened appearance. Between these tiny metallic pores are spaces where the host bone actually grows onto the prosthesis.

Bearing surfaces are the parts of the prostheses that glide across one another to allow motion at the joint. In the past, many different products were used including ivory, glass, plastic and metal. Today popular choices include either a metal (cobalt-chrome) on plastic (called polyethylene), ceramic on plastic, ceramic on ceramic. Metal on metal remains an option, but has fallen out of favor due to poor clinical performance and implant recalls.

As the bearing surfaces rub against each other, the materials begin to wear, shedding tiny micron-sized particles, each at a different rate. Previously, plastic wear particles generated when the head of the prosthesis rubbed on the plastic liner were responsible for a phenomenon termed 'osteolysis.' Osteolysis is an inflammatory condition led by an activated macrophage response to ingested plastic particles which leads to periprosthetic bone loss resulting in implant loosening or fracture.[8] This has largely (but not completely) been solved with the highly engineered "cross-linking" of the polyethylene molecules that makes it almost a thousand times more resistant to wear.

Ceramic bearings are quickly becoming the preferred bearing surface in the young and active patient.[6,9,10] These bearings have lower wear rates than metal on plastic components and have less friction between surfaces leading to smoother motion.[3] Additionally, by eliminating a polyethyelene component, osteolysis is much less a concern.[8-10]

Another aspect of the modern hip prosthesis that has evolved is the actual design of the femoral implant itself. Several implant designs on the market are 'bone sparing,' meaning that less native bone is resected from the femur. Over the past decade, "hip resurfacing" was a popular procedure in this regard. Resurfacing procedures have fallen out of favor recently for several reasons, including the difficulty of placing the prosthesis as well as concerns for metal-on-metal bearing wear and failures.

A "bone-sparing prosthesis" is not a new concept but has been gaining in popularity. This prosthesis is similar in

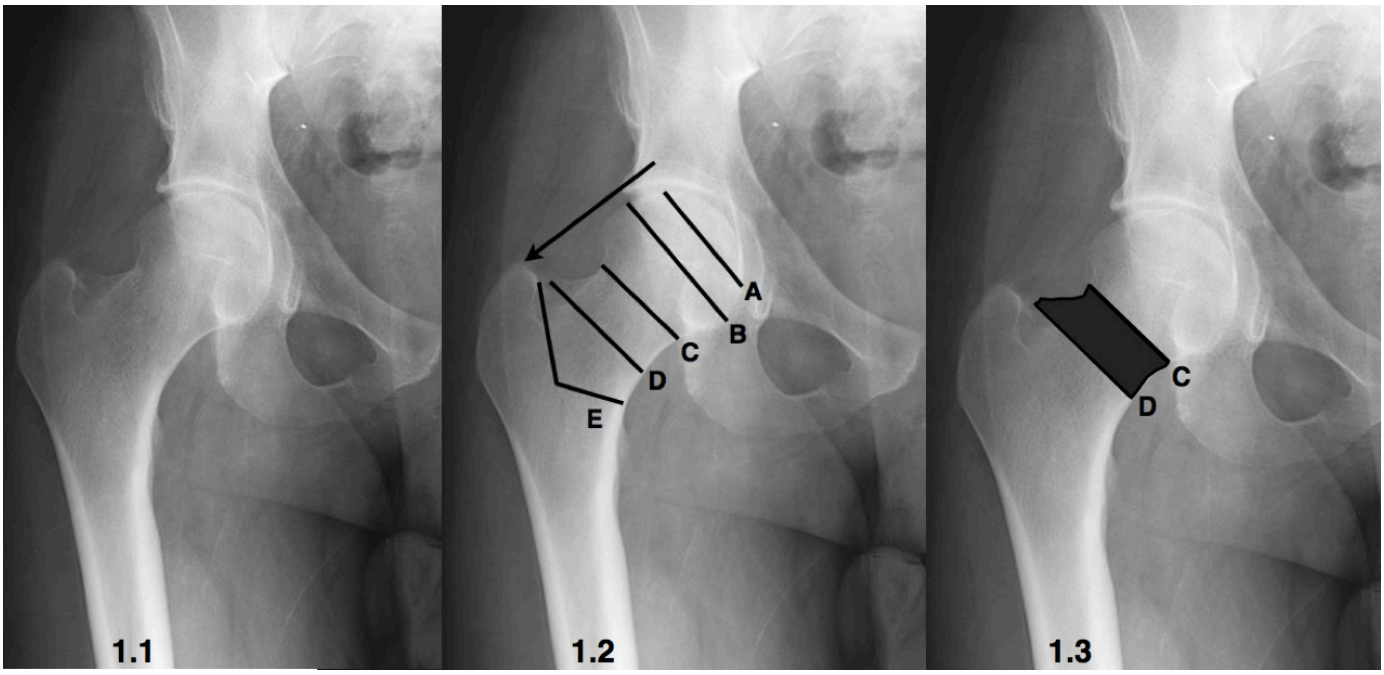

Figure 1.1. AP Radiograph demonstrating a healthy native right hip joint.

Figure 1.2. Various bone resection levels, each taking away more proximal femoral bone from level A (Proximal) through E (Distal). (A: Hip Resurfacing, B: "Mid-Head" Resurfacing, C: "Neck-Sparing Arthroplasty," D: Standard Total Hip Arthroplasty, E: Revision Total Hip Arthroplasty.)

Figure 1.3. Shaded area demonstrates the retained area of proximal femur preserved with a "Neck-sparing arthroplasty."

design to other modern prosthesis but preserves more bone in the femoral neck of the patient. The hope is to allow implant placement while leaving a viable option for revision at a later date. When the femoral bone cut is made, more femoral neck bone is retained, and the proximally coated implant engages and helps preserve this "extra" bone over time. Plastic, metal or ceramic bearing options can still be used.

The level of the femoral bone resection varies based on the arthroplasty technique. (Figure 1) In hip resurfacing (1.2 A) and "mid-head" resurfacing (1.2 B) (available only in Europe), most of the femoral bone is retained. With neck sparing arthroplasty (1.2 C) and conventional total hip arthroplasty (1.2 D), progressively more bone is resected during the operation. With hip revision surgery, native bone is often eroded, leading to and even lower bony resection level (1.2 E). "Neck-sparing" implants allow the surgeon to retain the native bone between cut levels C and D (Figure 1.3), with the concept of native neck bone stock preservation for future revision surgery in the young patient.

SUMMARY

Over the next several decades we will continue to see improvements in implant fixation, bioengineering of bearing surfaces, and prosthesis design that will allow us to reliably replace hip joints in younger and more active adult patients. In addition to continued improvements, careful outcomes monitoring with joint replacement registries will be needed over the next few decades. Ideally, surgeons would like to provide durable, long lasting pain relief to patients, regardless of their age at presentation, and have the ability to safely revise a prosthesis in the future if needed. The ability to perform hip replacement surgery with a forward thought toward future revision will give hip specialists the confidence to treat patients previously though too young to undergo joint replacement surgery.

Brief Case Example

A 29-year-old man presented with the acute-onset of debilitating pain in his left hip from AVN with collapse secondary to chronic steroid use for immunosuppression of severe lupus. (Figure 2). His symptoms developed over 4 weeks and were incapacitating, requiring the use of two crutches and high doses of long-acting narcotic for comfort. He was treated with total hip arthroplasty using a neck sparing implant and a ceramic on cross-linked polyethylene bearing surface couple. The implants were inserted via the direct anterior approach with a "bone-sparing technique" allowing retention of 1.5 cm of his proximal femoral bone, with anatomic restoration of his hip center of rotation (Figures 3 and 4). His postoperative course showed complete resolution of his pain, dramatic improvement in his hip function, and he was able to begin returning to work as a professional chef after less than 8 weeks of recovery.

Figure 2. Left Hip Joint with AVN and acute collapse of the dome of the femoral head, indicated by arrows.

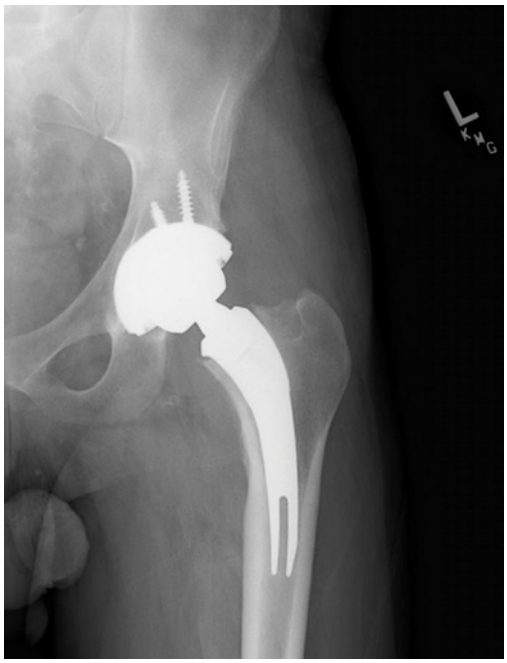

Figure 3. Postoperative AP Left Hip, showing "neck-sparing arthroplasty" in an anatomic position with restoration of hip alignment, offset, and position.

Figure 4. Postoperative Lateral Left Hip demonstrating anatomic prosthesis positioning.

References

1. Hoaglund FT, Steinbach LS. Primary Osteoarthritis of the Hip: Etiology and Epidemiology. *Journal of the American Academy of Orthopaedic Surgeons*. 2001; 9:320-27.
2. Ganz R, et al. The Etiology of Osteoarthritis of the Hip. *Clinical Orthopaedics and Related Research;* 2008;466(2):264-272.
3. Polkowski G, et al. Total Hip Arthroplasty in the very Young Patient. *Journal of the American Academy of Orthopaedic Surgeons.* 2012;20:487-497.
4. Chen CH, Chang JK, Lai KA, Hou SM, Chang CH, Wang GJ. Alendronate in the prevention of Collapse of the Femoral Head in non-traumatic Osteonecrosis. *Arthritis and Rheumatism*. 2012;64(5)1572-78.
5. Hernigou P, Bachir D, Galacteros F. The Natural Hisotry of Symptomatic Osteonecrosis in Adults with Sickle-Cell Disease. *Journal of Bone and Joint Surgery.* 2003;85-A(3):500-4.
6. Moussa H, Pierre B, Jacques D, et al. Alumina-on-Alumina Total Hip Arthroplasty A Minimum 18.5-Year Follow-up Study. *The Journal of Bone & Joint Surgery*. 2002;84(1):69-77.
7. Neumann L, Freund KG, Sorenson KH. Long-Term Results of Charnley Total Hip Replacement. *J Bone Joint Surg Br*. March 1994;76-B(2):245-251.
8. Beck RT, Illingwort KD, Saleh KJ. Review of Periprosthetic osteolysis in total joint arthroplasty: an emphasis on host factors and future directions. *Journal of Orthopedic Research*. 2012 Apr;30(4):541-6.
9. Byun JK, et al. Third-Generation Ceramic-on-Ceramic Total Hip Arthroplasty in Patients younger than 30 years with Osteonecorsis of the Femoral Head. *Journal of Arthroplasty.* 2012;27(7):1337-1343.
10. Restrepo C, Parvizi J, Kurtz SM, et al. The noisy ceramic hip: is component malpositioning the cause? *J Arthroplasty*. 2008;23:643.
11. Walter WL, Yeung E, Esposito C. A Review of Squeaking Hips. *Journal of the American Academy of Orthopaedic Surgeons*. 2010;18:319-326.
12. Daniel J, et al. Pseudotumor Associated with Total Hip Arthroplasty. JBJS. 2012; 94:86-93.

Authors

Scott A. Ritterman, MD, is a resident in orthopaedic surgery, affiliated with Brown University and Rhode Island Hospital.

Lee E. Rubin, MD, is Assistant Professor of Orthopaedic Surgery, Division of Adult Reconstruction, Warren Alpert Medical School of Brown University.

Disclosures

Neither author has any financial conflicts of interest to disclose related to the content of this article.

Correspondence

Lee E. Rubin, MD
University Orthopedics Inc.
1405 South County Trail
East Greenwich RI 02818
401-402-1060
Fax: 401-402-1061
lrubin@universityorthopedics.com