Cubital Tunnel Syndrome: Diagnosis and Management

Samir K. Trehan, MD, John R. Parziale, MD, and Edward Akelman, MD

Cubital tunnel syndrome is, after carpal tunnel syndrome, the second most common compression neuropathy of the upper extremity. Patients often present with pain, paresthesias and/or weakness that if left untreated may lead to significant disability. This article reviews the etiology, diagnosis and management of cubital tunnel syndrome.

Anatomy and Etiology

The ulnar nerve originates from branches of the C8 and T1 spinal nerve roots and is the terminal branch of the medial cord of the brachial plexus. In the arm, the ulnar nerve courses between the medial head of the triceps and the brachialis muscles. It then travels posterior to the medial epicondyle of the humerus and enters the cubital tunnel. The roof of the cubital tunnel consists of Osborne's ligament, which spans from the medial epicondyle of the humerus to the olecranon of the ulna, and the floor consists of the medial collateral ligament and joint capsule of the elbow. After exiting the cubital tunnel, the ulnar nerve passes between the humeral and ulnar heads of the flexor carpi ulnaris muscle and enters the anterior compartment of the forearm. In the forearm, it courses between, and innervates, the flexor carpi ulnaris and ulnar half (i.e., fourth and fifth fingers) of the flexor digitorum profundus muscles. The ulnar nerve then divides into superficial and deep branches. The deep branch innervates the hypothenar, third and fourth lumbrical, interosseous, adductor pollicis and deep head of the flexor pollicis brevis muscle, and the superficial branch provides sensory function for the medial hand.

Ulnar nerve compression most commonly occurs at the elbow. At the elbow, the ulnar nerve can be compressed at five sites: the arcade of Struthers, medial intermuscular septum, medial epicondyle, cubital tunnel and deep flexor pronator aponeurosis.[1] (Figure 1) Ulnar nerve compression within the cubital tunnel, known as cubital tunnel syndrome, is the most common site of compression.

During elbow flexion, the ulnar nerve is stretched 4.5 to 8 mm (since it lies posterior to the axis of motion of the elbow) and the cubital tunnel cross-sectional area narrows by up to 55% as intraneural pressures increase up to 20-fold.[2,3] As a result, repeated and sustained elbow flexion can irritate the ulnar nerve and eventually lead to cubital tunnel syndrome. This relationship between prolonged elbow flexion and cubital tunnel syndrome has been reported in patients who habitually sleep in the fetal position or sleep in the prone position with their hands tucked under the pillow. More recently, this relationship has been reported in patients with frequent prolonged cell phone use (i.e. "cell phone elbow"). Cubital tunnel syndrome can also develop in patients years after elbow trauma leading to cubitus varus deformity, such as supracondylar humerus fractures (i.e., "tardy ulnar nerve palsy"). Other causes of cubital tunnel syndrome include chronic external compression (e.g., wheelchair-bound patients and truck drivers), ulnar collateral ligament laxity (e.g., baseball pitchers), local edema or inflammation, space-occupying lesions (e.g., tumor) and repeated subluxation or dislocation of the ulnar nerve.

The incidence of cubital tunnel syndrome in the general population has been reported at 24.7 per 100,000.[4] Populations at risk for cubital tunnel syndrome include patients with diabetes, obesity, as well as occupations involving repetitive elbow flexion and extension, holding tools in constant positions and using vibrating tools. The prevalence within these populations ranges from 2.8% among workers whose occupations require repetitive work (e.g., assembly line workers, packagers and cashiers) to 6.8% in floor cleaners to 42.5% among vibrating tool operators.[4]

Clinical Evaluation and Diagnosis

Diagnosis of cubital tunnel syndrome requires a thorough history and physical examination. Patients frequently initially present with intermittent paresthesias, numbness and tingling in the small finger and ulnar half of the ring finger (i.e., ulnar nerve distribution). As the disease progresses, these symptoms may become more constant and patients may complain of elbow pain in the region of the cubital tunnel (i.e., the "funny bone" area). Patients may also initially present with non-specific complaints of hand clumsiness or weakness, however atrophy of the intrinsic hand muscles innervated by the ulnar nerve is a sign of advanced disease. Motor impairment may manifest as grip weakness (e.g., difficulty opening bottles

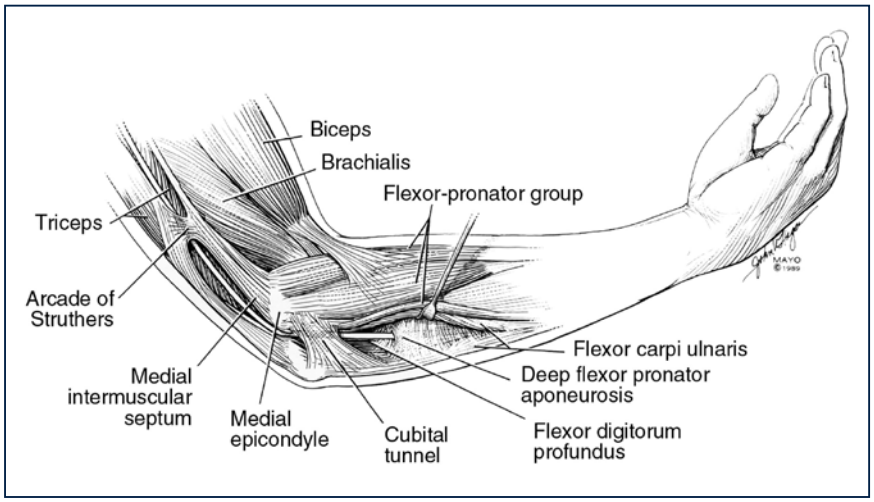

Figure 1. Ulnar nerve anatomy and sites of compression around the elbow. By permission of Mayo Foundation for Medical Education and Research. All rights reserved.

or jars), hand clumsiness (e.g., difficulty typing) or difficulty with precision pinch activities (e.g., buttoning buttons).[1]

Since patients with mild disease may have no symptoms at the time of examination, various provocative exam techniques may aid in diagnosis of these patients. The elbow flexion test is performed by placing the elbow in maximal flexion and full supination. The test is positive if paresthesias, numbness or tingling are reproduced in the ulnar nerve distribution. This test has been reported to be 75% sensitive after one minute. Tinel's test, in which the cubital tunnel is tapped by the examiner's finger, may also reproduce symptoms and has been reported to be 70% sensitive. Finally, compression of the nerve for one minute just proximal to the cubital tunnel with the elbow in 20° flexion and full supination is 89% sensitive when performed alone and 98% sensitive when performed in combination with the elbow flexion test.[1, 5]

With advanced disease, objective findings of weakness in the muscles innervated by the ulnar nerve may be noted on examination. Patients may have weak finger abduction secondary to interosseus muscle atrophy. In particular, the first dorsal interosseous muscle can be examined by asking the patient to abduct the index finger against resistance. Small finger abduction following extension of the digits may also be noted (Wartenberg sign), which patients may notice by the small finger being caught when trying to place the hand inside of a pant pocket. Patients may also be unable to grasp with a key-pinch grip and instead compensate with a fingertip grip (Froment sign) secondary to adductor pollicis, first dorsal interosseous and flexor pollicis brevis atrophy. (Figure 2) Finally, severe clawing of the ring and small fingers (i.e. flexion of the interphalyngeal joints with extension of the metacarpophalyngeal joints) may be noted secondary to lumbrical and interosseous muscle atrophy.[6]

Physical examination must also include investigation of potential underlying causes for cubital tunnel syndrome. Thus, the elbow should be examined for range of motion, crepitus, ligament stability and deformity. In particular, patients whose chief complaint is medial elbow pain (as opposed to paresthesias, numbness, tingling or hand clumsiness) should be evaluated for medial epicondylitis and elbow instability.

During the work-up of patients with suspected cubital tunnel syndrome, it is important to consider other potential sites of ulnar nerve compression, C8 radiculopathy, thoracic outlet syndrome, vascular disease, amyotrophic lateral sclerosis and peripheral neuropathy (which can be secondary to chronic alcoholism, diabetes, vitamin B_{12} deficiency and hypothyroidism among other causes). Patients with C8 radiculopathy can have co-existent cubital tunnel syndrome—a phenomenon referred to as "double crush"—and therefore one diagnosis does not preclude the other.

Although no disease-specific outcome measures have been validated for cubital tunnel syndrome, numerous severity scales have been reported based on findings from history and physical examination.[7] McGowan first classified cubital tunnel syndrome severity into three categories: mild, moderate and severe. Mild disease is defined as occasional paresthesias, positive Tinel's sign and subjective weakness. Moderate disease is defined as occasional paresthesias, positive Tinel's sign and objective weakness. Severe disease is defined as constant paresthesias and muscle wasting.[8]

Laboratory, Radiographic and Electrodiagnostic Assessment

Diagnostic testing may be helpful in patients with suspected cubital tunnel syndrome. Radiographs of the elbow may identify osteophytes, bone fragments or malalignment in patients with arthritis or a history of trauma. **Electromyographic (EMG)** and nerve conduction studies may be helpful in confirming the diagnosis of ulnar neuropathy at the elbow, assisting in precise localization of the compressive lesion (e.g., proximal versus distal to the innervation of the flexor carpi ulnaris), quantifying the degree of the neurologic deficit and/or identifying alternate sites of nerve dysfunction simulating cubital tunnel syndrome such as cervical radiculopathy, brachial plexopathy and/or ulnar nerve compression at the wrist at Guyon's canal. Ulnar nerve compression can be diagnosed if **motor nerve conduction velocity (NCV)** across the elbow is less than 50 m/s. Performing NCV studies with the elbow in moderate flexion (i.e., 70 to 90 degrees from the horizontal) maximizes test sensitivity by providing the greatest correlation between the skin surface measurement and true nerve length.[1, 9] Needle EMG examination should always include the first dorsal interosseous muscle, which is the most frequent muscle to first demonstrate abnormalities following ulnar nerve compression.[9] In addition, electrodiagnostic testing has been shown to have prognostic value in predicting subjective recovery.[10]

Figure 2. First dorsal interosseous muscle atrophy secondary to ulnar nerve neuropathy.

MRI may be helpful if a space-occupying lesion is suspected, but otherwise is not routinely used. In addition to also being useful for visualizing space-occupying lesions, ultrasound has recently been proposed as a diagnostic tool for cubital tunnel syndrome via measurement of nerve diameter. A literature review of clinical trials of ultrasonagraphy used to test ulnar neuropathy at the elbow noted that numerous studies had significant methodological flaws, some studies were uncontrolled, and that the study designs differed significantly. The authors concluded that the role of ultrasound in ulnar neuropathy at the elbow could not be firmly established.

Management

Conservative Management

In the absence of intrinsic muscle atrophy, conservative treatment should be attempted. Non-operative treatment includes patient education and activity modification to avoid elbow flexion and/

or cubital tunnel compression. Depending on the provocative activity, this can be accomplished by wearing an elbow extension splint at night (or, more simply, limiting elbow flexion by wrapping a pillow around the anterior elbow), adjusting posture at work to reduce elbow flexion, using a hands-free headset with cell phone use, or padding the posterior surface of the elbow. In addition, non-steroidal anti-inflammatory drugs or ice can be used to reduce acute pain and inflammation. Following resolution of acute symptoms, physical therapy is initiated to first establish pain-free range of motion of the affected extremity and then increase strength. Dellon, et al. reported symptom improvement in 90% of patients with mild disease and 38% of patients with moderate disease. A history of elbow trauma is a poor prognosticator and risk factor for eventual surgery.[11]

Operative Management

When patients fail to respond to conservative measures, have persistent severe symptoms or present with intrinsic muscle atrophy, operative management should be considered. Surgical options include ulnar nerve in situ decompression, anterior transposition of the ulnar nerve (subcutaneous, intramuscular or submuscular), partial medial epicondylectomy and endoscopic ulnar nerve decompression. Studies of in situ decompression report 75% to 90% of patients achieve good or excellent pain relief, while 7% to 15% do not benefit.[12] Despite discussion in the literature regarding in situ decompression's potential advantages (e.g., minimal disruption of the ulnar nerve's vascular supply) and disadvantages (e.g., limited exposure to explore other potential sites of ulnar nerve compression and risk of post-operative ulnar nerve subluxation) versus anterior transposition, two meta-analyses have demonstrated similar outcomes between these techniques.[13, 14] In the 7% to 15% of patients who have recurrent disease following in situ decompression, many can be successfully treated with anterior transposition of the ulnar nerve.[14]

Patients with post-traumatic elbow stiffness or deformity, ulnar nerve subluxation, ulnar collateral ligament laxity and "tardy ulnar nerve palsy" may benefit from initial anterior transposition of the ulnar nerve. Patients with medial epicondylitis may benefit from partial medial epicondylectomy, although this procedure has been associated with increased medial elbow pain post-operatively. Finally, endoscopic ulnar nerve release has been reported to have a similar success rate to open procedures with potentially less post-operative pain. A common surgical complication of all of these techniques is potential injury to the posterior branch of the medial antebrachial cutaneous nerve. Taken together, given the similarity in outcomes reported between the surgical treatments for cubital tunnel syndrome, the choice of procedure is based largely on surgeon experience and sometimes underlying etiology.[1]

When patients fail to respond to conservative measures, have persistent severe symptoms or present with intrinsic muscle atrophy, operative management should be considered.

Post-Operative Rehabilitation

Once the incision and soft tissues have healed, rehabilitation therapies are often used to help the patient regain pain-free range of motion, normal strength and function. The extent and duration of a post-operative rehabilitation program varies with the extent of injury and the physical demands of a return to normal activities such as ADLs, occupational activities or sports. Goals of a postoperative rehabilitation program include (a) full active range of motion for elbow flexion, extension, pronation and supination, (b) normal elbow strain, with balance maintained between agonists and antagonists muscles, and (c) resumption of sports-specific and work specific functional activities. Exercises to establish neuromuscular control include proprioceptive neuromuscular facilitation and progression from closed-kinetic chain activities through open-kinetic chain exercises. A rehabilitation program may be necessary for six weeks or more post-operatively.[15]

Conclusions

Cubital tunnel syndrome is a common cause of upper extremity pain and disability. The treating clinician should possess a high degree of familiarity with the relevant aspects of anatomy, epidemiology and clinical presentation. The diagnosis of cubital tunnel syndrome frequently requires a combination of clinical suspicion and may require electrodiagnostic confirmation. Once diagnosed, cubital tunnel syndrome is initially treated by conservative measures focused on patient education and avoidance of provocative activities. In the presence of intrinsic hand muscle atrophy or persistent severe symptoms, operative treatment should be considered.

References

1. Palmer BA, Hughes TB. Cubital tunnel syndrome. *J Hand Surg Am.* Jan 2010;35(1):153–63.
2. Werner CO, Ohlin P, Elmqvist D. Pressures recorded in ulnar neuropathy. *Acta Orthop Scand.* Oct 1985;56(5):404–6.
3. Apfelberg DB, Larson SJ. Dynamic anatomy of the ulnar nerve at the elbow. *Plast Reconstr Surg.* Jan 1973;51(1):79–81.
4. van Rijn RM, Huisstede BM, Koes BW, Burdorf A. Associations between work-related factors and specific disorders at the elbow: a systematic literature review. *Rheumatology (Oxford).* May 2009;48(5):528–36.
5. Novak CB, Lee GW, Mackinnon SE, Lay L. Provocative testing for cubital tunnel syndrome. *J Hand Surg Am.* Sep 1994;19(5):817–20.
6. Folberg CR, Weiss AP, Akelman E. Cubital tunnel syndrome. Part I: Presentation and diagnosis. *Orthop Rev.* Feb 1994;23(2):136–44.
7. Macadam SA, Bezuhly M, Lefaivre KA. Outcomes measures used to assess results after surgery for cubital tunnel syndrome: a systematic review of the literature. *J Hand Surg Am.* Oct 2009;34(8):1482–91 e1485.
8. McGowan AJ. The results of transposition of the ulnar nerve for traumatic ulnar neuritis. *J Bone Joint Surg Br.* Aug 1950;32-B(3):293–301.
9. Practice parameter: electrodiagnostic studies in ulnar neuropathy at the elbow. American Association of Electrodiagnostic Medicine, American Academy of Neurology, and American Academy of Physical Medicine and Rehabilitation. *Neurology.* Mar 10 1999;52(4):688–90.
10. Friedrich JM, Robinson LR. Prognostic indicators from electrodiagnostic studies for ulnar neuropathy at the elbow. *Muscle Nerve.* Apr 2011;43(4):596–600.
11. Dellon AL, Hament W, Gittelshon A. Nonoperative management of cubital tunnel syndrome: an 8-year prospective study. *Neurology.* Sep 1993;43(9):1673–7.

12. Abuelem T, Ehni BL. Minimalist cubital tunnel treatment. *Neurosurgery.* Oct 2009;65(4 Suppl):A145–9.
13. Goldfarb CA, Sutter MM, Martens EJ, Manske PR. Incidence of re-operation and subjective outcome following in situ decompression of the ulnar nerve at the cubital tunnel. *J Hand Surg Eur Vol.* Jun 2009;34(3):379–83.
14. Macadam SA, Gandhi R, Bezuhly M, Lefaivre KA. Simple decompression versus anterior subcutaneous and submuscular transposition of the ulnar nerve for cubital tunnel syndrome: a meta-analysis. *J Hand Surg Am.* Oct 2008;33(8):1314 e1311–2.
15. Hertling D KR, ed *Management of Common Musculoskeletal Disorders. Physical Therapy Priciples and Methods.* 4 ed. Philadelphia: Lippincott Williams & Wilkins; 2006.

Samir K. Trehan, MD, is a second year orthopaedic surgery resident at Hospital for Special Surgery in New York, NY

John R. Parziale, MD, is a Clinical Associate Professor, Department of Orthopaedics, Warren Alpert Medical School of Brown University

Edward Akelman, MD, is a Professor, Department of Orthopaedics, Warren Alpert Medical School of Brown University

Disclosure of Financial Interests

The authors and/or their spouses/significant others have no financial interests to disclose.

Correspondence

John R. Parziale, MD
University Rehabilitation, Inc.
450 Veterans' Memorial Parkway, Building #12
East Providence, RI 02914
phone: (401) 435-2288
fax: (401) 435-2282
e-mail: jrp@urehab.necoxmail.com