Non-small Cell Lung Cancer With Unsuspected Distant Metastasis To the Kidney Seen on PET/CT

Marilyn Barry-Brooks, MD, Don C. Yoo, MD, Michael Chaump, MD, and Richard B. Noto, MD

A 72-year-old man with a 40-pack-year history of smoking presented to his primary care physician with a three-week history of hoarseness. Physical examination at the time of presentation was remarkable only for hoarseness. The patient was treated with a trial of inhalers and continued to have symptoms.

Diagnosis

A CXR was performed at an outside institution that reported no evidence of an infectious process in the lungs. The patient subsequently had a chest CT scan that showed a five cm left upper lobe mass invading the mediastinum and likely involving the recurrent laryngeal nerve resulting in the patient's hoarseness. (Figure 1) CT guided biopsy of the mass was performed which showed clusters of atypical cells on histology consistent with **non-small cell lung cancer (NSCLC)** with adenocarcinoma favored. (Figure 2) The patient then underwent a **positron emission tomography/computed tomography (PET/CT)** scan with **18F-fluorodeoxyglucose (F-18 FDG)** for staging. **Maximum intensity projection (MIP)** image (Figure 3) and axial images (Figure 4) from the PET/CT scan showed intense uptake in the lung mass. There was no evidence of metastatic disease in the mediastium or hilar regions. However, there was an intense focus of increased activity in the lower pole of the left kidney (MIP image in Figure 3 and coronal reformats in Figure 5) which was suspicious for metastatic disease and the patient had a contrast enhanced renal MRI for further characterization. MRI showed a solid mass in the lower pole of the left kidney (Figure 6) corresponding to the abnormality on the PET/CT scan. An ultrasound-guided biopsy was performed which showed glandular like clusters of cells on histology that were morphologically similar to those seen in the fine needle aspirate of the lung. In conjunction with the clinical scenario, the kidney mass was diagnosed as poorly differentiated adenocarcinoma consistent with metastatic lung adenocarcinoma. (Figure 7) The patient was treated with chemotherapy and also received radiation therapy to the lung mass but died within a year from his diagnosis.

Discussion

This case highlights the utility of PET/CT in the staging of NSCLC. NSCLC accounts for 75-80% of lung cancer related deaths in the western hemisphere. Accurate staging is needed to make treatment decisions including whether or not the patient is a surgical candidate.[1] Staging of NSCLC is based on location and size of the tumor, the degree of nodal involvement, and the presence of intrathoracic and extrathoracic metastases. It is important to determine the presence or absence of mediastinal disease.[2]

CT is usually the initial imaging modality used for the staging of NSCLC. The limitation of CT is that it is based on morphologic criteria, i.e. suspicious lymph nodes are identified by size criteria of being greater than 1 cm in short axis. However, lymph nodes smaller than 1 cm can have metastatic involvement and enlarged lymph nodes may be due to etiologies other than neoplasm. One study demonstrated that up to 44% of metastatic lymph nodes in patients with NSCLC measured less than 1 cm.[3]

PET/CT has become an established and readily available imaging modality for staging and restaging of patients with NSCLC. PET/CT using F-18 FDG combines information regarding the physiologic activity of a tumor (as most cancer cells have higher metabolic activity and accumulate more F18-FDG compared to normal cells) with the anatomic finding on CT. PET/CT has a sensitivity of 74% and specificity of 85% for identifying

Figure 1. Noncontrast CT image shows a heterogeneous lung mass (white arrow) with direct extension into the anterior mediastinum and encasement of the left subclavian artery and left common carotid artery.

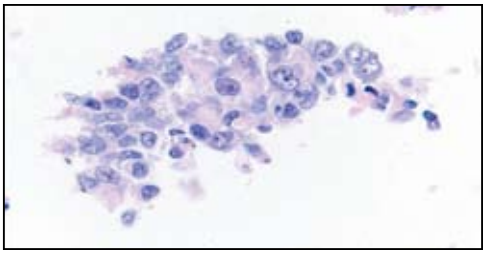

Figure 2. Microscopic image of the fine needle aspirate cell block from the left upper lobe lung mass, showing clusters of atypical cells (400x). Hematoxylin and Eosin stain.

Figure 3. MIP image from the F18-FDG PET/CT scan shows intense uptake in the lung mass invading the mediastinum (open arrow) and a discrete round focus of intense uptake in the left kidney (closed arrow).

mediastinal metastases versus CT with a sensitivity of 51% and a specificity of 86% when compared with mediastinoscopy or surgical staging.[4] In addition, PET/CT can aid in the detection of intrathoracic and extrathoracic metastases. PET/CT has been shown to contribute to upstaging of patients primarily by the identification of extrathoracic metastases resulting in 20% fewer unnecessary thoracotomies.[5] A limitation of PET/CT is the low metabolic activity of some types of lung cancers such as adenocarcinoma in situ and primary lung carcinoid which can make the evaluation of metatastic lymph node involvement and distant metastatic disease more difficult.

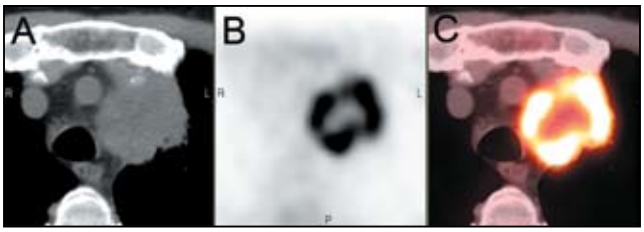

Figure 4. Axial CT (A), PET (B), and fused PET/CT (C) images show intense uptake around the periphery of the left upper lobe mass. The central region of the mass was photopenic consistent with central necrosis.

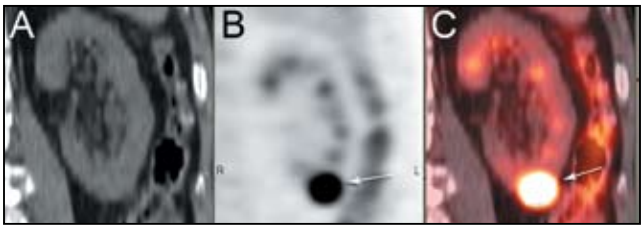

Figure 5. Axial CT (A), PET (B), and fused PET/CT (C) images show focal intense uptake in the lower pole of the left kidney (white arrows) without an unenhanced CT correlate.

Figure 6. Postcontrast T1 weighted coronal MR image of the left kidney show a solid mass in the lower pole with mild peripheral nodular enhancement corresponding to the focus of intense uptake on the PET/CT scan.

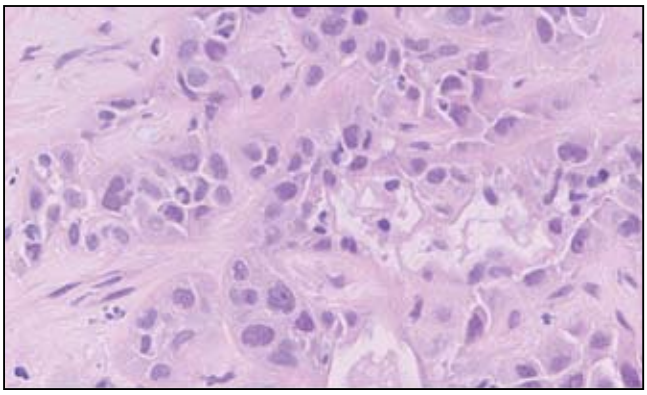

Figure 7. Microscopic image of the left lower pole kidney biopsy showing glandular like clusters of atypical cells (400x) morphologically similar to those seen in the fine needle aspirate of the lung. Hematoxylin and Eosin stain.

This case shows a very unusual unsuspected isolated distant site of metastatic disease to the left kidney detected on PET/CT in a patient with absent mediastinal or hilar metastatic adenopathy. The primary method of excretion of F18-FDG is through the kidneys with 40% of the administered dose excreted by the kidneys in the first two hours. Evaluation of primary renal malignancies on PET/CT is limited due to the high background activity in the kidneys that can obscure uptake in primary renal cell cancers especially as most renal cell cancers have relatively low metabolic activity on PET/CT. Metastatic disease to the kidneys from lung cancer is uncommon. However, when it occurs, it typically demonstrates intense activity on PET/CT.[6]

Conclusion

This patient had a PET/CT for the staging of a left upper lobe NSCLC that did not show evidence of metastatic adenopathy in the chest but showed an unexpected suspicious focus of intense activity in the left kidney which on biopsy represented a site of distant metastatic disease. This patient was upstaged from a stage 3A to a stage 4 lung cancer based on the PET/CT, altering the patient's prognosis and treatment.

References

1. Devaraj A, Cook GJR, et al. PET/CT in non-small cell lung cancer staging-promises and problems. *Clinical Radiology.* 2007;62: 97–108.
2. Nair A, Klussman MJ, et al. Revisions to the TNM staging of non-small cell lung cancer: rationale, clinicoradiologic implications, and persistent limitations. *RadioGraphics.* 31:215–38.
3. Prenzel KL, Monig SP, Sinning JM, et al. Lymph node size and metastatic infiltration in non–small cell lung cancer. *Chest.* 2003;123:46–7.
4. Silvestri, GA, Gould MK, et al. Noninvasive staging of non-small cell lung cancer. *Chest.* 2007;132:178S-201S.
5. Van Tinteren H, Hoekstra OS, et al. Effectiveness of positron emission tomography in the preoperative assessment of patients with suspected non-small cell lung cancer: the PLUS multicentre randomized trial. *Lancet.* 2002; 359:1388–92.
6. Kochhar R, Wong CO, et al. Role of FDG PET/CT in imaging of renal lesions. *J Med Imag Rad Oncol.* 2010;54:347–57.

Marilyn Barry Brooks, MD, is a Diagnostic Radiology Resident at the Warren Alpert Medical School of Brown University.

Don C. Yoo, MD, is Assistant Professor of Diagnostic Imaging (Clinical) at the Warren Alpert Medical School of Brown University.

Michael Chaump, MD, is a Pathology Resident, The Warren Alpert Medical School of Brown University.

Richard B. Noto, MD, is Associate Professor of Diagnostic Imaging (Clinical), The Warren Alpert Medical School of Brown University.

Disclosure of Financial Interests

The authors and/or significant others have no financial interests to disclose.

Correspondence

Marilyn Barry-Brooks, MD
Department of Diagnostic Imaging
Rhode Island Hospital
593 Eddy Street
Providence, RI 02903
e-mail: mbarry@lifespan.org

Recurrence of Lung Cancer After Radiofrequency Ablation Detected by PET/CT and Contrast Enhanced CT Scan

Albert A. Scappaticci, MD, PhD, and Don C. Yoo, MD

82-year-old female with a history of cough for three months had a CT of the chest which revealed a 1.5 cm right upper lobe pulmonary nodule. (Figure 1) The patient underwent a CT guided percutaneous biopsy which on histology was consistent with adenocarcinoma of the lung. The patient then underwent a **positron emission tomography/computed tomography** (**PET/CT**) scan (Figure 2) with **18F-fluorodeoxyglucose** (**F-18 FDG**) for staging which showed intense uptake in the right upper lobe adenocarcinoma without evidence of metastatic disease. The patient was not a surgical candidate due to poor pulmonary reserve and subsequently underwent percutaneous **radiofrequency ablation** (**RFA**) of the right upper lobe adenocarcinoma. After RFA, a follow-up PET/CT (Figure 3) six months later showed curvilinear activity around the ablation site with slightly more intense activity anteriorly. A contrast-enhanced CT scan (Figure 4) showed focal enhancement in the anterior aspect of the ablation cavity corresponding to the area of more focal intense activity seen on the follow-up PET/CT. Percutaneous CT guided biopsy of this region confirmed suspicion of residual or recurrent adenocarcinoma. The patient was retreated with RFA. (Figure 5) Repeat CT scan (Figure 6) performed at four months after reablation showed no evidence of residual tumor (not shown).

Figure 1. Noncontrast CT image show a spiculated 1.5 cm lung nodule in the right upper lobe (arrow).

Discussion

Radiofrequency ablation of lung cancer is an important treatment option for patients who are medically inoperable with proven safety and efficacy. RF abla-



Figure 2. Preablation Axial CT (A), PET (B), and fused PET/CT (C) images show intense uptake in the right upper lobe nodule (arrows) which was histologically proven to represent an adenocarcinoma.