Images In Medicine

Cryptococcal Pneumonia in a HIV Positive Patient: A Pre- and Post-Mortem View

Michael Chaump, MD, Ralph N. Sams, MD, Don Yoo, MD, and Ronald A. DeLellis, MD

A 42-year-old man with no significant medical history presented to the emergency department with headaches and fever of three weeks duration. He had returned to the United States from a recent trip to Puerto Rico, where he reported multiple unprotected sexual contacts with men. One week prior to presentation, he was evaluated at an outside facility and was discharged with a diagnosis of Dengue fever.

On further evaluation, ELISA testing for HIV was positive and was confirmed with Western Blot. His CD4+ cell count was 0.015 K/uL. A lumbar puncture was performed and his cerebrospinal fluid was positive for cryptococcal antigen. On examination of the spinal fluid, encapsulated yeast-like forms were seen and cultures were positive for *Cryptococcus neoformans*. An anteroposterior chest radiograph revealed a 2.6 x 2.0 cm cavitary lesion in the right lower lobe. (Figure 1) The patient was admitted for further treatment. During his hospital course, he experienced seizure-like activity and became unresponsive. A non-contrast CT scan of the head at this time was non-diagnostic. He was transferred to the ICU; however, his condition deteriorated and he expired the day after admission. Cause of death was most likely due to septic shock in conjunction with an immunocompromised state.

Autopsy was limited to the brain and lungs. In addition to congestion and edema, there was a cavitary lesion in the right lower lobe that contained mucopurulent material. (Figure 2) On microscopic examination of the cavitary lesion, encapsulated yeast-like forms that were positive for methenamine silver and mucicarmine were identified. (Figure 3) Autopsy also revealed evidence of cryptococcal meningitis.

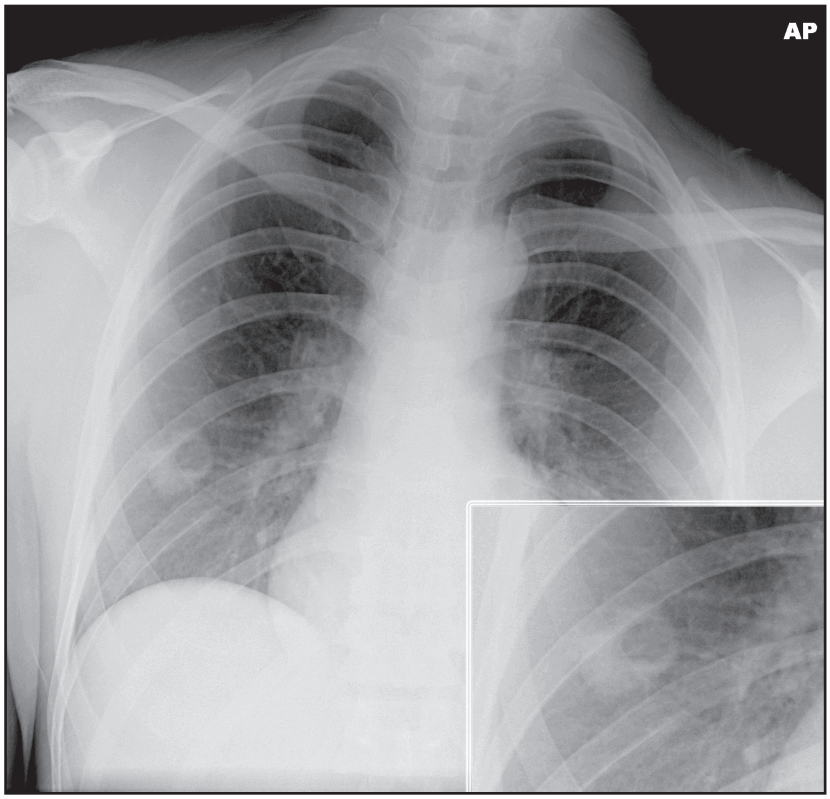

Figure 1. Chest radiograph with cavitary lesion in the right lower lung. Insert shows magnification of lesion.

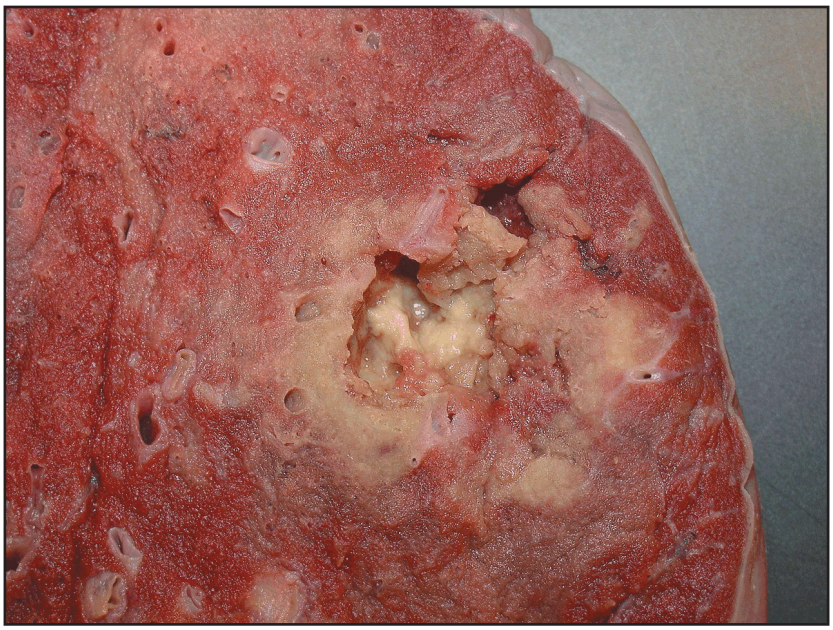

Figure 2. Gross view of right lower lobe cavitary lesion.

Cryptococcal Pneumonia

Cryptococcus neoformans is an encapsulated, laccase producing yeast. It is found predominantly in bird droppings and soil, and is infectious via inhalation. In immunocompetent hosts, infection is either not likely or may be latent. However, in immunocompromised individuals, *C. neoformans* is a significant pathogen.

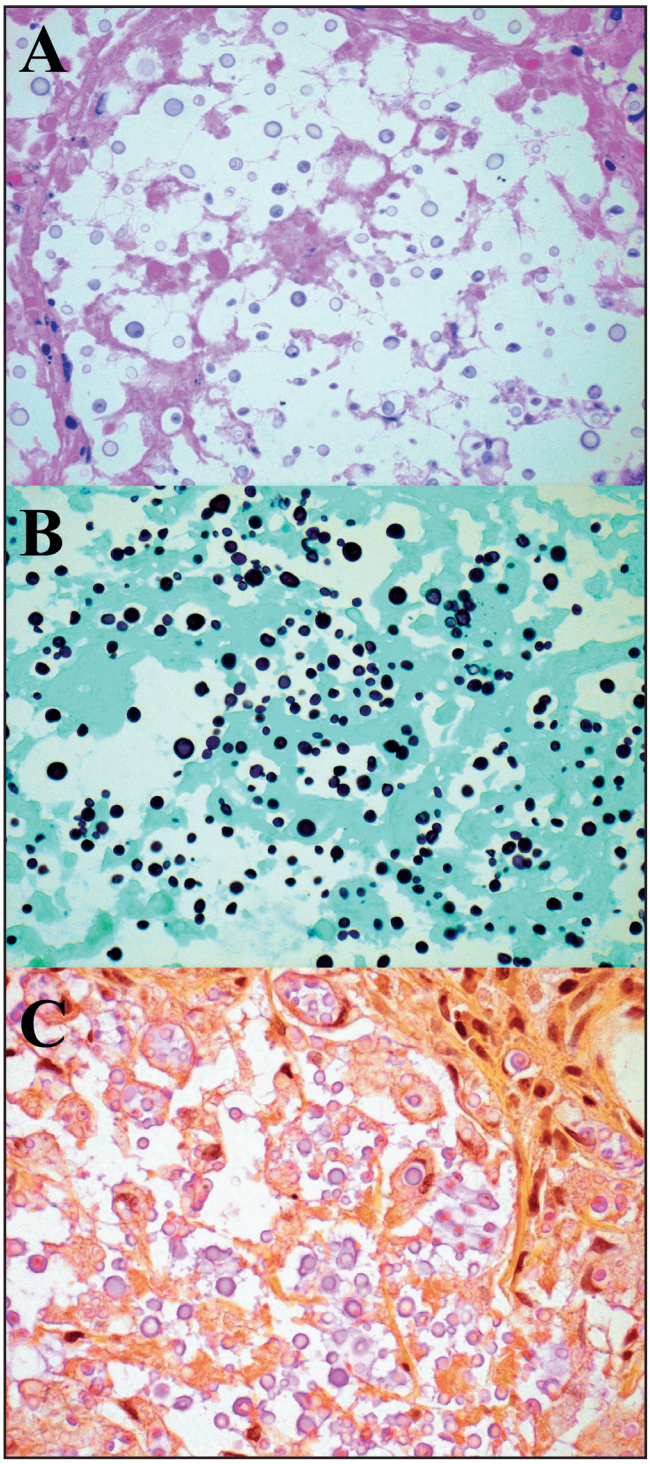

Figure 3. Microscopic images of the cavitary lesion showing round, encapsulated organisms with occasional budding forms (600x). A. Hematoxylin and Eosin stain, B. Mucicarmine stain, C. Gomori Methenamine Silver stain.

Several mechanisms allow for infection. The first is the presence of a polysaccharide capsule rich in glucuronoxylomannin, which reduces or prevents phagocytosis by alveolar macrophages. Second, is the production of laccase, a catalyst in the formation of melanin-like pigment. Production of this antioxidant provides protection against oxygen radical mediated destruction by alveolar macrophages.[1] Third, is the ability to invade tissue through the production of serine proteases that are capable of cleaving fibronectin in basement membranes.

Symptoms on presentation usually include fever, weakness, and shortness of breath, or in more extreme cases, respiratory failure. Clinically, immunocompromised patients are at most risk when their CD4 lymphocyte count is 200 cells/mm^3 or lower.[2] Radiologically, pulmonary lesions most often present as nodules or interstitial infiltrates.[3,4] Occasional patients may develop acute respiratory distress-like syndrome. Although rare, cavitary lesions do occur and are significantly more common in immunocompromised hosts that present with Cryptococcal pneumonia.[5]

References

1. Liu L, Tewari RP, Williamson PR. Laccase protects Cryptococcus neoformans from antifungal activity of alveolar macrophages. *Infect Immun* 1999; 67: 6034-9.
2. Masur H, Ognibene FP, et al. CD4 counts as predictors of opportunistic pneumonias in Human Immunodeficiency Virus (HIV) infection. *Ann Intern Med* 1989; 111: 223-31.
3. Zinck SE, Leung AN, et al. Pulmonary cryptococcosis. *J Computer Assisted Tomography* 2002; 26: 330-4.
4. Flickinger FW, Sathyanarayana, et al. Cryptococcal pneumonia occurring as an infiltrative mass simulating carcinoma in an immunocompetent host. South Med J.1993; 86:450-2.
5. Chang WC, Tzao C, et al. Pulmonary cryptococcosis. *CHEST* 2006;129: 333-4.

Michael Chaump, MD, is a resident, Department of Pathology, Rhode Island Hospital.

Ralph N. Sams, MD, is a resident, Department of Pathology, Rhode Island Hospital.

Don Yoo, MD, is Assistant Professor of Diagnostic Imaging, The Warren Alpert Medical School of Brown University.

Ronald A. DeLellis, MD, is Pathologist-in-Chief, Rhode Island Hospital and The Miriam Hospital, and Professor and Associate Chair, Department of Pathology and Laboratory Medicine, The Warren Alpert Medical School of Brown University.

Disclosure of Financial Interests

The authors and/or spouses/significant others have no financial interests to disclose.