What's New In Surgical Treatment for Crohn's Disease

Adam Klipfel, MD, and Paul Sturrock, MD

Crohn's disease (CD) has no cure. Surgery is reserved for 3 specific categories of complications: 1) urgent/ emergent, 2) chronic type conditions and 3) refractoriness to medical therapy. Approximately 70% of patients with CD will require at least one surgery during their lifetime.

The type of surgery required depends upon the clinical and anatomic presentation. CD can manifest anywhere from the mouth to the anus; unfortunately, for most patients, disease tends to eventually recur at the anastomotic site. The goal of treatment is similar in all cases: to resolve the symptoms, improve quality of life and reduce the risk of disease complications. The three anatomic areas that most commonly need surgical treatment are the distal small bowel, the large bowel and the ano-rectal area. Surgical treatment of the large bowel or colon will sometimes require a total colectomy or segmental resection which may require a temporary or permanent ostomy. The small bowel and the ano-rectal area present more difficult challenges. Anorectal disease can be quite debilitating, but can usually be palliated with drainage of abscesses and temporary indwelling drains. A team approach with medical and surgical therapy is associated with better outcome.[1] Severe ano-rectal disease may require a permanent ostomy in rare cases. There are some new techniques for ano-rectal surgery to palliate the disease.

For the small bowel, overall treatment goals are to preserve bowel length and thus prevent a short gut syndrome, while at the same time providing palliation and resolution of the problem with as little resection as possible by the least invasive techniques. Long-term studies have reported that on average a Crohn's patient will have 2.5 operations in a lifetime. For these reasons the use of laparoscopy, a less invasive technique thought to produce less scarring and trauma to the tissues, is an excellent way to reduce morbidity.

Laparoscopy in Crohn's Disease

The technique of laparoscopy has revolutionized abdominal surgery, allowing smaller incisions, better visibility, and less post-operative pain after procedures as diverse as cholecystectomy, appendectomy, hernia repair, and even surgery for morbid obesity. This technique is performed by using several small incisions (5 to 10 mm each) to gain access to the peritoneal cavity and employing small instruments to dissect under direct visualization provided by a camera (laparoscope.) When used for larger procedures including colonic surgery, one larger incision is often made for specimen extraction or for the insertion of a hand-assist port. This incision is almost always smaller than one that would have to be made for a conventional open operation.

Compared to conventional open surgery, improvements include decreased post-operative pain, shorter hospital stay, better cosmetic result and shorter recovery period.[2] When applied specifically to CD, the important issues are whether or not recurrence rates, morbidity and quality of life are equivalent to open surgery, therefore justifying its use to gain the above advantages. The next section reviews recent evidence regarding minimally invasive surgical treatment of CD.

Since 2005, three separate meta-analyses have evaluated laparoscopy in CD. The predominant operation by far was ileocolic resection, with a minority of studies reporting on Hartmann's procedures or abdominoperineal resections. All three studies demonstrated a statistically significant shorter length of hospitalization and earlier return of bowel function with the laparoscopic approach.[2,3,4] Additionally, Tan *et al* reported a lower overall cost in the laparoscopic group, likely related to earlier discharge.[2] Rosman and co-workers showed a lower rate of recurrent CD requiring surgery. No difference was observed in operative blood loss, rate of reoperation for complications, or mortality in any of these analyses. Overall morbidity was also found to be lower in the laparoscopic group, but there was no difference when individual complications were analyzed.[3] Conventional open surgery provided significantly shorter operative times than the laparoscopic approach. These studies concluded that the results justified the use of laparoscopy as a safe and viable option in the surgical treatment of CD.[2,3,4]

Additional data support the position that laparoscopic surgery has the lowest recurrence rate, fewest complications, and highest patient satisfaction. A comparative study of the two methods by Eshuis et al. showed similar rates of recurrence and quality of life after resection. The open surgery group had a higher rate of hernia formation and laparoscopy was associated with better cosmetic result; these results however did not reach statistical significance.[5] A prospective randomized trial by Stocchi et al confirmed similar recurrence rates and a trend toward higher rate of hernia formation, as well as a significantly greater rate of multiple operations in the open surgery group.[6] These studies did not demonstrate a superiority for the laparoscopic approach, but provided further evidence that its use in CD is acceptable with better cosmetic results and potentially decreased morbidity.

Other operative technologies are evolving, and some may be of assistance in the surgical management of RD. Robotically assisted laparoscopic surgery is used in abdominal surgery, and there

Complications:	Urgent/Emergent	Chronic/Long-term
Indications for operation	Bowel perforation/ obstruction toxic colitis	Stricture / recurrent partial obstruction
	Massive hemorrhage	Cancer
	Abscess	Abscess/ Fistula
	Refractory disease	Refractory disease

has been speculation that the ability to perform intracorporeal suturing may make it advantageous in the performance of strictureplasty. **Natural Orifice Transluminal Endoscopic Surgery (NOTES)** has gained attention recently, although its application in CD is as yet unclear. There are no reports of these techniques applied specifically to the treatment of inflammatory bowel disease, but as comfort and experience grow with the technology, there may be a role for each of these approaches.

Minimally invasive surgery has become an important element of the colorectal surgeon's arsenal. Patients often request laparoscopy, as they are aware of the potential advantages, including a faster recovery. While it may not be appropriate for every patient, it is an acceptable initial approach under the correct circumstances. Regardless of an open or laparoscopic approach, the ultimate goal is to achieve effective treatment of the diseased intestine and preserve as much bowel length as possible given the high likelihood for disease recurrence and need for reoperation.

Bowel Preservation and Strictureplasty

An area of surgery that is unique to CD is strictureplasty, which is the opening of a fibrotic narrowing (stricture) of the bowel lumen and suturing it back in a different orientation to allow more normal flow of intestinal contents without needing resection. Because CD has no cure, patients are prone to multiple operations with multiple bowel resections, and thus are at high risk of getting "short gut" syndrome, which can lead to death or lifelong dependence on total parenteral nutrition. For this reason the surgical approach to CD has become more and more conservative, focusing on techniques such as strictureplasty to preserve bowel length whenever possible. In CD a large inflammatory component can make resection the only possibility.

The strictures in CD come in various types and lengths, and there are different techniques to manage different types. If the stricture has a large inflammatory component refractory to medical treatment, a resection is indicated.

Indications for strictureplasty include:

1. Multiple strictures in a diffusely affected bowel
2. High risk for "short gut" because of previous resection and small amount of remaining bowel.
3. Fibrotic stricture without inflammation.

To justify surgical intervention, the stricture must also be symptomatic, usually manifesting as intermittent obstruction, restriction of food intake, weight loss, and/or inability to tolerate certain foods (particularly high residue); malnutrition can occur. Even in a patient who meets these criteria there are reasons that a strictureplasty should not be done. The following is a list of contraindications:

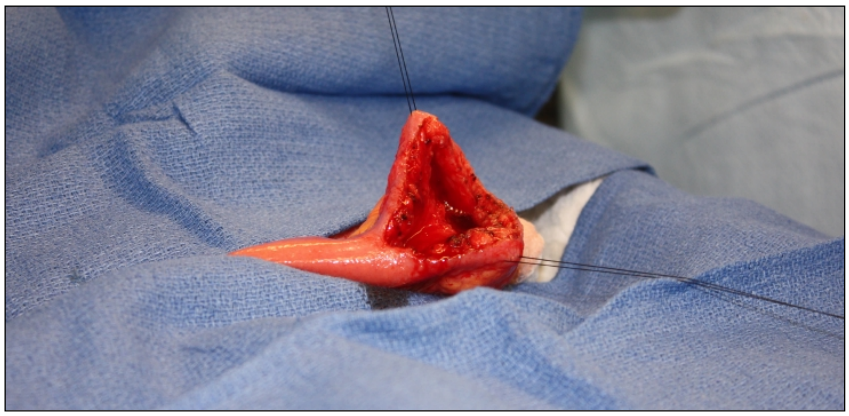

Image 1. Incision is made along the anti-mesenteric border of the stricture.

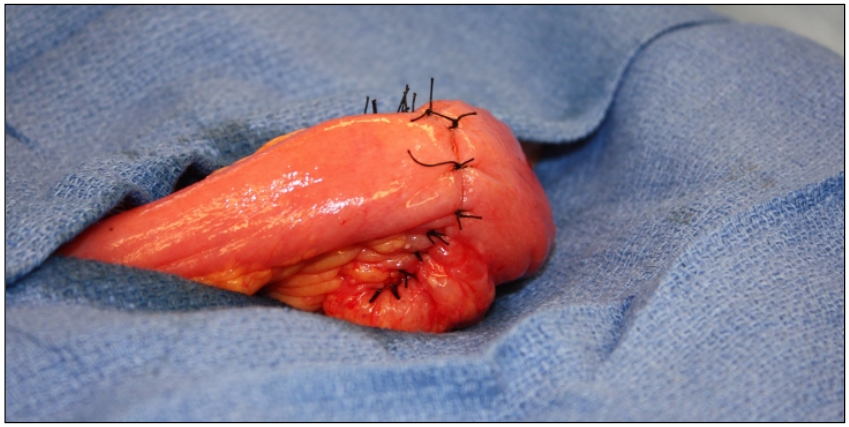

Image 2. Then sutured back together transversely.

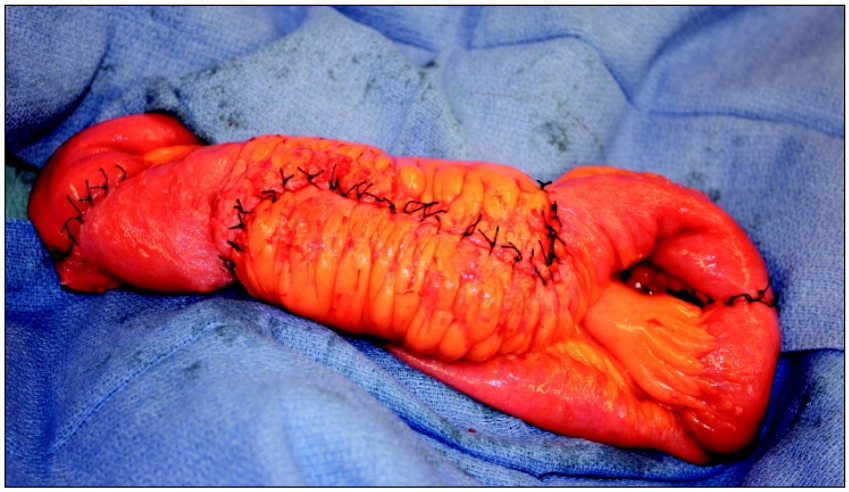

Image 3.

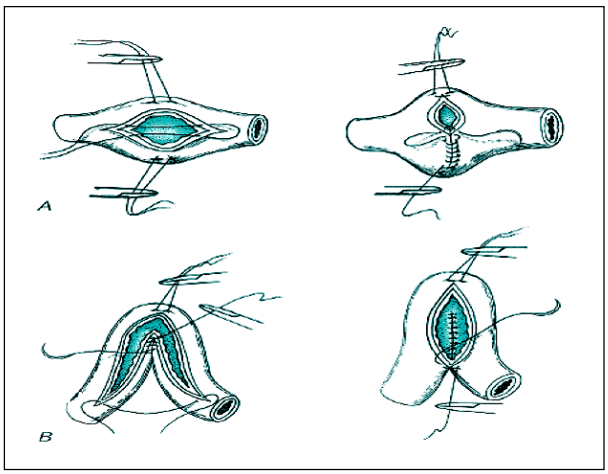

Diagram 1.

1. Perforated bowel
2. Severely inflamed loops of bowel forming a mass with or without a fistula to other bowel or skin.
3. Multiple strictures close together that would be better to resect.
4. Albumin < 2.0g/dl
5. Colonic strictures or a stricture close to a site that is being resected.

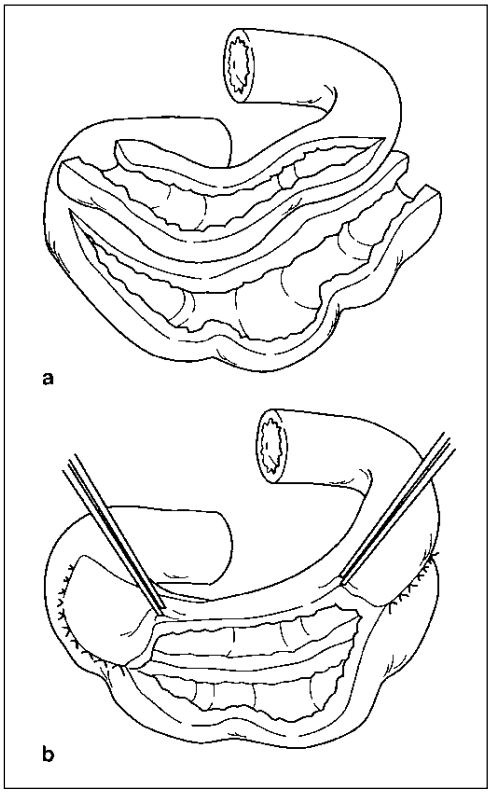

Diagram 2. Side to Side Iso-Peristaltic strictureplasty with two simple short segment strictureplasties one on either side.

There are several techniques of strictureplasty depending on the size and location of the lesions and the history of the patient. The size of the strictures are general broken down into 3 categories, <10cm, 10-20cm, and >20cm, each with increasing difficulty. If the tissue is not amenable to extensive suturing, the simplest, safest procedure is always resection; but this must be balanced with the amount of remaining bowel length and the patient's nutritional absorption. The smaller the stricture the easier the strictureplasty; the basic idea is to incise the wall of the bowel along the direction of the stricture and sew it back together in a way so as to create a new lumen and allow passage of intestinal contents without removing any bowel.

For the short segments strictures this can be accomplished by a longitudinal incision along the anti mesenteric side of the bowel followed by suturing it closed in the opposite and transverse direction. (Diagram 1(A) and Images 1 and 2)

For the medium length strictures the bowel is folded back onto itself and after incising along the anti-mesenteric side of the stricture the opening is closed by sewing to the opposite side and creating a lumen into which the intestinal contents can flow into and back out easily. (Diagram 1(B))

The longer segment strictures are the most difficult and often will be resected, but strictureplasty is important for the patient who is not able to tolerate a resection. One technique for the long strictures is to do a very long folded side to side anastamosis. This however will result in a large lumen or cavity that is not in continuity with the flow of the bowel and can lead to stasis and bacterial overgrowth. The technique that was developed more recently and seems to provide a more physiologic function is a side to side iso-peristaltic anastamosis. This is done by transecting the bowel in the middle of the stricture and placing the two portions of bowel side by side. By transecting and not folding it is possible to suture it together in a way that the lumen remains in continuity and thus prevent stasis of the intestinal contents. See Diagram 2 and Image 3.

Strictureplasty of all types can be done with good results. A systematic review with meta-analysis, done in 2007, examined these three types of strictureplasty in 3,259 patients. The morbidity was low with a septic (abscess/fistula/leak) complication rate of 4%. The recurrence rate overall was 28% after strictureplasty. Ninety percent of these were at non-strictureplasty sites. Two patients developed adenocarcinoma at the site of previous strictureplasty. The risk of cancer in the area of the stricture must always be kept in mind during a strictureplasty. Any suspicious lesions must be biopsied and evaluated.

Ano-rectal Abscess and Fistula

Infection of the ano-rectal area is seen in approximately 20-25% of patients. It is often in conjunction with other areas of disease as well. Only about 3-5% of patients will have the ano-rectal area as their only site of disease. Anal abscess/fistula in CD can be debilitating. The abscess can be drained but often there is a connecting fistula and this is difficult to treat because of the poor wound healing related to the CD. Typically a drain or "seton" would be placed to allow for resolution of the sepsis associated with a fistula. Some patients retain that drain on an intermittent or permanent basis. The use of either Infliximab or Adalimumab has reduced the need for surgical treatment. A careful evaluation for perianal abscesses prior to medical treatment includes either pelvic MRI or ano-rectal ultrasound depending on local expertise combined with exam under anesthesia. This approach has 100% sensitivity in detecting abscesses that should be drained prior to treating with a biologic[12,13]. Infliximab is very effective in healing anal fistulas, or at least decreasing drainage where the

symptoms are not as troublesome.

One new surgical technique for anal fistulas from all causes is the collagen plug. The plug is a piece of porcine collagen that has been formulated into a cone shape with a small tip that is brought through the fistula tract from the inside to out and the large end is sutured in place to obliterate the internal opening and thus help the fistula to heal. Initial results showed success rates as high as 80%, but as experience has grown, success is falling to 50-65% in current series. The success with CD is even less with rates as low as 26%.[8] The best success seems to be in long fistulas without significant inflammation or abscess, thus treatment with an anal seton or drain prior to the plug is often beneficial. However, in these Crohn's patients even if 25-30% of people benefit, it may be worthwhile because this less invasive procedure, with minimal cutting, has less chance for complications related to poor wound healing.

Conclusion

CD poses difficult medical and surgical dilemmas. The ultimate goal is to give patients the best quality of life possible for their situation. Someday there may be a cure, but currently the surgical perspective is to palliate symptoms with as minimally invasive techniques as possible; these advances include laparoscopy, strictureplasty and anal fistula plugs. Refinements in other techniques, such as Robotics and **Natural Orifice Transluminal Endoscopic Surgery** (NOTES), are likely in the future.

References

1. Regueiro M, Mardini H. Treatment of perianal fistulizing Crohn's Disease with infliximab alone or as an adjunct to exam under anesthesia with seton placement. *Inflamm Bowel Dis* 2003; 9:98-103.
2. Tan JJY, Tjandra JJ. Laparoscopic surgery for Crohn's disease. *Dis Colon Rectum* 2007; 50: 576-85.
3. Rosman AS, Melis M, Fichera A. Metaanalysis of trials comparing laparoscopic and open surgery for Crohn's disease. *Surg Endoscopy* 2005; 19: 1549-55.
4. Tilney HS, Constantinides VA, et al. Comparison of laparoscopic and open ileocecal resection for Crohn's disease. *Surg Endoscopy* 2006; 20: 1036-44.
5.. Eshuis EJ, Oplle SW, et al. Long-term surgical recurrence, morbidity, quality of life, and body image of laparoscopic-assisted vs. open ileocolic resection for Crohn's disease. *Dis Colon Rectum* 2008; 51: 858-67.
6. Stocchi L, Milsom JW, Fazio VW. Long-term outcomes of laparoscopic versus open ileocolic resection for Crohn's disease. *Surgery* 2008; 144: 622-8.
7. Corman ML. *Colon and Rectal Surgery*. 5th Edition, Philadelphia: JB Lipincott. 2005: 1513-5.
8. Yamamoto T, Fazio VW, Tekkis PP. Safety and efficacy of strictureplasty for Crohn's disease. *Dis Colon Rectum* 2007;50:1968-86.
9. Ky AJ, Sylla,, et al. Collagen fistula plug for the treatment of anal fistulas. *Dis Colon Rectum* 2008;51:838-43.
10. Sands, et al. Infliximab maintenance therapy for fistulizing Crohn's Disease. *NEJM* 2004; 350: 876-85.
11. Siemanowski B, Regueiro M. Management of Perianal Fistula in Crohn's Disease. *Inflamm Bowel Dis* 2008; 14 (S2), A Clinician's Guide to IBD.
12. Schwartz DA, Pemberton JH, Sandborn WJ. Diagnosis and treatment of perianal fistulas in Crohn's Disease. *Ann Intern Med* 2001;135: 906-8.
13. AGA Technical Review on Perianal Crohn's Disease. *Gastroenterol* 2003;125:1508-30.

Adam Klipfel, MD, FACS, is a Staff Surgeon, Rhode Island Colorectal Clinic, and Program Coordinator and Faculty, Colorectal Fellowship Program, The Rhode Island Foundation for Colorectal Disease.

Paul Sturrock, MD, is a Colorectal Fellow, Rhode Island Colorectal Clinic Fellowship Program.

Disclosure of Financial Interests

The authors have no financial interests to disclose.

Correspondence

Adam Klipfel, MD
RI Colorectal Clinic
334 East Ave.
Pawtucket, RI 02860
Phone: (401) 725-4888
e-mail: AKlipfel@lifespan.org